

Recent Advances in Finding the Source of Triphasic Waves

Yash D. Shah and Muhammad S. Zafar*

Department of Neurology, Duke University Hospital, Durham, North Carolina, USA

Corresponding Author*

Muhammad S. Zafar*

Department of Pediatrics, Duke University Hospital, Durham, North Carolina

U.S.A

E-mail: muhammad.zafar@duke.edu

Copyright: ©2022 Zafar M. This is an open-access article distributed under the terms of the Creative Commons Attribution License, which permits unrestricted use, distribution, and reproduction in any medium, provided the original author and source are credited.

Received: 22-February-2022, Manuscript No. jnn-22-55197; **Editor assigned:** 24-February -2022, PreQC No. jnn-22-55197(PQ); **Reviewed:** 3-March-2022, QC No. jnn-22-55197(Q); **Revised:** 20-April-2022, Manuscript No. jnn-22-55197(R); **Published:** 8-April-2022, DOI. 10.35248/2471-268X.22.13.4.576

Abstract

Triphasic Waves (TWs) have been observed in the EEG recorded in patients with various types of encephalopathy. However, their origin and significance is still unclear. This review aims to explicate the localization of the cortical and subcortical generators of TWs using EEG Source Imaging (ESI).

Introduction

Generalized Periodic Discharges (GPDs) with Triphasic wave morphology, previously known as Triphasic Waves (TWs) are seen in medically ill patients. TW manifests with similar clinical presentations as other EEG encephalopathies and understanding the cerebral sources for TW might help understand the pathophysiology of TW. In this review, we try to analyze the TW in detail with the help of the Electric source imaging technique. TW can be defined as having three phases. The first phase is a small blunt upward phase, a steeper descending second phase is then followed by a slow rising, slightly prolonged third phase, seen bilaterally and diffusely on Electroencephalogram (EEG) (Figure 1).

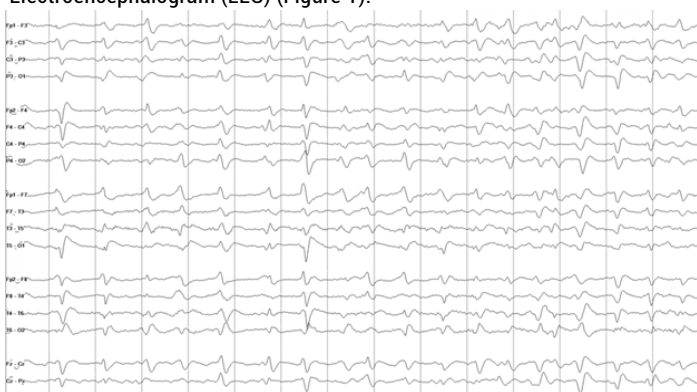


Figure 1. EEG of a 71-year-old female with a history of anoxic encephalopathy with a new presentation of hepatic encephalopathy secondary to non-alcoholic cirrhosis. EEG findings of triphasic waves of 1hz frequency with anterior-posterior lag. (sensitivity 7uV, AP bipolar longitudinal montage).

Etiopathogenesis

Hepatic encephalopathy, hyperammonemia, uremia, hypoxia, toxic encephalopathies associated with various drug classes, including antibiotics (cefepime), muscle relaxants (Baclofen), chemotherapeutic agents (Ifosfamide), anti-psychotics (lithium) and anti-seizure medications (pregabalin) are conditions commonly related with TWs. However, most cases of TWs are multifactorial, including cerebral atrophy, toxic, metabolic derangement, and intercurrent infection [1].

Studies have shown that patients with multiorgan failure or liver disease have an increase in TWs with increasing serum ammonia levels [2,3] In another study of 105 patients with acute encephalopathy, it was found that there was an increased risk of mortality in patients with TWs if they required ventilatory support or had minimally reactive EEG background [4].

There are two types of TWs waves described in the literature. Typical TWs commonly seen in hepatic encephalopathy are smoothed, negative, positive negative, diffuse symmetrical, and synchronous regular periodic or rhythmic at 1.5 hz to 2 hz fronto-centrally dominant (Figure 1). However, atypical TWs are seen mostly in other metabolic encephalopathies, degenerative disorders, cerebrovascular lesions, and tumors. These are frontopolar or parieto-occipital maximum, negative-positive or negative-positive-negative, asymmetric (Figure 2), and asynchronous, unreactive, irregular, multifocal, continuous with spatiotemporal evolution, sharper, and without anterior posterior lag [5].

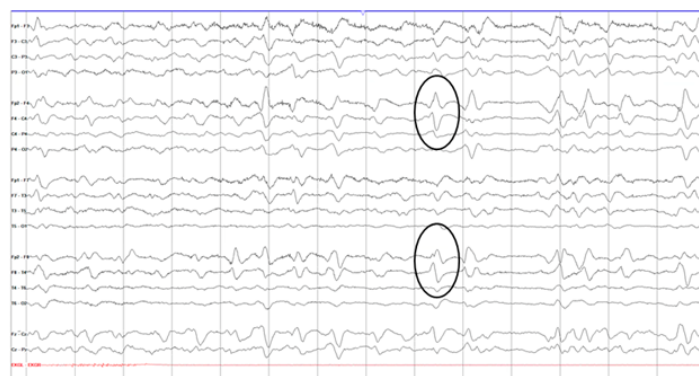

Figure 2. Atypical TWs: 0.75hz-1hz GPDs of TW morphology more prominent over the right frontal region in 82-year-old patient with hypoxic Ischemic encephalopathy secondary to Acute respiratory failure

The specific underlying pathophysiology of TWs is not known. The lack of animal models makes it difficult to localize the origin of TWs. In one study involving magnetoencephalography, it was found that there was thalamo-motor-cortical coupling at a significantly lower frequency in patients with hepatic encephalopathy compared to normal subjects. However, in this study, TWs were not studied [6]. Previous reports have hypothesized that TW is most likely generated through wave traveling across the cortex from the frontal to the occipital region, with primary disturbance occurring mainly at the thalamic level. Thus, TWs may represent sequential activation of the midline thalamic reticular nucleus. This activation may also be exacerbated when a patient suffers from acquired white matter disease, which can impair cortico-thalamic inputs that surpass thalamic activity [7].

EEG source Imaging (ESI)

Understanding the origin of specific waveforms in patient undergoing EEG monitoring can provide clues to the neurobiological mechanism of these patterns. Recent advancements in computational models such as ESI technology may help us understand the origin of these waveforms and generators of TWs.

ESI uses advanced computational methods to overcome two main problems: the 'Forward' and 'Inverse' problems. The forward problem is defined as difficulty in predicting the electric scalp activity based on the known source in the brain, while the inverse problem is a challenge to find a source that might be generating the recorded electrical activity on the scalp. Setting conditions to make a hypothetical head modal through which the electric currents pass can address the forward problem. In comparison, the inverse problem has no unique solution. Instead, there are multiple possibilities. Different algorithms with mathematical constraints are used to find the best possible solution. The two most common methods used are the dipole and the distributed source model.

Dipole modeling takes the voltage value from all the electrodes at that given instant in time and searches for the equivalent dipole within the head model. In distributed source modeling, no assumption is made on the number of dipoles, and multiple sources may be simultaneously active across multiple locations [8].

Recently, a retrospective EEG analysis was performed on medically ill encephalopathic patients at Duke University Hospital and Johns Hopkins University Hospital. It included patients with EEG findings of TW (Triphasic waves), Theta-Delta predominant pattern, the predominant Delta pattern, and FIRDA (Frontal intermittent rhythmic delta). TW was defined as >70 mV positive sharp with preceding and after going negative waves of <70 mV. Theta-Delta patterns were defined as those with intermixed frequencies from 1 Hz to 7 Hz. Delta patterns were defined as those with frequencies from 1 to 4 Hz. FIRDA waveforms were characterized by delta frequencies with associated rhythmicity seen in the anterior electrodes only. EEG with 10-20 system was performed on patients as a part of the standard of care. The EEG was obtained through Natus (at Duke) and Nihon Kohden amplifier (at John Hopkins) with impedance of 1kHz. EEG was visualized on bipolar and common average montages. The low frequency filter used was 0.5Hz and the high frequency filter as 70Hz. EEG samples were imported as European Data Format (EDF) format into the open-source Brainstorm and Commercial Curry 8 software by Compumedics. Dipole source modeling and distributed source modeling were performed. The standard Boundary Element Method (BEM) was used for modeling. This was derived from an averaged MRI data set from the Montreal Neurological Institute database (MNI). Twenty-eight EEG samples were selected for TW, predominant delta, predominant theta-delta, and FIRDA patterns. The dipole for TW was in the mesial structure within the anterior, inferior, and posterior frontal lobe and had anterior to posterior motion around midline structures. Current density analysis showed activation of the mesial area of anterior, inferior, and posterior frontal lobe (Figure 3). In comparison, dipole of FIRDA waves were in the mesial structure of the anterior frontal lobe without any change in location. Current density analysis showed activation of anterior and medial frontal structures but did not spread beyond this. The source analysis for EEG with generalized slowings like theta-delta and predominant delta patterns showed broad involvement of posterior frontal, middle frontal, and anterior parietal regions, including midline structures.

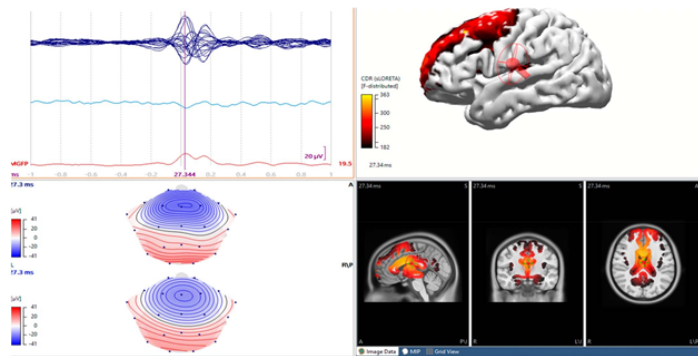


Figure 3. Triphasic wave source analysis: EEG averaged data of all electrodes plotted as butterfly (top left), voltage map (bottom left), standardized head model display (top right), and 3-dimensional reconstruction (bottom right).

In comparison to previous work where ESI was done on TW, FIRDA and diffuse slowing separately, this study compared these different wave forms on two different software. This analysis performed through two different algorithms produced results mostly concordant with previous findings. Kwon, et al. studied twelve patients with TWs using a single software [8]. Their results with Dipole and Distributed source modeling also suggest mesial frontal origin. Motomura et al. studied five patients with FIRDA [10]. They noticed source analysis results were located in the mesial frontal region anteriorly. Earlier studies using a simplified four-shell head model ESI have found the cortical generators of TWs to be present in the mesial frontal along cingulate cortices [9]. In one other study with 20 patients with encephalopathy with TWs using distributed source model and a more advanced spatial filtration method, TWs were generated by large, bilateral cortical networks invoking the anterior frontal and temporo-polar areas. In this study, using source montage, it was found that depolarization initially started in the frontal region and later propagated to the temporal regions supporting the complex frontal-temporal network involved in generating TWs. This could be explained by the uncinate fasciculus, which closely connects orbitofrontal and frontopolar frontal regions with anterior temporal structures [10].

Dipole and distributed source modeling of TW suggests a probable origin in the mesial structures at the anterior middle and posterior frontal lobe. When further constraints were applied, results were narrowed to the mesial frontal and to the midline structure (possibly thalamic). In comparison, FIRDA had a similar mesial origin but did not propagate from anterior to posterior, as did the TW. This suggests focal pathology with FIRDA while diffuse pathology with involvement of the thalamus with TW. Similar source localization results are seen with spike and wave discharges in idiopathic generalized epilepsy with the more frontopolar source. The underlying mechanisms in generalized epilepsies are attributed to the disrupted thalamocortical networks suggesting a somewhat similar mechanism in both spike and wave, and triphasic waveforms. On the other hand, analysis of predominant Theta-Delta and predominant Delta patterns showed different results than TW and FIRDA. This suggests the involvement of a more generalized region of the brain [11-14].

All these studies have some limitations. They are retrospective analysis with a low number of total subjects. The clinical etiology, neuroimaging, or administered medications were not considered. The standard 10-20 EEG placement might not be sufficient to implicate the thalamus as a source of origin. Future studies with high-density EEG will be helpful.

The high temporal resolution through EEG with the combined spatial estimation of the sources given by ESI provides noninvasive monitoring of brain areas that other single modality analysis cannot provide. However, ESI methods are not able to identify deep subcortical structures. It is reasonable to assume that thalamic structures play an essential role in initiating or sustaining the synchronized activity in these bilateral, mesial widespread cortical areas found in other studies. However, identifying this requires a different methodology. There is a need for further studies using EEG triggered functional MRI or high-density EEG, or stereotactic EEG involving medial structures, including the thalamus, to elucidate the possible involvement of the thalamus in generating TWs.

Conclusion

In summary, analysis of triphasic waves suggests TW appears to derive from the mesial frontal region with temporal evolution posteriorly through midline structures. This implies the possible role of the thalamus in its origin and propagation. The signature of TW is different than other EEG findings in medically ill patients, thus signifying its unique origin and pathophysiology.

References

1. Kaplan, P.W., et al. "An EEG Voyage in Search of Triphasic Waves-The Sirens and Corsairs on the Encephalopathy/EEG Horizon: A Survey of Triphasic Waves". *J Clin Neurophysiol*.38.5(2021):348-358.
2. Sutter, R., and Kaplan, P.W. "Clinical and electroencephalographic correlates of acute encephalopathy". *J Clin Neurophysiol*.30.5(2013):443-453.
3. Sutter, R., et al. "Clinical and imaging correlates of EEG patterns in hospitalized patients with encephalopathy". *Neurology*.260.4(2013):1087-1098.
4. Sutter, R. "Significance of triphasic waves in patients with acute encephalopathy: a nine-year cohort study". *Clin Neurophysiol*. 124.10(2013):1952-1958.
5. Fernández-Torre, J.L., and Kaplan, P.W. "Atypical or typical triphasic waves-is there a difference? A review." *J Clin Neurophysiol*. 38.5(2021):384-398.
6. Timmermann, L., et al. "Mini-asterix in hepatic encephalopathy induced by pathologic thalamo-motor-cortical coupling". *Neurology*. 61.5(2003):689-692.
7. Freund, B. "White matter disease-The true source of triphasic Waves?" *J Clin Neurophysiol*.38.5(2021):359-361.
8. Zozos, I., et al. "Advances in electrical Source Imaging: A Review of the current approaches, Applications and Challenges". *Signals*. 2.3(2021):378-391.

9. Kwon, O.Y., et al. "Source localization of triphasic waves: implications for the pathophysiological mechanism". *Clin EEG Neurosci.* 38.3(2007):161-167.
10. Motomura, E., et al. "Electroencephalographic dipole source modeling of frontal intermittent rhythmic delta activity". *Neuropsychobiol.*65.2(2012):103-108.
11. Ebersole, J.S. "Noninvasive localization of epileptogenic foci by EEG source modeling". *Epilepsia.* 41.(2000):S24-33.
12. Kural, M.A., et al. "Triphasic waves are generated by widespread bilateral cortical networks". *J Clin Neurophysiol.* 38.5(2021):415-419.
13. Kaplan P.W., and Schlattman, D.K. "Comparison of triphasic waves and epileptic discharges in one patient with genetic epilepsy". *J Clin Neurophysiol.* 29.5(2012):458-461.
14. Rodin, E.A., et al. "Source analysis of generalized spike-wave complexes". *Brain Topography.* 7.2(1994):113-119.