

Multiple Myeloma: “Uncommon Immunogamopathy Maculopathy”

Mohd Syafiq Bin Azman^{1,2*}, Shawarinin Binti Jusoh¹ and Akmal Haliza Binti Zamli¹

¹Department of Ophthalmology Hospital Tengku Ampuan Afzan

²Department of Ophthalmology Universiti Kebangsaan Malaysia

Abstract

Purpose: To report a case of symptomatic immunogammopathy maculopathy in multiple myeloma despite lower level of IgM (<7000 mg/dl) in a non-diabetic patient.

Case report: We report a 53-year-old Malay man with underlying hypertension and newly diagnosed multiple myeloma, complained of progressive blurring of vision in both eyes over 2 months. Visual acuity with best correction was 6/36 in both eyes. No relative afferent pupillary defect. Slit lamp biomicroscopy showed minimal nuclear cataract in both eyes. No evidence of cornea crystals. Funduscopic examination revealed bilateral macula neurosensory detachment with yellow-white subretinal precipitates. The retinal veins also appeared distended. Fluorescein angiography showed no evidence of macula hyperfluorescence from the retinal vasculature or retinal pigment in either eye. Baseline laboratory evaluation before treatment revealed microcystic anaemia, thrombocytopenia and abnormal serum protein electrophoresis IgM Kappa paraproteinemia of 5890 mg/dl.

Conclusion: Symptomatic immunogammopathy maculopathy in multiple myeloma is still possible despite lower levels of IgM (<7000 mg/dl) in a non-diabetic patient, therefore prompt treatment is necessary to prevent irreversible visual loss.

Keywords: Multiple myeloma; Immunogammopathy; Paraproteinemic; Maculopathy

Introduction

Multiple Myeloma is a plasma cell malignancy that destroys renal, skeletal and neurological function. An unusual macular detachment with or without subretinal precipitates or fundus signs of serum hyperviscosity, such as retinal hemorrhages and distended retinal veins, may be observed in patients with immune gammopathy such as multiple myeloma. Usually an immune gammopathy maculopathy becomes symptomatic when IgM level exceed 7000 mg/dl (non-diabetic patient).

Case Report

We examined a 53 year-old Malay man with underlying hypertension and newly diagnosed multiple myeloma, complained of progressive blurring of vision in both eyes over 2 months. Visual acuity with best correction was 6/36 in both eyes. No relative afferent pupillary defect. Slit lamp biomicroscopy showed minimal nuclear cataract in both eyes. No evidence of cornea crystals. Intraocular pressure was normal for both eyes. Funduscopic examination revealed bilateral macula neurosensory detachment with yellow-white subretinal precipitates which was further evaluated with optical coherence tomography (Figures 1-3). The retina veins also appeared distended. Fluorescein angiography showed no evidence of macula hyper fluorescence from the retinal vasculature or retinal pigment in either eye. Baseline laboratory evaluation before treatment revealed microcystic anaemia, thrombocytopenia and abnormal serum protein electrophoresis IgM Kappa paraproteinemia of 5890 mg/dl.

Discussion

Multiple myeloma, one of the malignant plasma cell dyscrasias is characterized by bone pain, skeletal punched out lesions, anemia, renal insufficiency, hypercalcaemia, hyperviscosity and increased susceptibility to infection. The ocular involvement can be found throughout the eye and visual pathway as well as the orbit. In this case, the retina specifically showed bilateral eye dilated and tortuous

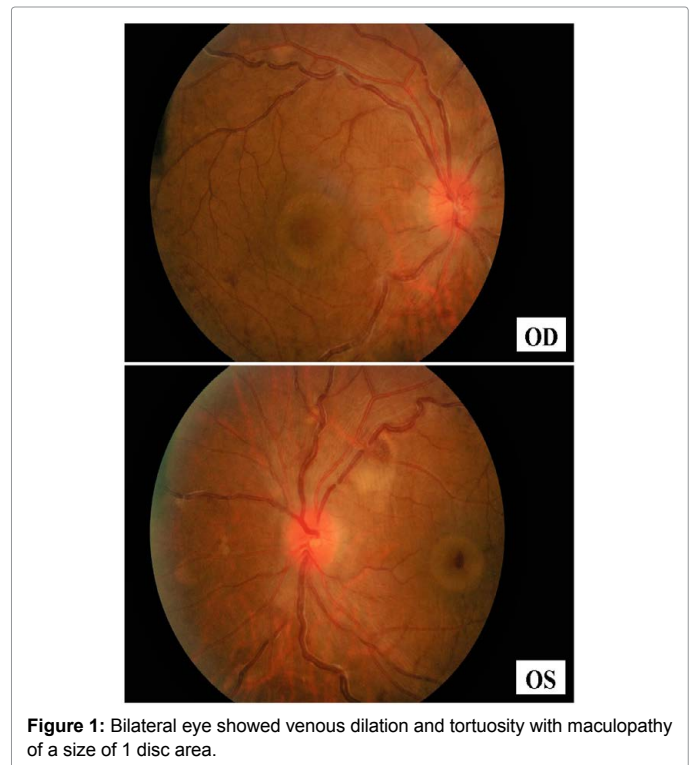


Figure 1: Bilateral eye showed venous dilation and tortuosity with maculopathy of a size of 1 disc area.

*Corresponding author: Mohd Syafiq bin Azman, Hospital Tengku Ampuan Afzan Jalan Tanah Putih, Malaysia, Tel: +60173129970; E-mail: drsyaqiqazman@gmail.com

Received May 31, 2017; Accepted June 06, 2017; Published June 12, 2017

Citation: Azman MSB, Jusoh SB, Zamli AHB (2017) Multiple Myeloma: “Uncommon Immunogamopathy Maculopathy”. Med Rep Case Stud 2: 137. doi: 10.4172/2572-5130.1000137

Copyright: © 2017 Azman MSB, et al. This is an open-access article distributed under the terms of the Creative Commons Attribution License, which permits unrestricted use, distribution, and reproduction in any medium, provided the original author and source are credited.

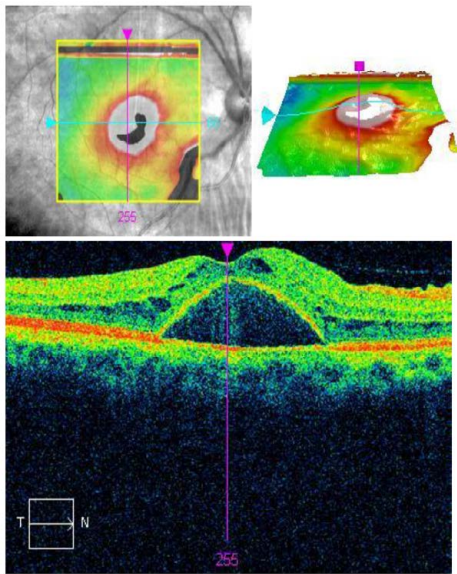


Figure 2: Optical coherence tomography of the right eye showed intraretinal edema with serous detachment of the neurosensory retina.

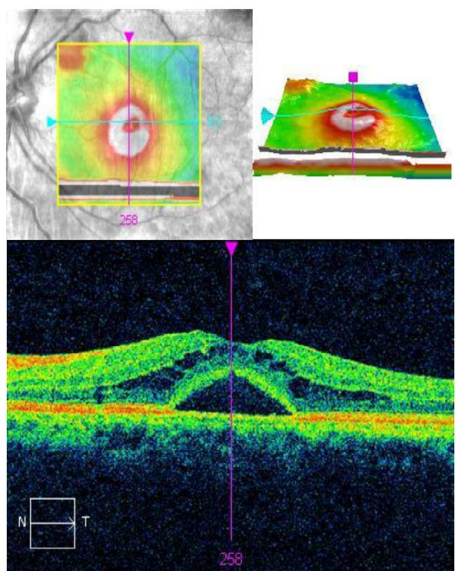


Figure 3: Optical coherence tomography of the left eye showed intraretinal edema with serous detachment of the neurosensory retina.

veins which are signs of hyperviscosity with intraretinal edema and subretinal fluid. Venous stasis retinopathy and choroidopathy will involve hypoxic event which lead to breakdown in the blood-retinal barrier and finally IgM deposition in the subretinal space producing significant osmotic gradient [1]. This case was uncommon in that the immune gammopathy maculopathy happen even before reaching the suggested level of IgM in previous literature. It was suggested that immunogammopathy maculopathy become symptomatic when IgM level exceed 4000 mg/dl in diabetics and 7000 mg/dl in non-diabetics [2].

Conclusion

Symptomatic immunogammopathy maculopathy in a non-diabetic multiple myeloma patient is still possible despite the level of IgM is lower than the suggested level in previous literature, therefore prompt treatment is necessary to prevent irreversible visual loss.

References

1. Cohen SM, Kokame GT, Gass JD (1996) Paraproteinemas associated with serous detachments of the retinal pigment epithelium and neurosensory retina. *Retina* 16: 467-473.
2. Mansour AM, Arevalo JF, Badal J, Moorthy RS, Shah GK, et al. (2014) Paraproteinemic aculopathy. *Ophthalmology* 121: 1925-1932.