

## Multifocal Colonic Endometriosis: Diagnostic Challenge and Therapeutic Modalities

Khalid Al Orabi<sup>1\*</sup> and Asrar Zamzami<sup>2</sup>

<sup>1</sup>*Surgical Department, Associate Consultant, King Abdullah Medical City, Makkah, Saudi Arabia*

<sup>2</sup>*Department of Radiology, Women Imaging, King Fahd Armed Forces Hospital, Jeddah, Saudi Arabia*

\***Corresponding author:** khalid Al-Orabi, Surgical Department, Associate Consultant, King Abdullah Medical City, Makkah, Saudi Arabia, Tel: +966555610071; E-mail: [khalidalorabi@hotmail.com](mailto:khalidalorabi@hotmail.com)

**Received:** Nov 30, 2018; **Accepted:** Dec 26, 2018; **Published:** Dec 31, 2018

**Copyright:** © 2018 Orabi KA, et al. This is an open-access article distributed under the terms of the Creative Commons Attribution License, which permits unrestricted use, distribution, and reproduction in any medium, provided the original author and source are credited.

### Abstract

Endometriosis occurs in 7-10% of women in the general population. It is an estrogen-dependent disease and, thus, usually affects reproductive aged women. intestinal involvement of endometriosis causing obstruction is relatively uncommon and is difficult to differentiate from neoplasia before surgery. Among women with intestinal endometriosis, the rectum and sigmoid colon are the most commonly involved areas (75–90%). We report a 22-year-old female presented with abdominal pain and rectal bleeding, and who had multifocal colonic endometriosis involving sigmoid colon and two other proximal foci (15 cm apart) diagnosed by histopathology after resection of the involved area laparoscopically with end to end anastomosis. She notices significant pain relieve one month after surgery and GnRH therapy. We did a review in the literature to find the best approach in such cases. Endometriosis is a common debilitating benign gynecologic condition. Multifocal symptomatic colonic endometriosis is rare, delayed and underdiagnosed disease. But it should be considered in the differential diagnosis of reproductive age women with cyclic abdominal pain and rectal bleeding. In this report, we present a case of young female with multifocal colonic endometriosis and discuss its clinical, radiological and colonoscopic findings. Literature review was done to find the best approach in managing such cases.

**Keywords:** Multifocal colonic endometriosis; Rectal bleeding; Cyclic abdominal pain

### Introduction

Endometriosis, the presence of endometrial-like glands and stroma outside the uterus, is a common, poorly understood, and extremely debilitating benign gynecological condition. No cure exists for the disease, and treatment is directed toward medical suppression, surgical excision, and symptoms alleviation.

Intestinal endometriosis is rare condition and can have variable presentations; moreover, the diagnosis is often delayed. Among women with intestinal endometriosis, the rectum and sigmoid colon are the most commonly involved areas. It rarely affects whole colon circumference, having the potential to cause obstruction or perforation. Its differential diagnosis involves colonic neoplastic disorders (benign and malignant), inflammatory bowel disease [1], ischemic colitis [2] and some types of diverticulosis.

We report a case of multifocal colonic endometriosis involving rectosigmoid and descending colon.

### Case Report

A 22-year-old, single, Saudi female who was well till 6 years ago when she started to complain of abdominal pain.

Her menarche at age of 12-year-old pain is diffuse, gradual of onset, colicky, intermittent, and lasting for 1-2 hours/day during menstruation, increased two days before menstruation, improved by defecation, rest and antispasmodic mediations. Associated increased

frequency of urination and intermittent bloody stool the first 3 days of menstruation, mixed with some mucus.

In the last year, the pain became localized in the Lower left quadrant. Her medical history otherwise would be unremarkable. Her symptoms became a lot worse in the last month.

On examination; the vital signs were normal and abdominal examination reveals only mild tenderness of the left lower quadrant. Basic investigations done and the abnormalities were: eosinophils 7% (1-6%), ESR: 33 mm/hr (1-20 mm/hr), urinalysis +1 ketones but normal blood sugar. CA 125 (ovarian marker) was 452 U/ml (0-35 U/ml).

Colonoscopy reveals normal rectal mucosa, and narrow recto-sigmoid where the scope could not be passed, incidentally, many pinworms were seen (Figure 1).

Abdomeno-pelvic CT scan, Figure 2 shows that there is excentric thickening at recto-sigmoid junction and sigmoid colon. The thickness of the wall ranges from (12-18 mm), Chocolate cyst were noted in both ovaries. No evidence of liver focal lesions or ascitis.

MRI pelvis (Figure 3) done and it reveals two separated solid enhancing mass lesions protruded intra-luminal in the colon, one of them at the anterior aspect of the recto-sigmoid measures about (3 × 2 cm) and another similar one (15 cm proximal to previous one) measures about (4.5 × 0.5 cm).

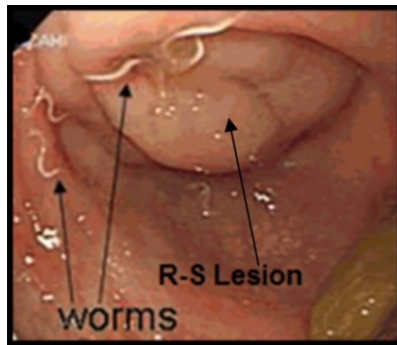


Figure 1: Colonoscopic view showing the recto sigmoid lesion.

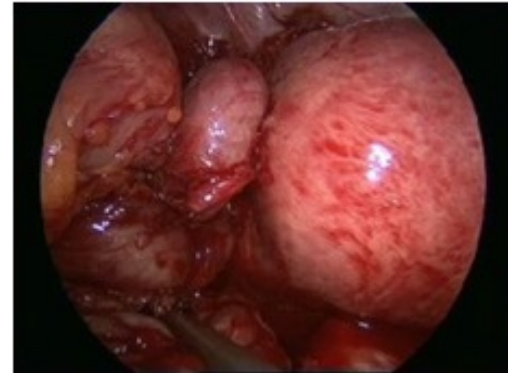


Figure 4: Lt. hydrosalpinx.

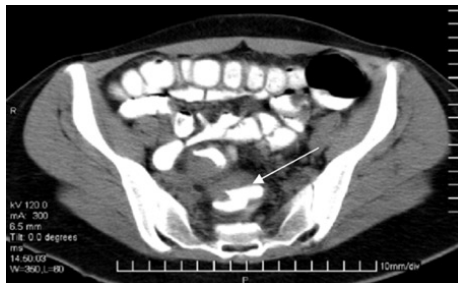


Figure 2: CT scan showing recto-sigmoid narrowing.

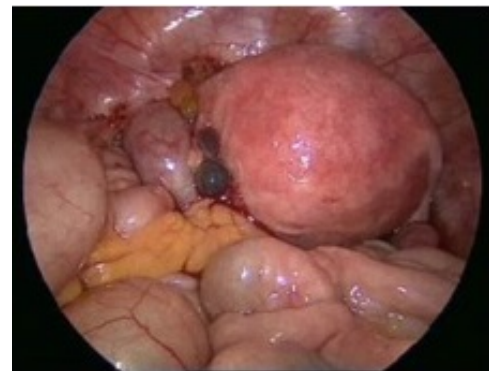


Figure 5: Two black lesions.

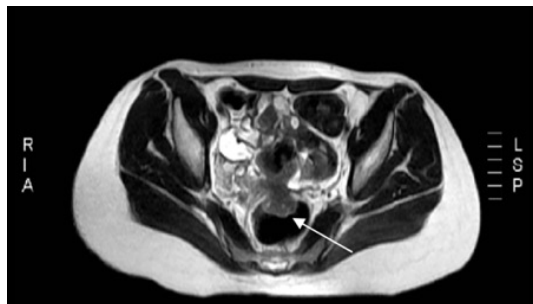


Figure 3: MRI showing the lesion on the anterior wall of recto sigmoid.

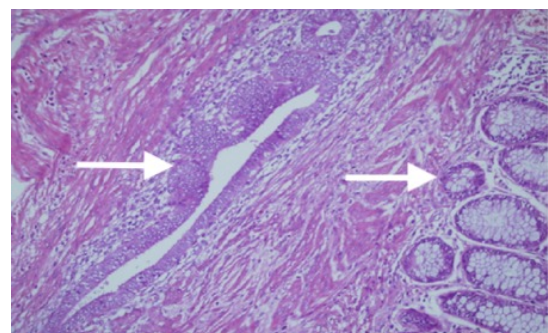


Figure 6: Endometrial glands on (left arrow), colonic epithelium (right arrow).

Laparoscopic exploration reveals extensive pelvic adhesions involving sigmoid colon, left ovary and tube with hydrosalpinx (Figure 4). There were 2 small (1 × 1 cm) black lesions noticed over the adhesions (endometriotic tissue) (Figure 5). Adhesiolysis and resection of the recto-sigmoid colon followed by end to end anastomosis was done with cauterization of the area in contact to prevent recurrence.

Histopathology of the specimen showing segment of large bowel (26 × 3 cm) and the wall shows 3 foci of mural thickening, largest focus measures (5.5 × 2.5 × 1) cm. Serosa shows adhesions. The microscopic examination showed cystic structures lined by endometrial glands and stroma (Figure 6). Several reactive lymph nodes were identified in the pericolic fat, some of which shows endometriosis. No evidence of malignancy seen.

She received GnRH therapy monthly (for 6 months) and was followed up in surgery and gynecology clinic. Significant improvement of pain was seen after 1 month of surgery and GnRH therapy. 6 months later CA125 level was 47 U/ml.

## Discussion and Conclusion

Endometriosis is a common debilitating benign gynecologic condition and occurs in approximately 7-10% of women in the general

population [3]. It is an estrogen-dependent disease and therefore, usually affects reproductive-aged women. Among women with intestinal endometriosis, the rectum and sigmoid colon are the most commonly involved areas (75–90%) [4]. Other parts of the bowel less commonly affected are the distal ileum (2–16%) and appendix (3–18%). Classically, the hallmark symptom of colonic endometriosis is rectal bleeding during menstruation; however, intussusception, hemorrhage, perforation, small bowel or colonic obstruction has also been reported [5]. There are many theories explaining the pathophysiology of this disease, but, most widely accepted is a retrograde flow of endometrial tissue through the fallopian tubes into peritoneal cavity and then to the intestinal wall where external implantation occurs. Diagnosis of intestinal endometriosis is difficult as the implanted lesion is hard to reach the colonic mucosa [6]. Before this, it is important to consider it in the differential diagnosis of such presentation even if no overt colonoscopic pathology is found.

The goals of the treatment are to relieve the symptoms (pain relief, defecation, urination), decrease the recurrence rate and enhance the fertility. Medical therapy should be given after discussion with the gynecologist and includes NSAIDs or GnRH analogs, oral contraceptive pills, aromatase inhibitors and progestins. Surgical intervention is indicated when the symptoms of endometriosis are severe, there has been an inadequate response to medical treatment or there is anatomic distortion of the pelvic organs or obstruction of the bowel or urinary tract.

If surgery is indicated in colonic endometriosis, GnRH agonists should not be used before surgery to reduce the extent of peritoneal (superficial implants) disease [7]. By reducing the implants' size and number, the surgery will be more difficult as the surgeon will not find the actual size and number of the deposits, therefore, affect the surgical

outcome. Unlike post-operative, use of GnRH agonist immediately following surgery reduces the rate of symptom recurrence and increases the length of time before symptoms recur [8]. Laparotomy or laparoscopic intervention is also a controversial issue in colonic endometriosis. It seems to be equally effective in the treatment of infertility and chronic pelvic pain associated with severe endometriosis. Laparoscopic surgery has advantages in terms of hospital stay, early mobilization and wound infection but in such cases requires an experienced surgeon.

## References

1. Meyers WC, Kelvin FM, Jones RS (1979) Diagnosis and surgical treatment of colonic endometriosis. *Arch Surg* 114: 169-175.
2. Hemmings R (1998) Combined treatment of endometriosis: GnRH agonists and laparoscopic surgery. *J Reprod Med* 43: 316-320.
3. Wheeler JM (1989) Epidemiology of endometriosis-associated infertility. *J Reprod Med* 34: 41-46.
4. Bergqvist A (1992) Extragenital endometriosis: A review. *Eur J Surg* 158: 7-12.
5. Varras M (2002) Endometriosis causing extensive intestinal obstruction simulating carcinoma of the sigmoid colon: A case report and review of the literature. *Eur J Gynaecol Oncol* 23: 353-357.
6. Liu DT, Hitchcock A (1986) Endometriosis: Its association with retrograde menstruation, dysmenorrhoea and tubal pathology. *Br J Obstet Gynaecol* 93: 859-862.
7. Rowland R, Langman JM (1989) Endometriosis of the large bowel: A report of 11 cases. *Pathology* 21: 259-265.
8. Schweppe KW, Hummelshoj L (2011) Recommendations on the use of GnRH in the management of endometriosis. In: Lunenfeld B (ed). *GnRH Analogs* 2: 1.