

Research

Radiation-Induced Sarcomas of the Head and Neck

Liuzzi Juan F*, DaCunha Maribel, Siso Saul, Salas Daniuska

Head and Neck Department, Oncology Hospital of the Venezuelan Institute of Social Security, Caracas 1040, Venezuela

*Correspondence should be addressed to Juan FL, Attending Head and Neck Surgeon of the Head and Neck Department, Oncology Hospital of the Venezuelan Institute of Social Security, Caracas 1040, Venezuela, E-mail: jfliuzzi@gmail.com.

Received: 30 August 2019 • Accepted: 12 September 2019

ABSTRACT

Background: Head and neck sarcomas are uncommon clinical entities and radiation-induced sarcomas of the head and neck (RISHN) even more. They comprise a very serious long-term complication of radiation therapy.**Patients and methods:** We reviewed the medical records of all patients with diagnosis of head and neck sarcomas evaluated and treated in our Hospital from 2005 to 2015, and selected those who had sarcomas related to the use of external beam radiotherapy.**Results:** The incidence of RISHN was 17.5% among all head and neck sarcomas evaluated. Most patients had sarcomas located at the maxillary sinus. Leiomyosarcoma was the most common histological type. The latency period average between time of initial radiation therapy and time of diagnosis of RISHN was 18.4 years. Patients received single or combined treatment modalities, including surgery, chemotherapy and/or radiation therapy, according to the criteria for tumor resectability. The average follow-up was 24.42 months and the disease free-survival rate at the end of the study was 28.6%.**Conclusions:** The overall prognosis of RISHN is poor regardless the modality of treatment received. Despite the difficulties to perform a surgical procedure in a radiated field, we consider surgery the best option to treat RISHN, over chemotherapy and radiation therapy.**Keywords:** Head and neck, radiation-induced sarcomas.

Copyright © 2019 Liuzzi Juan F, et al. This is an open access paper distributed under the Creative Commons Attribution License. European Journal of Clinical Oncology is published by Lexis Publisher.

INTRODUCTION

Radiotherapy is a common modality of treatment for some types of head and neck cancers. It could be used as a definitive treatment or as an adjuvant therapy as well. Sometimes radiotherapy induces the development of other tumors, such as squamous cell carcinomas and sarcomas. These tumors are known as radiation-induced second malignancies. In particular, radiation-induced sarcomas (RIS) are probably the most devastating of the late complications of radiotherapy [1].

RIS represent less than 5% of all sarcomas and account approximately 12% of all radiation-induced second malignancies, being the second most common after radiation-induced squamous cell carcinoma [2].

Radiation-induced sarcomas of the head and neck (RISHN) have been related with poor prognosis, when compared to *de novo* sarcomas located in the same areas. Probably, the main reason is that the diagnosis is more difficult due to the radiation-associated tissues changes that occur in the radiation field. Another important reason is the difficulty to perform surgery or to give more radiation within a previous irradiated area [3].

The purpose of this case series report is to describe all the clinical aspects of the patient with diagnosis of RISHN treated in our Hospital and to make a review of the literature.

PATIENTS AND METHODS

The study was focused on patients with head and neck sarcomas evaluated and treated from 2005 to 2015 at the Head and Neck Department of the Oncology Hospital of the Venezuelan Institute of Social Security (**Figures 1-3**). We selected those patients with sarcomas that met the criteria for radiation-induced sarcomas proposed by Cahan et al. [4] in 1948 and modified by Arlen et al. [5] in 1971. The criteria are the following:

- The sarcoma must arise in an irradiated field.
- The patient must have a documented history of previous radiotherapy in the head and neck area.
- The sarcoma must be histologically different from the original tumor.
- The latency period must be more than 3 years (defined as the interval from the initiation of the first radiation therapy to the onset of the RIS).

After review the clinical records of each eligible patient, we obtained data including epidemiological characteristics, details of primary disease and the treatment received, latency period for the second malignancy, treatment of the RISHN, follow-up and outcome.

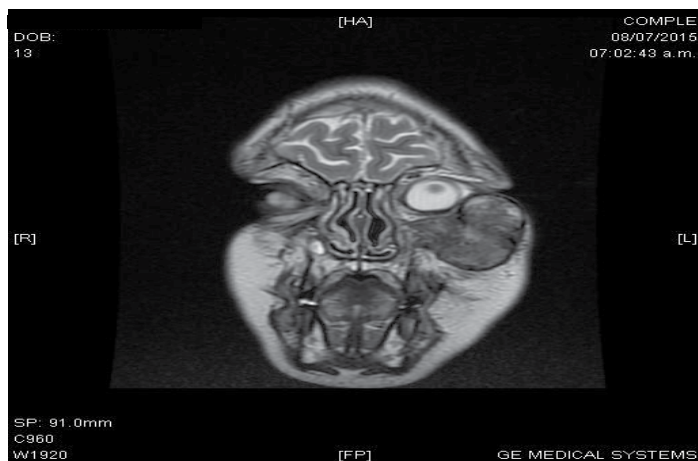


Figure 1: MRI showing a leiomyosarcoma arising from the left maxillary sinus in a 16-year old male patient with history of retinoblastoma treated with radiation therapy at age of 2-year old, this tumor was considered unresectable and was treated with chemotherapy and EBRT.

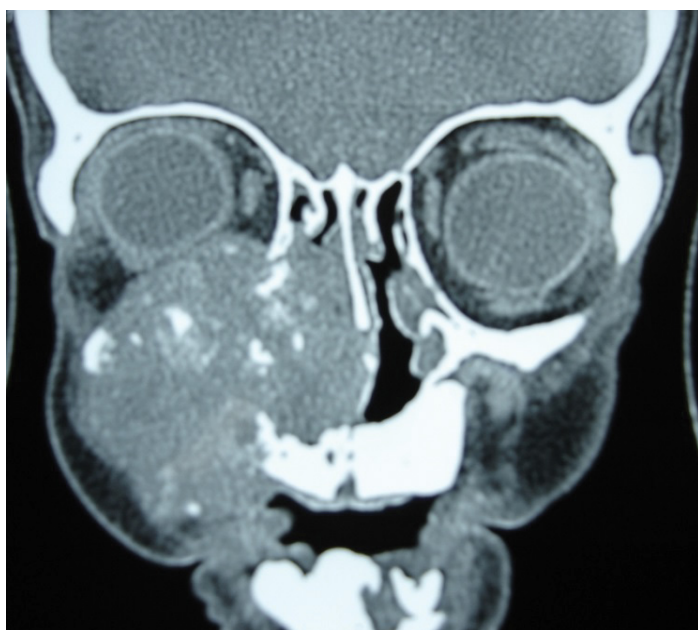

Figure 2: CT scan with a high-grade osteoblastic osteosarcoma of the right maxillary sinus in a 21-year old male patient with history of oropharyngeal rhabdomyosarcoma treated with chemotherapy and radiation therapy at age of 10-year old. This patient underwent chemotherapy and EBRT.

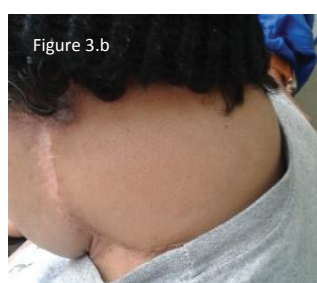
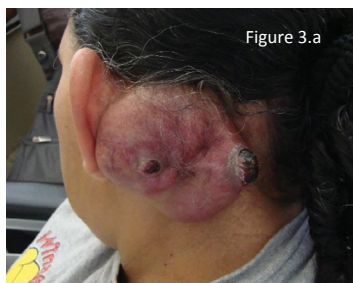
Figure 3: 63-year old female patient with a rhabdomyosarcoma of the posterior neck (a) With history of a posterior fossa meningioma treated with surgery and radiation therapy at age of 42-year old (b) This patient underwent surgery with wide resection of the tumor and reconstruction.

RESULTS

Forty patients with diagnosis of head and neck sarcomas were evaluated and treated from 2005 to 2015 at the Head and Neck

Department of the Oncology Hospital of the Venezuelan Institute of Social Security. Seven patients matched with the criteria for RIS (17.5%). **Table 1** summarizes all the data of these patients. Incidence of RISHN was higher in males than females (male 2.5:1 female). The average age was 36.9 years (range from 16 to 64 years). Retinoblastoma and rhabdomyosarcoma were the most common tumors considered as primary diseases for which patients received radiation therapy. Five patients had their primary disease when they were at a pediatric age. The average latency period from irradiation of the primary disease to the diagnosis of RIS was 18.4 years (range from 11 to 32 years). The average radiation dose for the primary condition was 50 Gy (30-60 Gy).

Histological types of RIS were diverse, being leiomyosarcoma the most common. Five RIS had high grade of differentiation (71.43%). Five tumors were located in the paranasal sinus region, mainly at the maxillary sinus. No patients had regional lymph nodes or distant metastasis at the time of diagnosis. All the patients received treatment. Three patients underwent surgical treatment with wide local resection followed by external beam radiation therapy. The rest of the patients had unresectable tumors and received chemotherapy and/or external beam radiotherapy.

The average follow-up was 24.42 months (range from 8 to 60 months). During the follow-up, one of the three patients that underwent surgery plus radiotherapy had distant relapse and died of disease 34 months after surgery; the other two patients were free of disease at the end of their follow-up. No one of these three patients developed local failure. The other four patients that underwent chemotherapy and/or radiotherapy, developed disease progression under treatment and died of distant metastasis.

In summary, at the end of the follow-up, two patients were alive with no evidence of disease, and five patients had died of disease. The disease free-survival at the end of the study was 28.57% and mortality was 71.42%.

DISCUSSION

The incidence of radiation-induced tumors has been rising in the last decades. This phenomenon has been occurring due to the increase in the use of radiotherapy for treat a wide spectrum of malignant tumors, in addition to the longer life expectancy of patients after receiving treatment [6] According to Brady et al. [2], the incidence of RIS is less than 5%; however, the incidence in our research was higher, reaching 17.5%.

Although radiation therapy is used to treat malignant tumors, its potential carcinogenic effect has been recognized for many years. Second malignancies, usually squamous cell carcinomas and sarcomas, are known to arise within or at the edge of radiation fields after a period of several years after the initial radiation exposure [7].

The precise pathogenic mechanism for the development of radiation-induced tumors is poorly understood. The paradigm focuses on radiation-induced DNA damage leading to mutations in susceptible cells [1]. In this regard, p53 mutations and genetic aberrations in the Rb gene have been implicated. Other studies have demonstrated that changes in microenvironments promote genomic injury in stem cells, playing an important role in tumorigenesis [8]. Lately, the “bystander effect” phenomenon, in which non-irradiated cells exhibit effects as a result of signals received from nearby irradiated cells, has been implicated as well [9-11].

Table 1: Summary of radiation-induced sarcomas of head and neck.

S.No.	Age/Sex	Primary disease	Rad dose	Latency	Localization	Histological type	Treatment	Outcome (Months)
1	24/M	RMS of Eyelid	55 Gy	17 years	Ethmoid sinus	LMS	Surgery plus EBRT	Died of disease 34 m
2	63/F	Posterior fossa Meningioma	60 Gy	21 years	Neck	UPS	Surgery plus EBRT	Free of disease 60 m
3	16/M	Retinoblastoma	35 Gy	14 years	Maxillary sinus	LMS	Chemotherapy	Died of disease 21 m
4	64/M	Laryngeal SCC	60 Gy	15 years	Neck	EHE	EBRT	Died of disease 14 m
5	34/M	Retinoblastoma	Unknown	32 years	Maxillary sinus	LMS	Surgery plus EBRT	Free of disease 8 m
6	29/M	Oropharyngeal RMS	30 Gy	19 years	Maxillary sinus	Osteoblastic osteosarcoma	Chemotherapy	Died of disease 23 m
7	28/F	Oropharyngeal Adenocarcinoma	60 Gy	11 years	Maxillary sinus	Fibrosarcoma	Chemotherapy	Died of disease 11 m

M: Male; F: Female; RMS: Rhabdomyosarcoma; LMS: Leiomyosarcoma; EBRT: External Beam Radiotherapy; UPS: Undifferentiated Pleomorphic Sarcoma; SSC: Squamous Cell Carcinoma; EHE: Epithelioid Hemangioendothelioma

In 1948, Cahan et al. [4] described the conditions to establish a relation between radiation and sarcoma genesis. These statements were modified in 1971 by Arlen et al. [5] and are currently in use.

On regards to the best interval to establish if a sarcoma of head and neck is considered a RIS, continues to be a subject of debate. The original lapse for this latent period was 5 years. Subsequent modifications have intended decrease the interval inclusive to 6 month [12-14]. For RISHN, arbitrary periods of 3-4 years have been used as cutoffs, based on a consensus that this was a sufficient gap for radiation carcinogenesis to occur [15,16]. In our study, we observed a latency period with a range of 11 to 32 years with a median latency period of 18.43 years; all patients had more than 5 years of latency.

In our report, we observed that five of seven patients received radiation therapy at a pediatric age, mostly under 10 years old. A younger age at initial diagnosis has been considered an important risk factor for the development of secondary sarcomas. There are some reasons for the susceptibility of younger patients to develop RIS. First, young people have higher number of stem cells with high proliferative rates, which makes them more sensitive to have tumorigenic changes when they are exposed to radiation. Second, radiotherapy usually inhibits proliferation of irradiated cells; but this could be less effective in some organs during youth. Finally, many types of childhood cancers involve a germline mutation, increasing the sensitivity to radiation-induced cancer. Retinoblastoma, the most common primary intraocular cancer in children, has been related with germline mutations [1,17]. Two of our patients had this condition as their primary disease.

Regarding the location, there is no subsite predilection; they can arise in any irradiated tissue of mesenchymal origin [1,18]. In some recently published series with patients who lived at the Southeast of Asia, where nasopharyngeal carcinoma is endemic, the most common subsites were the nose and paranasal sinus region [19-21]. In our research, the most common site for RISHN was the paranasal sinus region, mainly the maxillary sinus. This was the most common location due to the majority of initial tumors was close to the paranasal sinus (eye and oropharynx).

RISHN can include osseous and soft tissue sarcomas; the vast majority of them are high-grade differentiated. The most common histologic subtype of RIS in many reported series is sarcoma NOS (formerly referred to as malignant fibrous histiocytoma). Other usual tumors include osteosarcoma, chondrosarcoma, fibrosarcoma, angiosarcoma and rhabdomyosarcoma (particularly in children) [16,18,19,22,23]. Leiomyosarcoma is not known as a common RISHN [24,25], however we report three of seven patients with this type of tumor. There is no specific histopathological criteria for determining differences between RIS and *de novo* sarcomas, however, some changes in the morphology of adjacent

tissues may be suggestive of RIS: e.g. the form of dense cellular fibrosis plaques, presence of atypical fibroblasts, alteration of the vascular architecture and abundant fibrous stroma in the dermis adjacent to the sarcoma [26].

Management of these tumors is complex and challenging. Patients should be treated according to the same principles of *de novo* sarcoma patients, however, there are some limitations given by the previous therapy. Surgical resection with clear margins appears to offer the best chance for cure, but surgery in irradiated tissue is a limited tool, and even more in head and neck due to the proximity to critical neurovascular structures [18]. Bjerkehagen et al. [27] reported a high percentage of positive margins and local recurrence in those patients with RIS who underwent surgery, concluding that local control is difficult to achieve in this type of tumors. Patient with unresectable criteria could be treated with chemotherapy and/or radiotherapy, which is difficult when the sarcomas are arising in a previous irradiated field [1,28].

A great number of *de novo* sarcomas receive adjuvant radiotherapy [29], but in RIS the role of adjuvant radiation therapy remains unclear. The major limitation is the amount of prior radiation delivered in the same field. Factors that need to be considered include: previous volume and dose fractionation schedule, critical tissues, organs at risk and the time elapsed since the first treatment.

Outcome of RISHN has been estimated worse than *de novo* sarcomas. Some of the explanations are the following:

- Delay in making a diagnosis.
- Close or positive surgical margins, due to proximity of the tumor to critical structures.
- Limited of treatment options in a radiated field.
- Poor tumor sensitivity to chemotherapy.
- The majority of RISHN are high-grade tumors [3,30,31].

Disease free-survival at the end of the study was 28.57% and mortality rate was 71.42%. These data support that the overall prognosis for patients with RISHN is poor.

CONCLUSION

In conclusion, RISHN are one of the most serious long-term complication of radiation therapy. Management of these tumors is difficult due to the delay in making an early diagnosis and the challenging to achieve a definitive curative treatment. Overall prognosis is poor even receiving any of the treatment modalities usually given to *de novo* sarcomas. We consider that surgery with clear margins is the best option in resectable tumors with similar local control than other sarcomas, in spite of the difficulties to perform a surgical procedure in a radiated field.

REFERENCES

1. Thiagarajan A, Iyer NG. Radiation-induced sarcomas of the head and neck. *World Journal of Clinical Oncology*. 2014; 5(5): 973-981.
2. Brady MS, Gaynor JJ, Brennan MF. Radiation-associated sarcoma of bone and soft tissue. *Arch Surg*. 1992; 127(12): 1379-1385.
3. Gladdy RA, Qin LX, Moraco N, Edgar MA, Antonescu CR, Alektiar KM, et al. Do radiation-associated soft tissue sarcomas have the same prognosis as sporadic soft tissue sarcomas? *J Clin Oncol*. 2010; 28: 2064–2069.
4. Cahan WG, Woodard HQ. Sarcoma arising in irradiated bone; report of 11 cases. *Cancer*. 1948; 1: 3–29.
5. Arlen M, Higinbotham NL, Huvos AG, Marcove RC, Miller T, Shah IC. Radiation-induced sarcoma of bone. *Cancer*. 1971; 28: 1087–1099.
6. Zhu W, Hu F, Zhao T, Wang Ch, Tao Q. Clinical characteristics of radiation-induced sarcoma of the head and neck. Review of 15 cases and 323 cases in the literature. *Journal of Oral and maxillofacial surgery* 2015; 74(2): 283-291.
7. Brachman DG, Hallahan DE, Beckett MA, Yandell DW, Weichselbaum RR. p53 gene mutations and abnormal retinoblastoma protein in radiation-induced human sarcomas. *Cancer Res*. 1991; 51: 6393–6396.
8. Barcellos-Hoff MH, Nguyen DH. Radiation carcinogenesis in context: How do irradiated tissues become tumors? *Health Phys*. 2009; 97: 446–457.
9. Goldberg Z, Lehnert BE. Radiation-induced effects in unirradiated cells: A review and implications in cancer. *Int J Oncol*. 2002; 21: 337–349.
10. Najafi M, Fardid R, Hadadi G, Fardid M. The Mechanisms of Radiation-Induced Bystander Effect. *Journal of Biomedical Physics & Engineering*. 2014; 4(4): 163-172.
11. Mothersill C, Seymour C. Radiation-induced bystander effects, carcinogenesis and models. *Oncogene*. 2003; 22(45): 7028.
12. Cha C, Antonescu CR, Quan ML, Maru S, Brennan MF. Long-term results with resection of radiation-induced soft tissue sarcomas. *Ann Surg*. 2004; 239: 903–909.
13. Johns MM, Concus AP, Beals TF, Teknos TN. Early-onset postirradiation sarcoma of the head and neck: report of three cases. *Ear Nose Throat J* 2002; 81: 402-406.
14. Laskin WB, Silverman TA, Enzinger FM. Postradiation soft tissue sarcomas. An analysis of 53 cases. *Cancer* 1988; 62: 2330-2340 .
15. Lau GSK, Chan JYW, Wei WI. Role of surgery in the treatment of radiation-induced sarcomas of the head and neck. *J Cell Sci Ther* 2011.
16. Huber GF, Matthews TW, Dort JC. Radiation-induced soft tissue sarcomas of the head and neck. *J Otolaryngol* 2007; 36: 93-97.
17. de Bree R, Moll AC, Imhof SM, Buter C, Leemans R. Subsequent tumors in retinoblastoma survivors: The role of the head and neck surgeon. *Oral oncology* 2008; 44: 982-985.
18. Patel SG1, See AC, Williamson PA, Archer DJ, Evans PH. Radiation induced sarcoma of the head and neck. *Head Neck*. 1999 Jul; 21(4): 346-354.
19. Yeang MS, Tay K, Ong WS, Thiagarajan A, Tan DS, Ha TC, et al. Outcomes and prognostic factors of post-irradiation and de novo sarcomas of the head and neck: a histologically matched case-control study. *Ann Surg Oncol*. 2013; 20: 3066–3075.
20. Wei Z1, Xie Y, Xu J, Luo Y, Chen F, Yang Y, et al. Radiation-induced sarcoma of head and neck: 50 years of experience at a single institution in an endemic area of nasopharyngeal carcinoma in China. *Med Oncol*. 2012 Jun; 29(2): 670-676.
21. Chung J, Lee V, Tsang R, Chan J, Kwong D, Lam K et al. Treatment outcomes of post radiation second head and neck malignancies managed by a multidisciplinary approach. *Head & Neck* 2015; 815-822.
22. Mark RJ, Bailet JW, Poen J, Tran LM, Calcaterra TC, Abemayor E, et al. Postirradiation sarcoma of the head and neck. *Cancer* 1993; 72: 887-893.
23. Riad S, Biau D, Holt G, Werier J, Turcotte R, Ferguson P et al Clinical and Functional Outcome for Patients With Radiation-Induced Soft Tissue Sarcoma. *Cancer* 2012; 15; 118(10): 2682-2692.
24. Souza R, Ramoa F, Ferreira A, AjudartebM, Jorge J. Leiomyosarcomas of the oral cavity: report of a radiation-associated and a metastatic case. *Oral Maxillofac Surg* 2012; 16: 227-232.
25. Pfeiffer J, Boedeker C, Ridder G, Maier W, Kayse G. Radiation-induced leiomyosarcoma of the oropharynx. *Diagn Pathol* 2006; 1: 22.
26. Thariat J, Italiano A, Collin F, Iannesi A, Marcy P, Lacout A et al. Not all sarcomas developed in irradiated tissue are necessarily radiation-induced. Spectrum of disease and treatment characteristics. *Critical reviews in oncology/hematology* 2012; 83: 393-406.
27. Bjerkehagen B, Smastuen MC, Hall KS, Skjeldal S, Smeland S, Fossa SD. Why do patients with radiation-induced sarcomas have a poor sarcoma-related survival? *Br J of Cancer* 2012; 106: 297-306.
28. Blay JY, Le Cesne A. Adjuvant chemotherapy in localized soft tissue sarcomas: still not proven. *Oncologist*. 2009; 14:1013-1020.
29. Liuzzi JF, Da Cunha M, Salas D, Siso S, Garriga E. Soft-tissue sarcomas in the head and neck: 25 years of experience. *Ecancermedicalscience*. 2017; 11: 740.
30. Yang Q, Mo Y, Zhao Q, Ban X, He M, Cai P, et al. . Radiation-induced sarcomas of the head and neck in post-radiation nasopharyngeal carcinoma. *Radiol Med*. (2017) 122: 53–60.
31. Giannini L, Incandela F, Fiore M, Gronchi A, Stacchiotti S, Sangalli C, Piazza C. Radiation-induced sarcoma of the head and neck: a review of the literature. *Frontiers in oncology*. 2018; 8.