

## Use of Transcranial Doppler for Monitoring Hepatic Encephalopathy

Cacciatori A<sup>1,2\*</sup>, Castelli J<sup>1,3</sup> and Grecco G<sup>3</sup>

<sup>1</sup>Central Hospital of the Armed Forces, Uruguay

<sup>2</sup>National Institute of Donations and Transplants, Uruguay

<sup>3</sup>Bi-institutional unit of the Hospital de Clínicas and the Central Hospital of the Armed Forces, Uruguay

\*Corresponding author: Armando Cacciatori Castro, Medical Doctor in chief of the ICU, Central Hospital of the Armed Forces, Jaime Zudáñez 2768, apto. 1001, Uruguay; Tel: 2710 02 9, PC: 1300; E-mail: [armataba@gmail.com](mailto:armataba@gmail.com)

Received date: February 23, 2015; Accepted date: March 30, 2015; Published date: April 06, 2015

Copyright: ©2015 Cacciatori A. This is an open-access article distributed under the terms of the Creative Commons Attribution License, which permits unrestricted use, distribution, and reproduction in any medium, provided the original author and source are credited.

### Abstract

Fulminant hepatic failure (FHF) is an acute and severe disease that can lead to death by the development of encephalopathy. Due to the severe alterations of coagulation that go along with this clinical picture, it may be contraindicated to place a sensor for monitoring intracranial pressure (ICP); it is for this reason that the option of the transcranial doppler (TCD) arises as an auxiliary method for monitoring these patients. The aim of this work was to present our first steps in the implementation of this technique in an intensive care unit (ICU) which is a reference center in liver transplant. Two clinical cases of young women, carriers of FHF with severe encephalopathy, were analyzed. The daily monitoring of these patients allowed us to identify changes in intracranial hemodynamics, expressed by "sistolized" patterns in the flow rates of cerebral arteries, coinciding with increases in the pulsatility index (PI) and the resistance index (RI). These findings suggest that an increased ICP coincides with those published in other series analyzed. Monitoring of hepatic encephalopathy by TCD is useful, becoming a method which is being implemented more and more every day in neurointensive treatment.

**Keywords:** Transcranial doppler; Liver failure; Liver encephalopathy; Liver transplant

### Introduction

Transcranial doppler (TCD) is an auxiliary method which is useful for measuring cerebral blood flow velocities, integrating neuromonitoring techniques in the intensive care unit (ICU).

It is a non-invasive, inexpensive, and simple to perform method, which does not require the patient to be transferred from the ICU to another hospital sector and can be done at the foot of the bed.

The fulminant hepatic failure (FHF) is a condition characterized by a rapid deterioration of the liver function, which is accompanied by a severe impairment of the neurological status in previously healthy patients. These changes are caused by the necrosis of hepatocytes. Brain damage is caused by an increase in intracranial pressure (ICP) with consequent cerebral ischemia. This fact is very important because brain damage constitutes a criterion for deciding liver transplantation.

### Objective

To present the utility of TCD as a neuromonitoring technique to monitor hepatic encephalopathy, knowing that crisis disorders that go along with hepatic failure may be contraindicative of the ICP sensor placement.

### Materials and Methods

Analysis of two patients that were admitted to the ICU of the Central Hospital of the Armed Forces, because of a severe and acute liver failure with encephalopathy. Both developed into a coma, with

reactivity in extensive-pronation, requiring artificial airway and mechanical respiratory assistance (MRA).

Tomographic images and TCD records will be discussed. The TCD equipment used for insonation of the cerebral vessels was a US SonaraTek 2007 model. The arteries of the anterior and posterior sector of the Circle of Willis were insonated daily.

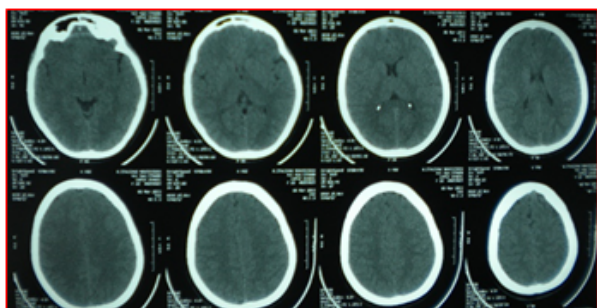
### Medical Record 1

I.L. Female. 22 years old. Admission date at the ICU: 7/03/2013. Discharge date of the ICU: 15/03/2013. No highlighted PA. The week previous to admission she was feeling fatigue, weakness, malaise, nausea and was vomiting. In the evolution she develops jaundice and episodes of mental confusion. She goes to a medical consultation in an Institution of Mutual Health Care, and she enters a medical ward for treatment and monitoring.

Of the complementary tests made, are highlighted: Total bilirubin: 10.03 mg%, Direct Bilirubin: 8.08 mg%. GOT: 2611 U/ml, GTP: 2203 U/ml. LDH: 1196 U/ml. Prothrombin time: 10%. INR: 8, 81. Ammoniemia: 429. Her family denied the intake of toxic substances. HBs Ag shows weak reactivity. HVC (-), HVA (-), HIV (-).

With a fulminant hepatic failure diagnosis, she was transferred to the ICU of the Central Hospital of the Armed Forces. She is admitted in a coma; GSS: 4 (no eye opening to nociceptive stimulation, extensive-pronation of the members, no verbal response), keeping brainstem reflexes (BS). Hypoglycemia was corrected with administration of glucose solutions.

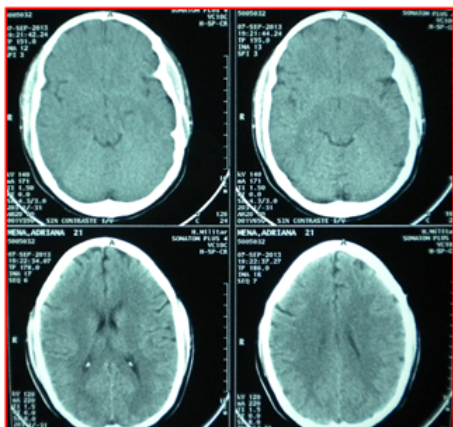
The computerized axial tomography (CAT) of the head showed a diffuse increase in the brain volume, with disappearance of the grooves of the convexity and compression of the lateral ventricles (Figure 1).



**Figure 1:** CAT scan of the skull where the increase in the volume of the brain is observed. I.L Female. 22 years old.

An endotracheal intubation (EI), a connection to MRA, femoral venous access, and bladder catheter were performed. She evolves with partial seizures. She develops respiratory sepsis by *Staphylococcus aureus* methicillin-sensitive (MSSA) with evolution to septic shock.

Due to the severe impairment of the blood crisis, the ICP invasive monitoring could not be performed. TCD insonation was performed



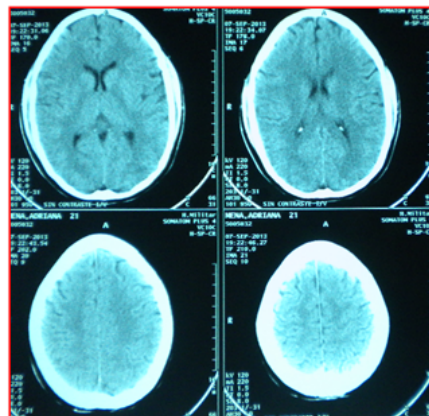
**Figure 2:** CAT scan of the skull that shows a slight increase in the brain volume. A.M. Female. 21 years old.

## Medical record 2

A.M. 21 years old. Female. From the department of Cerro Largo. Admission date: 6/09/2013. Discharge date of the ICU: 10/09/2013. She was recently diagnosed with Wilson's disease, she is sent to Montevideo for studying because of an acute and severe hepatic impairment, she was admitted at the Medicine Room. The pre-transplant evaluation was initiated. She develops a fever and hyperleucocytis. Subsequently, her consciousness starts being impaired, expressed by somnolence, space-time disorientation, vomiting, abdominal pain and bloating. Diagnostic paracentesis was performed, and the study showed a polymorphonuclear count of the order of 260, suggestive of spontaneous peritonitis.

She is admitted to the ICU, artificial airway was performed and a connection to MRA. Neurological evaluation highlights reactivity in

extensive-pronation, without eye opening and without gestural response. GSS: 4. CAT scan of the skull reveals a slight increase in the brain volume and absence of intracranial bleeding (Figures 2 and 3).




**Figure 3:** CAT scan of the skull that shows a slight increase in the brain volume. A.M. Female. 21 years old.

Due to the alteration of blood crisis with a Prothrombin time of the order of 6%, it could not be indicated an ICP monitoring, therefore it was requested to follow a TCD daily.

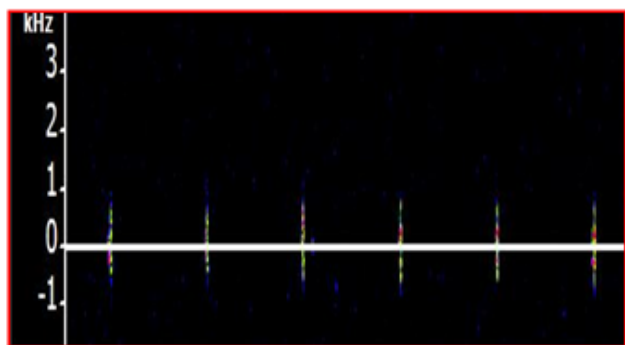
## Results

In the first case, the first records showed at the anterior circle of Willis, middle cerebral artery (MCA) and anterior cerebral artery (ACA) bilaterally: a continuous flow, with a sharp drop in diastolic phase curve corresponding to a "sistolized" pattern with increased pulsatility indices (PI) and resistance indices (RI), which suggest an increase of brain resistances (Figure 4 and Table 1). This fact is correlated with an increase in the ICP. An aggressive treatment of ICH administered boluses of hypertonic saline, optimizing sedation-analgesia was performed using muscle relaxants.

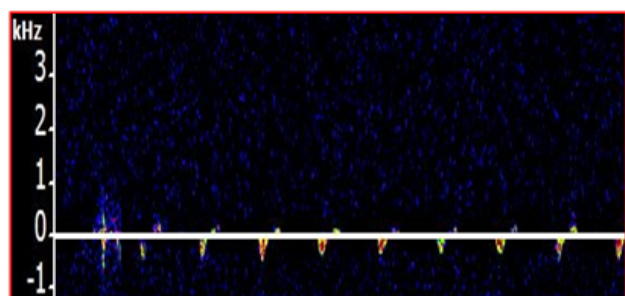


**Figure 4:** Insonation of left middle cerebral artery (MCA) and anterior cerebral artery (ACA). Bifurcation zone. "Sistolized" pattern. I.L- Female. 22 years old.

Despite the therapeutic measures, the patient developed unfavorably. On the last day of stay in the ICU, the study TCD showed at both the anterior and the posterior of the circle of Willis a circulatory pattern consistent with cerebral circulatory arrest (CCA) that accompanies brain death (BD) (Figures 5 and 6).

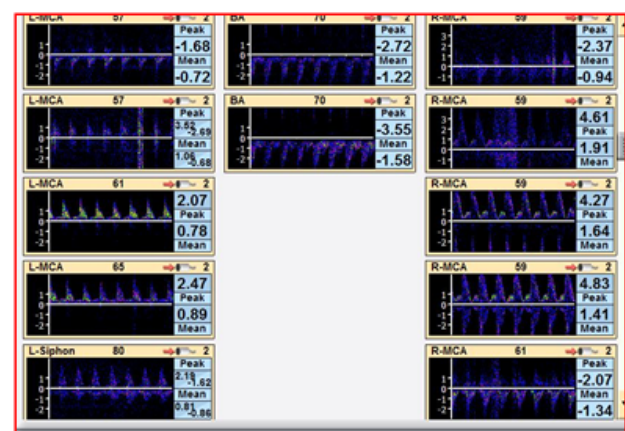


**Figure 5:** Right middle cerebral artery (MCA) systolic spikes corresponding to CCA accompanying the BD. I.L. Female 22 years old.

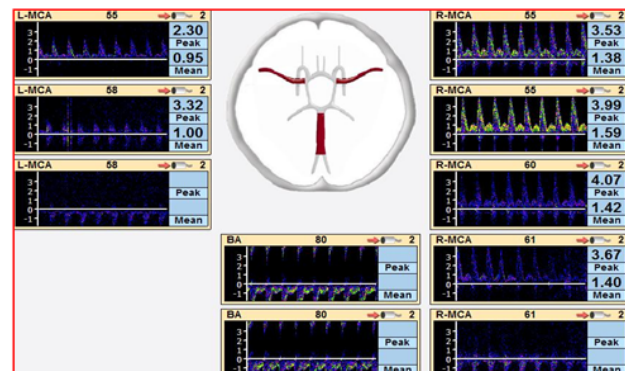


**Figure 6:** Insonation of the basilar artery (BA). Reversed diastolic flux (reverberant) compatible with CCA accompanying BD. I.L. Female 22 years old.

In the second case, in the studies conducted during the early days, the TCD “sistolized” patterns of high resistance in the anterior and posterior areas of the circle of Willis (Figures 7 and 8).



**Figure 7:** “Sistolized” pattern of high resistance in the anterior and posterior areas of the circle of Willis. A.M. Female. 21 years old.



**Figure 8:** “Sistolized” pattern of high resistance in the anterior and posterior areas of the circle of Willis. A.M. Female. 21 years old.

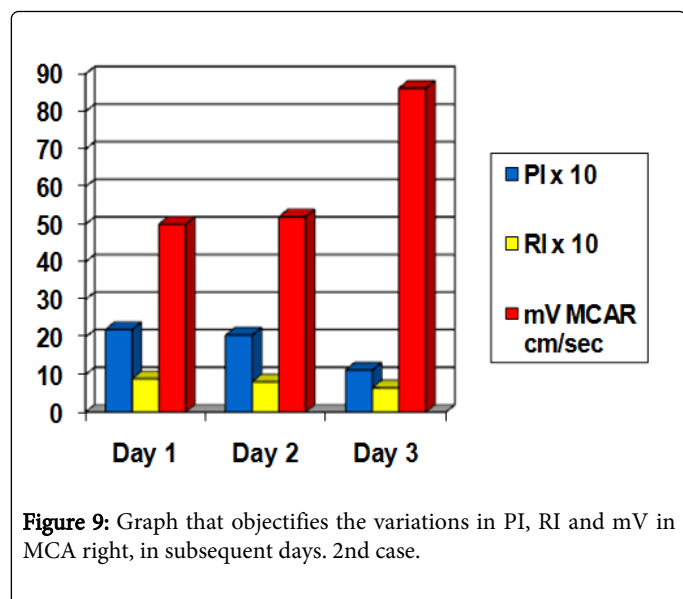
By following up with TCD it was evidenced an increase in the PI and the RI (Figure 9 and Table 1), highlighting a transitory improvement in the third register of the circulatory pattern due to therapeutic measures to control of the ICH.

This fact was also expressed by an increase in the average speeds in the MCA.

Patient	Date	Insonated vessel	Depth	PI	RI	mV	Pattern
I.L.	10/3/2013	MCA Right	46 mm	3.34	0.95	52 cm/sec	Sistolized
I.L.	11/3/2013	MCA Right	46 mm	6.84	0.97		Systolic spikes
A.M.	7/9/2013	MCA Right	55 mm	2.20	0.89	50 cm/sec	Sistolized
A.M.	8/9/2013	MCA Right	55 mm	2.05	0.81	52 cm/sec	Sistolized
A.M.	9/9/2013	MCA Right	55 mm	1.12	0.65	86.2 cm/sec	Continues/ notsistoliz
A.M.	10/9/2013	MCA Right	55 mm				Reverberant flow



**Table 1:** Pulsatility and resistance indices found in subsequence studies and their relationship with mean arterial velocities and circulatory patterns.





In the evolution it adds hemodynamic deterioration and distress, with clinical suspicion of multiple organ dysfunction (MOD), of infectious origin.

The study conducted on the last day of her stay in the ICU, showed a pattern consistent with CCA accompanying BD (Figure 10 and 11).



## Discussion

Clinically, the hepatic encephalopathy is usually identified by the impairment of consciousness and development of various motor and intellectual abnormalities, which can range from subtle cognitive deficits to coma.

This neurological syndrome is accompanied by slow-path electroencephalogram (EEG) where triphasic waves can be recognized [1].

The most frequent cause of hepatic encephalopathy is the decompensation of chronic liver diseases. However, the most serious and rapid way of this encephalopathy is distinguished in the fulminant liver failure, either toxic, immune or viral in origin [1].

Acute liver failure, also known as fulminant hepatic failure (FHF), encompasses a spectrum of clinical entities characterized by: acute liver injury, severe hepatic dysfunction and hepatic encephalopathy. Even though it is not very common, its prevalence is approximately 2000 cases per year in the United States, with mortality ranging from 50 to 90% [2].

The clinical evolution time has prognostic implication, due to its relation to the different etiologies and outcomes [3].

The loss of hepatocyte function triggers a systemic inflammatory response (SIRS) with multiple organ dysfunction (MOD) that can lead to death. The orthotopic liver transplantation is the only definitive treatment for those patients with FHF and for those whose liver cannot recover its function spontaneously. The cerebral edema that causes the intracranial hypertension (ICH) complicates approximately between 50 and 80% of patients with FHF (III or IV grade) and becomes a death cause [4,5]. Cerebral edema and ICH do not occur in patients with cirrhosis and chronic hepatic failure. Unfortunately, many patients die due to ICH and brain herniation. So, early diagnosis and aggressive therapy to control ICH prevent the evolution to exitus, waiting for an organ donor, or until spontaneous recover of hepatic function occurs [2].

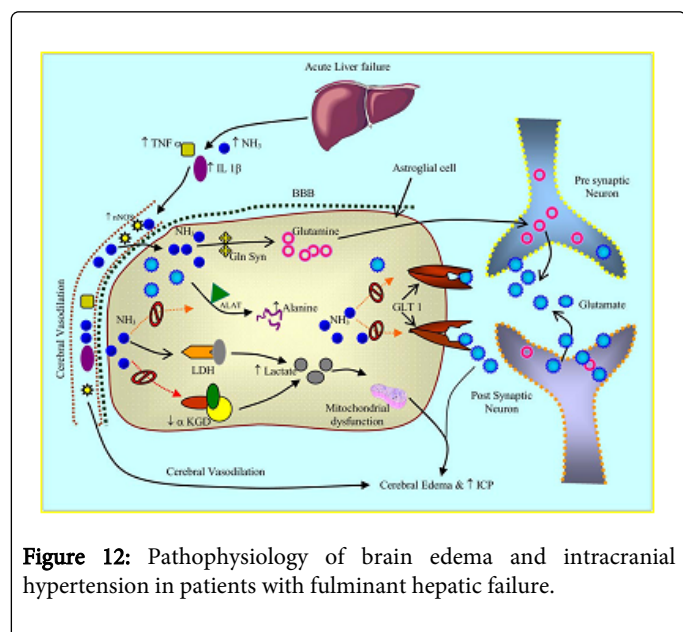
Production brain edema and ICH mechanisms in the context of FHF are multifactorial and so far, partially understood. They include: cytotoxicity as a result of osmotic effect caused by ammonia, glutamine, other amino acids and proinflammatory cytokines. Cerebral hyperemia and vasogenic edema can occur because of blood-brain barrier disruption with accumulation of low molecular weight substances. Dysfunction of the ATPase Na<sup>+</sup>-K<sup>+</sup> bomb, with consequent loss of autorregulation of cerebral blood flow (CBF), have been implicated as hyperemia causes [2] (Figure 12).

Cranial CT is indicated in those patients with acute liver failure, progressing to stages III/IV of encephalopathy, or experiencing acute changes in consciousness, and before indicating ICP monitoring.

Although CT can often detect brain swelling in patients with acute liver failure and with an advanced stage of encephalopathy, it does not have the sensitivity to prove ICH; so its main value is to discard intracranial bleeding.

Many authors recommend ICP monitoring in patients with advanced encephalopathy, believing that monitoring allows the management of cerebral edema, providing information about neurological recovery after orthotopic liver transplantation [6]. Continuous measurements of ICP perioperatively in the management of FHF, has been associated with a survival rate of 54%-74% in a series of six to 23 patients, which is generally higher than with medical means,

and was a high as 92 % for the selected group who had undergone liver transplantation [7].



**Figure 12:** Pathophysiology of brain edema and intracranial hypertension in patients with fulminant hepatic failure.

The invasive monitoring, however, is specially risky in FHF patients with coagulopathy, in whom the incidence of bleeding from ICP monitoring ranges from 5%–22%, with a mortality rate of 60% [7].

Considering that crasis disorder constitute a severe impediment for placing an ICP, is where the option of TCD arises in order to evaluate changes in cerebral hemodynamic suggestive of ICH. The noninvasive technique provides adequate information when cerebral perfusion is low, comparable with the invasive technique, and allows the ICH is diagnosed and treated effectively [7].

The TCD has been used extensively for monitoring of head injury and cerebral circulatory arrest [8] and has been studied extensively in head trauma patients [9].

Sidi and Mahla compared with simultaneous invasive monitoring of ICP sensor and TCD, in the pre, peri and postoperative orthotopic liver transplantation, in patients with fulminant hepatic failure. They demonstrated the usefulness of both to control ICP, and maintenance for adequate cerebral perfusion pressure (CPP).

The extensive studies of TCD monitoring in head-trauma patients have contributed some information about the relationship between ICP and TCD. Diastolic flow velocity is influenced by cerebral vascular resistance, which is determined mainly by ICP and vessel diameter. TCD images show that diastolic flow velocity becomes zero when ICP equals diastolic blood pressure (10). This is a conclusive warning sign, at which time TCD images of the diastolic component should be compared with diastolic blood pressure (rather than systolic or mean pressure) [7].

PI, which also represents resistance to flow, can be correlated with ICP or cerebral perfusion pressure in head-trauma patients.

CBF measurement with the TCD, present a good correlation with other direct measurements, as the xenon method. The attenuation of the diastolic phase of the curve constitutes a sign of ICH and the consequent decrease in cerebral perfusion. Additionally, the morphology of the curve in the diastolic phase may indicate early or

late ICH signs with the consequent attenuation of the cerebral diastolic flow (2).

Aggarwal et al. published a study in the year 2008, in which, using the TCD, observed changes in the morphology of the velocity curve of cerebral blood flow in patients with FHF, relating cerebral perfusion with the different stages of this disease. In this study, changes were observed in the shape of the curve, as increased levels decreased ICP and CPP values, reaching the images of cerebral circulatory arrest : systolic spikes and retrograde flow during diastole.

The TCD secence indicates, that TCD can provide information about the dynamic state of the intracranial circulation and perfusion. This study indicates that, other easily identifiable and calculable features of TCD waveform that noticeably change as both ICP and CPP, change can be advantageously used to infer the state of cerebral perfusion with little addition of complexity [11].

The authors conclude that, the preliminary results on the correlation of TCD waveform features with the state of cerebral perfusion are promising.

Abdo et al. evaluated CBF by TCD in five patients with FHF and compared with a control group that showed severe neurological alterations not associated with FHF. A pattern of cerebral hypoperfusion was found in 80% of the group with FHF, while in the control group it corresponded to 40%.

Average values of the velocities and PI were 36.6 cm/sec and 2.4 respectively in the FHF group, while in the control group they were 47.8 cm/sec and 1.8 respectively. The authors conclude that patients with FHF showed a predominant pattern of cerebral hypoperfusion (sistolized) with average speed values lower than normal and increased PI [2].

Bindi et al., in a series of 5 patients with FHF, to whom TCD was applied in order to monitor, conclude that this technique allows the evaluation, non-invasive, repeatable and reliable of the changes in CBF, at the head of the patient, avoiding complications associated with an ICP placement. Likewise, it allows time to properly assess the moment for the hepatic transplant indication [12].

## Conclusion

Fulminant hepatic failure (FHF) constitutes an acute and severe nosological entity, which can lead to death, because of encephalopathy development. Cerebral edema is responsible for generating intracranial pressure (ICP), which can lead to brain herniation. FHF brain commitment constitutes a criterion for deciding hepatic transplant.

Due to the fact that it is not always possible to place an ICP sensor, TCD arises as an auxiliary method for monitoring these patients. It has the advantage of being performed at the bedside of the patient; it is noninvasive and can be repeated as many times as necessary. So far, there are few documented series with the use of this technique in monitoring the hepatic encephalopathy.

Daily monitoring of the patients analyzed in this work, allowed the care team to identify changes in intracranial hemodynamics, expressed by “sistolized” patterns in the velocity of cerebral arteries flow, coinciding with increases in pulsatility indices (PI) and resistance indices (RI).

These findings, which suggest the increase in ICP, coincide with those published in other analyzed series. The results of the studies, allowed conducting the therapeutic strategy. However, the evolution of the patients was not good at all, reaching the locking and cerebral circulatory arrest (CCA), accompanying the BD, which is highly expressive of the extreme severity of this disease.

## References

1. Jiménez D, Cartier L (2012) Encefalopatía hepática fulminante vinculada a hiperintensidad de la corteza cerebral en la resonancia magnética. *Revista chilena de neuro-psiquiatría* 50: 51-56.
2. Raghavan M, Marik PE (2006) Therapy of intracranial hypertension in patients with fulminant hepatic failure. *Neurocrit Care* 4: 179-189.
3. Stravitz RT (2008) Critical management decisions in patients with acute liver failure. *Chest* 134: 1092-1102.
4. O'Grady JG (1997) Paracetamol hepatotoxicity: how to prevent. *J R Soc Med* 90: 368-370.
5. Butterworth RF (2003) Molecular neurobiology of acute liver failure. *Semin Liver Dis* 23: 251-258.
6. Todd Stravitz R, Kramer AH, Davern T, Shaikh O, Caldwell SH, et al. (2007). The Acute liver Failure Study Group. Intensive care of patients with acute liver failure : Recommendations of the U.S. Acute Liver Failure Study Group. *Critical Care Med* 11: 2498-2508.
7. Sidi A, Mahla M (1995) Noninvasive Monitoring of Cerebral Perfusion by Transcranial Doppler During Fulminant Hepatic Failure and Liver Transplantation. *Anesth Analg* 80: 194- 200.
8. Newell DW, Seiler RW, Aaslid R (1992) Head injury and cerebral circulatory arrest. In: Newell DW, Aaslid R (eds.) *Transcranial Doppler*. Raven Press, New York, pp. 109-121.
9. Homburg AMI, Jakobsen M, Enevoldsen E (1993) Transcranial Doppler recordings in raised intracranial pressure. *Acta Neurol Scand* 87: 488-493.
10. Hassler W1, Steinmetz H, Gawlowski J (1988) Transcranial Doppler ultrasonography in raised intracranial pressure and in intracranial circulatory arrest. *J Neurosurg* 68: 745-751.
11. Aggarwal S, Brooks DM, Kang Y, Linden PK, Patzer II JF (2008) Noninvasive Monitoring of Cerebral Perfusion Pressure in Patients with Acute Liver Failure Using Transcranial Doppler Ultrasonography. *Liver Transpl* 14: 1048-1057.
12. Bindi ML, Biancofiore G, Esposito M, Meacci I, Bisa M, et al. (2008) Transcranial Doppler sonography is useful for the decision - making at the point of care in patients with acute hepatic failure : a single centre 's experience. *J Clin Monit Comput* 22: 449-452.