

Shoulder Dislocation with Head and Shaft Fracture Ipsilateral

Tomás Pérez Cervera*, Luis Roca and Miguel Ángel Martín Montalvo

Hospital Universitario Virgen Macarena Sevilla, Spain

Abstract

Accompanied shoulder dislocation of the proximal humerus fracture associated with ipsilateral shaft fracture is a rare injury described in literature collection and whose treatment protocol is not clearly established.

Here we present the case of 63 years old male who suffered a fall after slipping in a pool and presented a humeral shaft fracture associated with ipsilateral anterior glenohumeral dislocation and fracture of the proximal humerus in three fragments with involvement of the anatomical neck. The patient underwent a closed reduction first attempt with the help of two needle percutaneous. Axillary artery was injured so had to undergo a second time for another intervention in which we made open reduction and osteosynthesis by proximal humerus long plate and hemiarthroplasty.

Keywords: Shoulder dislocation with shaft fracture; Humeral shaft fractures with dislocation; Proximal humerus fracture and shaft fracture

Introduction

Anterior glenohumeral dislocation associated with ipsilateral shaft fracture is a rare injury. The first case in modern literature was described in 1940 by Winderman. Since then, 24 new cases have been described by others (Table 1) [1].

These injuries often occur as a result of high energy trauma. The literature concerning this rare lesion is limited to "case reports", within which there are different treatments applied [2].

The purpose why we report this case it is to show the different options of treatment for an unusual injury which was treated with hemiarthroplasty with plate screws fixation of shaft.

Case History

The patient was a 63 year old male slipped in a pool and fell on his right arm. On arrival to the emergency room right arm and shoulder were sore, swollen and deformed.

Clinical examination showed right shoulder deformity to the middle third diaphyseal with no neurovascular abnormalities. Also anterior displacement of the head and a positive sulcus sign was found.

Radiographs showed a spiral fracture of the humeral shaft with lateral angulation, three parts anatomic neck fracture and anterior glenohumeral dislocation (Figures 1 and 2).

Firstly, in the operating room, under general anesthesia closed reduction of anterior dislocation using two percutaneous pinning was attempted but it was impossible to reduce it [3]. When we removed the needles, bleeding is observed by one of the inlets of the needles which refers to maintaining compression.

Weak radial pulse was palpable without uptake in the O₂ sensor so vascular injury was suspected and Hemodynamic Vascular Surgeon was informed.

Vascular surgeons confirmed a small tear at the level of the axillary artery which was sutured. This complication forced us to delay the final intervention for about five days.

Secondly, under new general anesthesia, new closed reduction was attempted without success.

Thus, using extended deltopectoral approach we were able to obtain the reduction of the humeral head, though not without difficulties.

Once the fracture is reduced, we noted the existence of a proximal humerus fracture in 3 fragments with involvement of the anatomical neck and spiral fracture of the shaft.

Due to increased risk of necrosis of the humeral head, we consider the optimal treatment was the placement of a cemented humeral hemiarthroplasty (Equinox, Exactech®) combined with a dynamic long compression plate for proximal humerus (Periloc. Smith and Nephew®) and three cerclages Dall-Miles (Figures 3 and 4).

Layered closure was performed with a suction drain which was removed in 24 hours. The radiological result is shown in Figures 5 and 6.

Discussion

In the current literature there is not any case of humeral shaft fracture combined with fracture - dislocation of the humeral head affecting the ipsilateral and anatomical neck. Since 1940 only 24 cases of fractures-dislocations of the humeral head with ipsilateral shaft fractures have been described (Table 1) [1]. Five of them described greater tuberosity fracture. One article described a proximal humerus fracture in three fragments, but without involvement of the anatomical neck, hence the uniqueness of our case. The majority of reported cases has occurred as a result of high energy trauma, unlike ours that was for a simple accidental fall after slipping on a wet floor [4,5].

In previous publications, the injuries were caused by traffic accidents involving motorcycles or cars, precipitation from two or more meters high or even workplace machinery accidents.

*Corresponding author: Tomás Pérez Cervera, Hospital Universitario Virgen Macarena, Cirugía Ortopédica y Traumatología, Sevilla 41018, Spain, Tel: +34660276344; E-mail: tperezc86@gmail.com

Received January 07, 2016; Accepted February 25, 2016; Published March 03, 2016

Citation: Cervera TP, Roca L, Montalvo MÁM (2016) Shoulder Dislocation with Head and Shaft Fracture Ipsilateral. J Arthritis 5: 194. doi:10.4172/2167-7921.1000194

Copyright: © 2016 Cervera TP, et al. This is an open-access article distributed under the terms of the Creative Commons Attribution License, which permits unrestricted use, distribution, and reproduction in any medium, provided the original author and source are credited.

Author/Dot	dapOsna		Ditdorodon	MIMI linarneo	114slotadaa Th	Press TY	Anlb
		Madbanias					
Ilmit.3)04	Me F	Pal	Animate 3 gun	Md./3	Owed	Ceoptanim SSW	Good
Inattrainel	:111	conerrer belt	Anterior. CIF	M4/3	Closed	()RIF Dynamic Coadermoon Fit	Good
howthlare206	In 31	MCC	Amain	htsa/3	Chord	Reddns & lawnersedullan Nat	(Mod
4 lsm/ litnl	IS M	MCC	Armand	Miblesill	(bird	Dynamic	Good
						Corapremion Fide and Scream	
	:OM	MCC	Antrnar	Ian Itutertb	timed	IMF Dynamic Conan-dim nor	Rota n rakey
Mafia/1996	19M	MST	Ant, ...(t. i:	Maiand/ 3 ltrandy	timed	Druids	Inv Abl
						Compredost lido	DI 13drg, Ore nrsi IR 10
Caladoor/1106	7711	MW	Ammar	Slid/3	aimed	Dynamic Comanweion liar	Ibatial n Paley. riwohrd
Daekt/ 1995	29 U	MCC	Animist	lbath/3	Closed	Stsba/Brace	CS7 *sopa. nesolord
	67 11	WIC	Minim	M/3	Owed	latnamord. Rod	lambed aid. litic wad IX
KontakiV10111	II 14	/417C	Anterior	114/3	Opts		Mr Si. aid. and ER 10
						Hale and Screwy	dee
	4131	Fa tom 201	Antedate	16113	Clad	1T-Slab (SAN)	the FR to dew
Commilld4	1611	MCC	Anardoe	Mid./3	Chord	3 tin stahaanbai .r 1 la Lethal bxlmlemw	(Dyed
Stephens. Kotty/lleol	29 31	MW	Amnion GTV	M4/3	Closed it/ limb Lenge:dab* APPRltwt to Amid	Clewed ltedurnew Edema 11A Elation	lbw Abd M dna
lb:1pm/ ttes3	2.511	Operating Maidnery 0 Tracduad	Animist. GIP	Mal Loy/ 3 hand*	Gamed	501111	Good
	C V	MW	Antsdne	limn	nomad w/ Sielawada	SWIM	Good
					pin		
Bake/1971	25 II	Oweratint Mad/ marry	Antral*. G17	Mid/3	ORO	latranedsdbry Raab	74 km. MA malmetat
		efalb				OW	
Gu1/19S7•	n/a	n/a	& ardor	Finsil	n/a	a/a	a/a
110bn/1911	a/a	n/a	n/a	n/a	st/o	n/a	a/a
Windermid/ HMO	614 F	bl	Submwaroid	Mi1/3	Owed math On	Split	Gaol M0690. Dimbred a karate
					Oo avid		
Mth/1919	'1711	Fall dome stars	Submaratold	Proa/3	Closed	SPIN	roll 11011. time rrw- Dt^Llfo;fl'Ula

*ubuietd atom Ranson 111K1/

Table 1: This table mimes the trimeted powlsosd bumf we Inctursw1okrations Mai awcanded hewn trastsrms Owls trmaarat aid antra.

We must emphasize the mechanism of injury. Case reports in the literature have advocated two possible mechanisms of injury. Sankaran-Kutty and Sadat-Ali [6] suggested that the force exerted along the axis of the humerus simultaneously fractured the humerus and dislocated the shoulder, whereas Kontakis et al. [7,8] proposed that the shoulder dislocated first and subsequent, bending or torsion forces fractured the shaft of humerus. We believe that the mechanism of injury in our patient was as described in the second case, and this is supported by the fracture pattern that is spiral and acute bending of the arm during emergency presentation.

In a prospective study developed by Court - Brown showed that 49% of proximal humerus fractures were classified as Neer Type I. 28% was classified as broken into two fragments of the surgical neck and only 9% as fractures into three fragments with greater tuberosity and fitness for repair broken neck. Our patient was classified as a fracture in three fragments with the peculiarity of the anatomical neck fracture.

The humeral head receives vascular supply through the anterior circumflex artery and to a lesser extent is also nourished by vessels entering through the posteromedial region of the proximal humerus, and metaphyseal vessels of the tuberosity. Doppler confirmed that if the humeral head fragments include at least 8 mm medial calcar, avascular necrosis risk drops significantly due to the blood pool present there. It also determined that avascular necrosis was ahead in 97% of cases if they had an anatomical neck fracture, small medial calcar and periosteal disruption of the medial line.

Our patient had a fracture of the anatomical neck, so he had a high risk of avascular necrosis to which must be added the time elapsed since the injury until surgery.

Fractures in three fragments of the proximal humerus with dislocations associated with ipsilateral humeral shaft fractures are rare. The closed each of these lesions is suitably reduced, if it is possible

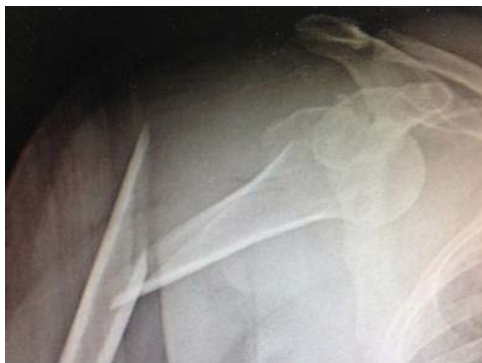

Figure 1: Rx shows fracture – dislocation with ipsilateral shaft fracture.

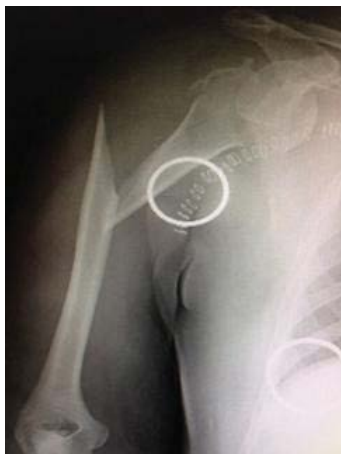

Figure 2: Rx shows fracture in three parts with anatomical neck fracture.

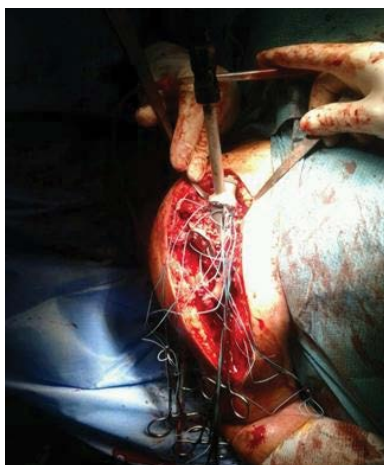


Figure 3: DLCP and hemiarthroplasty during their collocation.

to do in emergencies, which will preserve blood flow to the fracture fragments.

The second important aspect of our case is its management. Literature reflects that hemiarthroplasty may be a viable option for complex fractures of the proximal humerus with even better results

than open reduction and fixation [9]. The treatment modalities include closed reduction and plaster of paris slab application, nailing and plating of the humeral shaft along with reduction of the shoulder dislocation. Good clinical results have been reported with almost all the modalities. However, there is no consensus in the literature for treating this type of injury [10-12]. In fact, we did a combination of several options to

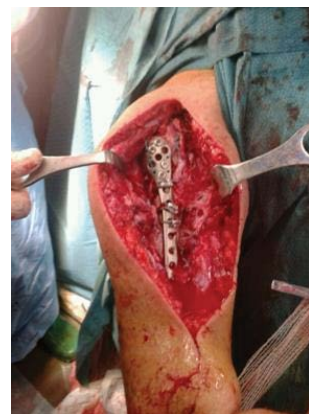

Figure 4: DLCP with hemiarthroplasty and cerclages.

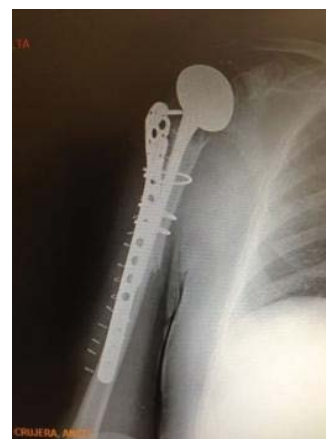

Figure 5: Postsurgery Rx.

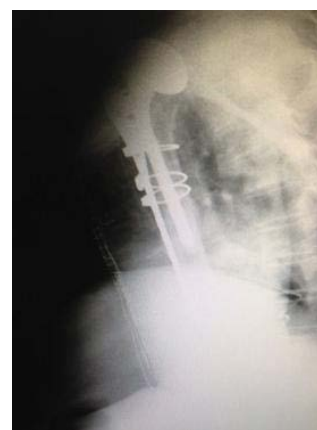

Figure 6: Radiological result.

overcome the difficulties we were facing for the internal fixation of the fracture and for the viability of the humeral head.

The last aspect of this case is its outcome. Almost all reported cases have reported satisfactory outcome (some degree of restriction of abduction and flexion) despite different modalities of management. We also had a good outcome in our patient despite having a more severe injury.

References

1. Karimi-Nasab MH, Shayesteh-Azar M, Sajjadi-Saravi M, Daneshpoor SMM (2012) Anterior shoulder dislocation and ipsilateral humeral shaft fracture. *Iran J Med Sci* 37: 202-204.
2. Kazakos K, Paraschou S, Lasanianos N, Verettas D, Lyras D (2009) A humeral shaft fracture complicated with anterior shoulder dislocation in a young male treated with modified Intramedullary nailing prior to reduction: a case report. *Cases Journal* 2: 9075.
3. Flint JH, Carlyle LM, Christiansen CC, Nepola JV (2009) Case report and literature review anterior shoulder dislocation with three-part proximal humerus fracture and humeral shaft fracture. *Iowa Orthop J* 29: 105-113.
4. Inan U, Cevik AA, Omeroğlu H (2008) Open humerus shaft fracture with ipsilateral anterior shoulder fracture-dislocation and posterior elbow dislocation: a case report. *J Trauma* 64: 1383-1386.
5. Calderone RR, Ghobadi F, McInerney V (1995) Treatment of shoulder dislocation with ipsilateral humeral shaft fracture. *Am J Orthop (Belle Mead NJ)* 24: 173-176.
6. Sankaran-Kutty M, Sadat-Ali M (1989) Dislocation of the shoulder with ipsilateral humeral shaft fracture. *Arch Orthop Trauma Surg* 108: 60-62.
7. Kontakis GM, Galanakis IA, Steriopoulos KA (1995) Dislocation of the shoulder and ipsilateral fracture of the humeral shaft: case reports and literature review. *J Trauma* 39: 990-992.
8. Gupta Y, Jha RK (2015) Compound fracture of humeral shaft associated with two-part fracture dislocation of ipsilateral shoulder: a rare combination. *J Surg Case Rep* 2015.
9. Sasashige Y, Kurata T, Masuda Y, Shimono K, Nagata Y (2006) Dislocation of the shoulder joint with ipsilateral humeral shaft fracture: two case reports. *Arch Orthop Trauma Surg* 126: 562-567.
10. Behera P, Kumar V, Aggarwal S (2014) Humeral shaft fracture with ipsilateral shoulder dislocation. *Chin J Traumatol* 17: 57-59.
11. Micic ID, Mitkovic MB, Mladenovic DS (2005) Unreduced chronic dislocation of the humeral head with ipsilateral humeral shaft fracture: a case report. *J Orthop Trauma* 19: 578-581.
12. Farooque K, Khatri K, Dev C, Sharma V, Gupta B (2014) Mechanism of injury and management in traumatic anterior shoulder dislocation with concomitant humeral shaft and ipsilateral scapula fracture: a case report and review of the literature. *Journal of Medical Case Reports* 8: 431.