

## Retroperitoneal Sarcoma - A Diagnostic Challenge with Only a Surgical Cure

Healy P\*, Soric I and McNamara D

Department of General Surgery, Beaumont Hospital and The Royal College of Surgeons in Ireland, Ireland

### Abstract

Sarcomas are solid tumours of mesenchymal cell origin and account for 1% of all adult malignancies. Retroperitoneal sarcomas more commonly affect people in their 50's who can present to a general surgeon for assessment of non-specific abdominal symptoms. This nature of their presentation and anatomical location provides a diagnostic challenge and initial investigations may be normal. Patients can therefore present late when the tumour is locally advanced.

Complete surgical resection with negative macroscopic margins is the treatment of choice and the only proven modality to improve survival and reduce disease recurrence. Extensive resection of multiple organs may be necessary to offer any chance of cure. The benefits of other treatments such as radiotherapy and chemotherapy are less certain.

We will present the case of a 63-year-old man who presented with a chronic history of non-specific abdominal symptoms and outline the results of his investigations and subsequent management. We will briefly discuss some of the issue relating to the diagnosis and management of retroperitoneal sarcomas in general.

**Keywords:** Macroscopic; Retroperitoneal; Sarcomas; Chemotherapy; Mesenchymal

### Case Presentation

A 63-year-old Caucasian man presented to a rapid access medical clinic with a 4-month history of fatigue, anorexia, drenching night sweats and a 14 kg unintentional weight loss. He had been previously well, was a non-smoker and did not take any regular medications. On examination there was obvious abdominal distension with a firm palpable mass in the left iliac fossa. There was clinical evidence of anaemia but no evidence of jaundice, ascites, obstruction or lymphadenopathy. His testicular examination was normal.

### Investigations

Initial investigations identified an iron deficiency anaemia (Hb 9.1 g/dL), a normal white cell count and a platelet count and a C Reactive protein level of 147 mg/L. Renal and liver function tests and viral serology for CMV, toxoplasma, EBV, Hepatitis A, B, C were also normal.

A chest radiograph and upper and lower gastrointestinal endoscopies were also reported as normal. A CT scan (Figure 1) revealed a large retroperitoneal mass measuring 16.5 cm × 10.9 cm ×

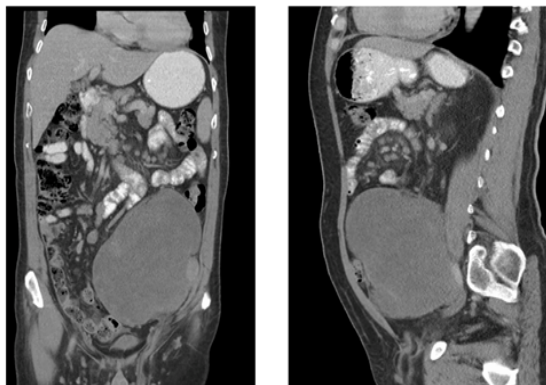


Figure 1: Coronal and sagittal views of preoperative CT Scan.

19.5 cm. It was closely related to the psoas muscle and it displaced the left colon anteriorly. It was associated with multiple mesenteric lymph nodes. The other intra-abdominal organs appeared normal.

### Management

The patient opted to proceed straight to surgery and a midline laparotomy revealed a massive and highly vascular retroperitoneal mass. It stretched and displaced the left colon and sigmoid colon over the anterior surface of the mass (Figure 2). The mass was delivered intact with macroscopically clear margins and weighed 3.7 kg (Figure 3).

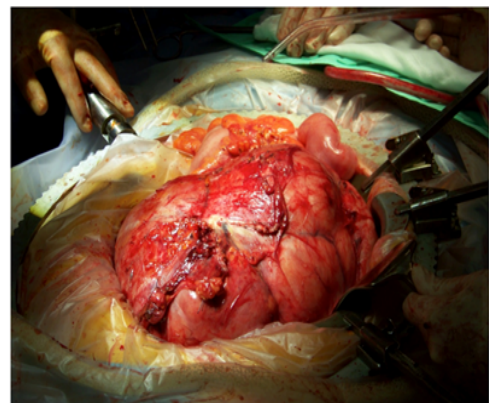


Figure 2: View at laparotomy of In situ tumor.

\*Corresponding author: Healy P, Department of General Surgery, Beaumont Hospital and The Royal College of Surgeons in Ireland, Beaumont, Dublin 9, Ireland, Tel: 0035318093000; E-mail: [paulpatrickhealy@rcsi.ie](mailto:paulpatrickhealy@rcsi.ie)

Received March 30, 2016; Accepted September 22, 2016; Published September 30, 2016

Citation: Healy P, Soric I, McNamara D (2016) Retroperitoneal Sarcoma - A Diagnostic Challenge with Only a Surgical Cure. Med Rep Case Stud 1: 121. doi: 10.4172/2572-5130.1000121

Copyright: © 2016 Healy P, et al. This is an open-access article distributed under the terms of the Creative Commons Attribution License, which permits unrestricted use, distribution, and reproduction in any medium, provided the original author and source are credited.

Final histological analysis identified a Grade 2 leiomyosarcoma. His post-operative recovery was unremarkable and he was discharged 6 days later. A CT scan at 1 year identified multiple new and enlarged intra-abdominal lymph nodes. Unfortunately a diagnostic biopsy revealed a diagnosis of a high grade B cell follicular lymphoma. The patient is currently receiving chemotherapy for this diagnosis. There is no significant family history of a cancer diagnosis and to date there has been no possible genetic link between the 2 diagnosis identified (Figure 4).

## Discussion

Sarcomas are solid tumours of mesenchymal cell origin and account for 1% of all adult malignancies and can affect the extremities (50%), trunk (10-15%), head and neck (10%) and retro-peritoneum (15%) [1]. They more commonly affect people in their 50's and affect men and women equally [2].

When they occur in the retro peritoneum, symptoms can be non-specific and include abdominal pain, abdominal distension, weight loss, anaemia, early satiety and lower limb oedema and occur due to the mass effect of the tumour [3]. The retroperitoneal space is a large space and retroperitoneal sarcomas can therefore grow to a considerable size before symptoms manifest. The median size at time of presentation has been reported to be 15 cm [3].

## Diagnosis

A high resolution, thin cut CT of the thorax, abdomen and pelvis with IV and oral contrast is the preferred imaging modality as it can

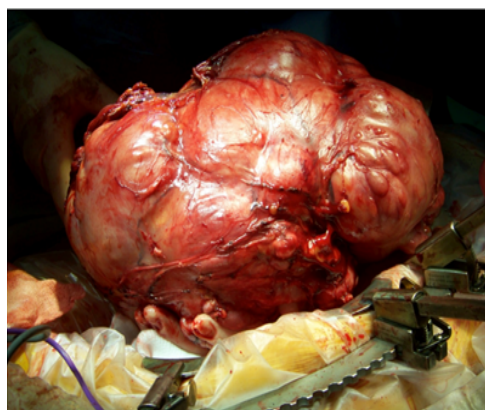


Figure 3: Tumour excised from abdomen.

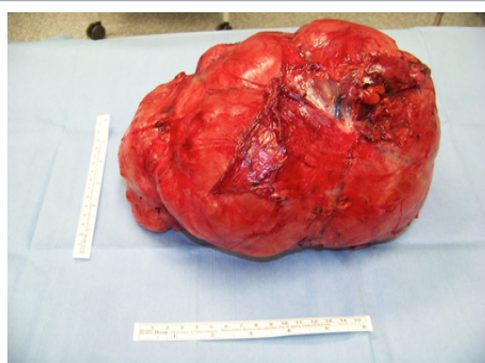


Figure 4: Tumour excised from abdomen.

assess the primary tumour including its involvement with other organs and assess any metastatic disease [4]. Recent guidelines from the Trans Atlantic RPS Working Group [5] have strongly recommended that multiple core needle biopsies be obtained unless the imaging is highly suggestive of a diagnosis of a liposarcoma, which has a characteristic radiological appearance. Previously, concern has been expressed that performing a biopsy of a suspected retroperitoneal sarcoma could result in seeding of the tumour [6]. However more recent evidence claims that seeding is rare and should not be a reason for avoiding a pre operative biopsy [5].

## Staging

Retroperitoneal sarcomas are staged using the American Joint Committee on Cancer (AJCC) TNM system [6] and are assigned a histological grade using the French Federation of Cancer Centres Sarcoma Group grading system. This is based on the degree of tumour differentiation, mitotic count and presence of tumour necrosis. However while these systems are used to stage retroperitoneal sarcomas their main role has been in the staging of extremity soft tissue sarcomas. The Dutch/ Memorial Sloan –Kettering cancer center classification system has been proposed as an alternative staging system for retroperitoneal sarcoma and takes histological grade, resection status and the presence of any metastases into account [7]. More recent advances have included the development of disease specific nomograms by combining datasets from multiple institutions. These have been proposed as a means to predict disease free survival as well as overall survival in patients diagnosed with retroperitoneal sarcoma [8].

The most common subtypes are liposarcoma, leiomyosarcoma and malignant fibrous histiocytoma. However advances in immunohistochemistry assays have shown that malignant fibrous histiocytoma are a form of dedifferentiated liposarcoma and the term is no longer included in the WHO classification of sarcomas [1].

## Treatment

Complete surgical resection with macroscopically negative margins is the only treatment to have proven benefit to reduce the risk of disease recurrence and improve survival [2]. In a series of 500 people, complete resection of retroperitoneal sarcoma resulted in a median survival of 103 months compared to 18 months with incomplete resection [9]. They can be locally invasive resulting in up to 75% of resections involving resection of other abdominal organ(s). Their complexity and possible multi organ involvement usually necessitates the involvement of a multidisciplinary team of surgeons and ideally a specialist with experience in managing retroperitoneal sarcomas [5].

Radiotherapy has been proposed to improve resection margins but conclusive evidence supporting its use in a neoadjuvant setting is lacking. However there is an on-going multicentre phase III randomised control trial being conducted by the European Organisation for Research and Treatment of Cancer (EORTC) to examine the role of neoadjuvant radiotherapy in the treatment of retroperitoneal sarcoma. It is randomising patients to either neoadjuvant radiotherapy followed by surgery or to surgery alone to assess the potential difference in recurrence free survival between both groups [5].

There are no randomised controlled trials examining the role of adjuvant radiotherapy and its benefits may be offset by the radiation effects on the bowel and other organs [3]. The majority of retroperitoneal sarcomas are chemotherapy insensitive and overall there is no significant role for the use of chemotherapy in the management of most retroperitoneal sarcomas [6]. Due to the rarity

of retroperitoneal sarcomas much of the data on radiotherapy and chemotherapy has been extrapolated from its use in managing sarcoma of the extremities [4]. However international collaboration between specialist centers, such as that seen with the current EORTC trial, may lead to more defined role for treatments such as chemotherapy and radiotherapy in the management of retroperitoneal sarcoma.

### Prognosis

Disease recurrence is reported to occur in 50-80% of patients and poor prognostic indicators include positive margins, un-resectable disease and a diagnosis of a high-grade sarcoma [2]. The National Comprehensive Cancer Network propose that patients should undergo surveillance after treatment with physical examination and a CT thorax, abdomen and pelvis every 3 to 6 months for 2 to 3 years, every 6 months for 2 years and then annually [10]. More recent recommendations from the Trans Atlantic RPS working Group concur with regular follow up initially and yearly after 5 years [5]. Prediction of disease free survival and overall survival appears to be possible with the development of disease specific nomograms from multiply institution datasets.

Disease free survival and overall survival appears to be possible with the development of disease specific nomograms from multiply institution datasets.

### Learning Points

- Patients can present with non-specific abdominal symptoms related to the mass effect of the tumour.
- The retroperitoneal space is large and tumours can be a significant size before symptoms manifest.
- Surgical resection with negative macroscopic margins is the only proven treatment to prevent recurrence and increase disease free survival.

Radiotherapy and chemotherapy have a limited role in the management of retroperitoneal sarcoma but the on-going EORTC trial may clarify the role of neo-adjuvant radiotherapy in the management of retroperitoneal sarcomas.

### References

1. Liles JS, Tzeng CW, Short JJ, Kulesza P, Heslin MJ (2009) Retroperitoneal and intra abdominal sarcoma. *Curr Probl Surg* 46: 445-503.
2. Kumar V, Sanjeev M, Chaturvedi A (2012) Retroperitoneal sarcomas - a challenging problem. *Indian J Surg Oncol* 3: 215-221.
3. Mullen JT, DeLaney TF (2013) Clinical features, evaluation, and treatment of retroperitoneal soft tissue sarcoma.
4. Mullinax JE, Zager JS, Gonzalez RJ (2011) Current diagnosis and management of retroperitoneal sarcoma. *Cancer Control* 18: 177-187.
5. Trans-Atlantic RPS Working Group (2015) Management of Primary Retroperitoneal Sarcoma (RPS) in the Adult: A Consensus Approach from the Trans-Atlantic RPS working Group. *Ann Surg Oncol* 22: 256-263.
6. Grimer R, Judson I, Peake D, Seddon B (2010) Guidelines for the management of soft tissue sarcomas. *Sarcoma* 2010: 506182.
7. Van Dalen T, Hennipman A, Van Coevorden F, Hoekstra HJ, Van Geel BN, et al. (2004) Evaluation of a clinically applicable post-surgical classification system for primary retroperitoneal soft-tissue sarcoma. *Ann Surg Oncol* 11: 483.
8. Gronchi A, Miceli R, Shurell E, Eilber FC, Eilber FR, et al. (2013) Outcome prediction in primary resected retroperitoneal soft tissue sarcoma: histology-specific overall survival and disease-free survival nomograms built on major sarcoma center data sets. *J Clin Oncol* 31: 1649-1655.
9. Lewis JJ, Leung D, Woodruff JM, Brennan MF (1998) Retroperitoneal soft-tissue sarcoma – analysis of 500 patients treated and followed at a single institution. *Ann Surg* 228: 355-365.
10. National Comprehensive Cancer Network (NCCN) (2012) NCCN Clinical Practice Guidelines in Oncology. Soft Tissue Sarcoma. National Comprehensive Cancer Network.