

# Management of 2 to 3 cm<sup>2</sup> Osteochondral Defects of the Knee with Subchondral Drilling in Patients Less than 50 Years of Age

Tarek Aly\* and Waleed Ewais

Department of Orthopedic Surgery, Tanta University School of Medicine, Egypt

## Abstract

**Aim:** Articular cartilage defects in the knee do not heal and may dispose a predisposition for an early onset of osteoarthritis. Large osteochondral defects are associated with mechanical instability and are accepted indications for surgical intervention to prevent development of degenerative joint disease.

**Purpose:** The purpose of this study to evaluate the effect of drilling on treatment of knee osteochondral defects among 2-3 cm<sup>2</sup>.

**Methods:** Twenty six patients (18 men and 8 women) with focal full-thickness cartilage lesions of the knee on the medial or lateral femoral condyle, or trochlea were included in this study. The surgical technique is through arthroscopic subchondral drilling. Lysholm score was used for evaluation of outcome. Clinical evaluation and scoring were done preoperatively and at follow-up.

**Results:** Lysholm score was 43.0 ± 12 preoperatively, improved to 88.0 ± 9 postoperatively. Radiologically, complete healing of the defect was observed in all cases except 2.

**Conclusion:** Subchondral drilling can be an effective approach for the treatment of osteochondral defects sized 2-3 cm<sup>2</sup>. Using this method, most of the patients with failed non-operative treatment successfully can postpone the joint arthroplasty after a single joint preserving surgical procedure.

**Keywords:** Chondral; Defect; Arthroscopy; Drilling; Knee

## Introduction

Articular cartilage defects in the knee do not heal and may dispose a predisposition for an early onset of osteoarthritis [1]. Large osteochondral defects are associated with mechanical instability and are accepted indications for surgical intervention to prevent development of degenerative joint disease [2]. The treatment of cartilage defects represents a common, complex and multifaceted task for orthopaedic surgeons; particularly, in young patients suffering from large cartilage defects, there are only limited conservative and surgical treatment options. Thus, several efforts to restore articular cartilage were undertaken. Ideally, a large osteochondral defect should be repaired with a graft that can provide mechanical stability and allow early postoperative function under physiologic loading condition [3]. Disagreement exists for treatment of lesions over 2-3 cm<sup>2</sup>, while both Osteochondral Cylinder Transplantation (OCT, OATS) or the different modalities of Autologous Chondrocyte Transplantation (ACT) as well as Matrix-Assisted Chondrocyte Transplantation (MACT) techniques are being applied. Furthermore, novel techniques, such as autologous matrix induced chondrogenesis or one-step procedures [4] do or will stand by for execution in the desired patient, while arthroscopic techniques [5] are described with increasing frequency. Cartilage repair is applied with a constantly increasing frequency, while there is both, no internationally accepted algorithm for treatment of cartilage defects or survey to describe how experienced surgeons handle cartilage lesions [6]. No internationally accepted algorithm for treatment of cartilage defects or survey to describe how experienced surgeons handle cartilage lesions. Also, the increased complication rate of autologous or artificial bone graft in management of osteochondral defects of the knee beside lack of experience and also for economic reasons in many places all over the world it was our hypothesis of this study to show that the over drilling is effective, safe method of treatment for knee osteochondral defects among 2-3 cm<sup>2</sup>.

## Methods

Twenty six patients (18 men and 8 women) with focal full-thickness cartilage lesions of the knee on the medial or lateral femoral condyle, or trochlea were included in this study through the period from 2006-2010. Age of the patients ranged from 23 years to 49 years (mean 36.7 years). All patients were complaining of symptom-like pain or dysfunction of the knee joint. Patients with at least one of the following criteria were excluded from this study: severe osteoarthritis; small lesions <2 cm<sup>2</sup>, age over 50 years, presence of active infection; and limb malalignment and presence of radicular pain. Eighteen patients had previous operations Patients included meniscectomies (in 6 patients) and reconstructions of the anterior cruciate ligament (in 12 patients). Presence and grade of meniscal and cartilage lesions as well as Bone Marrow Edema Pattern (BMPE) were assessed using a modified whole organ MRI score (WORMS) [7]. There were 12 patient's grade 5 and the rest were grade 6.

Lysholm and Gillquist [8] score was used for evaluation of outcome. Clinical evaluation and scoring were done preoperatively and at follow-up. The surgical technique is through subchondral drilling. This technique enhances chondral resurfacing by providing a

\*Corresponding author: Tarek Aly, Department of Orthopedic Surgery, 48<sup>th</sup>, Sarwat street, Tanta 31111, Egypt, Tel: 2040 3317928; E-mail: [elphara3on@hotmail.com](mailto:elphara3on@hotmail.com)

Received February 07, 2014; Accepted February 22, 2014; Published February 24, 2014

**Citation:** Aly T, Ewais W (2014) Management of 2 to 3 cm<sup>2</sup> Osteochondral Defects of the Knee with Subchondral Drilling in Patients Less than 50 Years of Age. J Arthritis 3: 121. doi:[10.4172/2167-7921.1000121](https://doi.org/10.4172/2167-7921.1000121)

**Copyright:** © 2014 Aly T, et al. This is an open-access article distributed under the terms of the Creative Commons Attribution License, which permits unrestricted use, distribution, and reproduction in any medium, provided the original author and source are credited.

suitable environment for tissue regeneration and by taking advantage of the body's own healing potential. Multiple perforations into the subchondral bone plate were done. The perforations are made as close together as necessary, but not so close that one breaks into another. Consequently, the drilling holes are approximately three to four millimeters apart (or 3 to 4 holes per square centimeter). Importantly, the integrity of the subchondral bone plate is maintained. The released marrow elements form a "super clot" which provides an enriched environment for tissue regeneration. Postoperatively, CPM was used for all patients from the 2nd day of operation and patients were allowed for partial weight bearing for 6 weeks.

### Statistical Analyses

Analyses were performed using Sigma Plot 10.0 and Sigma Stat (SPSS). The level of significance was defined at  $P=0.05$ .

### Results

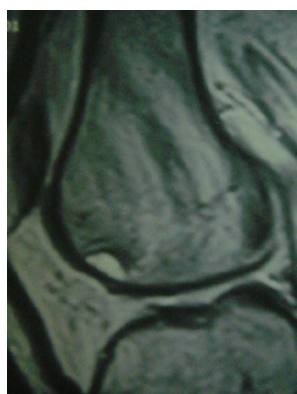
The patients had complained of pain for 3-15 months preoperatively. Nineteen of them reported rest pain. Clinical evaluation of the patients revealed Mild knee effusion in 19 patients and moderate in 7, tenderness over the affected area was noted in all patients. Limitation of range of motion of the affected knee was observed in all cases (average flexion: 93.4°, Average extension: -9°).

The mean follow up was 38 months (range 25-54 months). In 17 patients, the lesion sized 2 cm<sup>2</sup>, between 2-3 cm<sup>2</sup> in 3 patients and it was 3 cm<sup>2</sup> in the rest of the patients. Postoperatively, pain disappeared in 23 patients and was mild in 3 patients. Knee effusion disappeared in all patients. Average range of motion improved to 140° flexion and -0.5° extensions respectively. Lysholm score was  $43.0 \pm 12$  preoperatively, improved to  $88.0 \pm 9$  postoperatively ( $P<0.0001$ ). Only 2 patients were complaining of slight impairment of climbing stairs and one patient was complaining of difficulty in squatting.

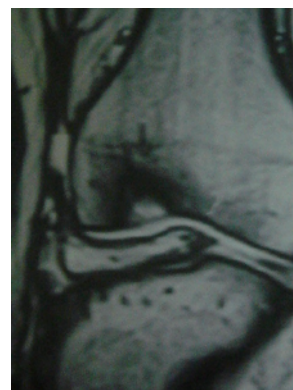
Radiologically using MRI, complete healing of the defect was observed in all cases (Figures 1-6) except 2 (Both were WOMOS's grade 6). No progression of the lesion or development of osteoarthritis was noted till the end of follow-up period.

### Discussion

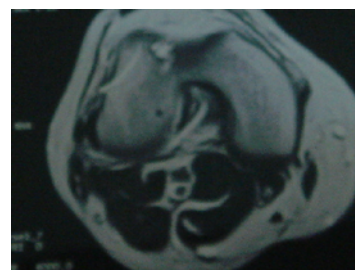
Treatments for managing articular cartilage defects of the knee are not always effective. When they are, long-term benefits may not be maintained and osteoarthritis may develop. Marrow stimulation



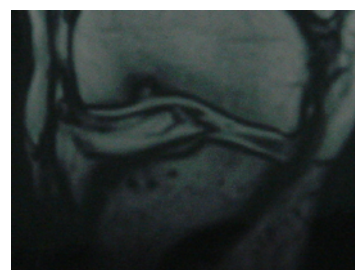
**Figure 1:** Sagittal MRI for 42 years old male with 4 years history of right knee pain showing osteochondral defect about 3 cm<sup>2</sup> of medial femoral condyle.



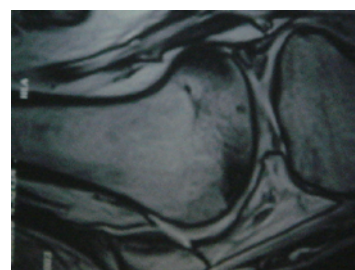
**Figure 2:** Coronal MRI for the same patient showing affection of the articular surface.



**Figure 3:** Transverse cut of the same patient showing the extent of the defect.

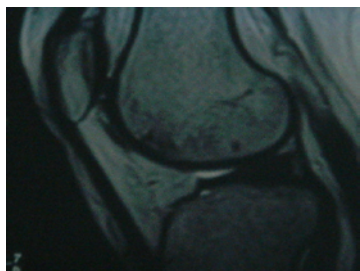


**Figure 4:** Coronal MRI of the same patient one year after surgery showing partial healing of the defect.



**Figure 5:** Sagittal MRI of the same patient 2 years after surgery showing complete healing of the defect.

techniques such as drilling or micro fracture are first-line treatment options for symptomatic cartilage defects. Common knowledge holds that these treatments do not compromise subsequent cartilage repair procedures with autologous chondrocyte implantation [9].



**Figure 6:** Sagittal MRI of the same patient showing complete healing of the defect 3 years after surgery.

Autologous osteochondral mosaicplasty may be an alternative for small and medium-sized focal chondral and osteochondral defects of weight bearing surfaces of the knee and other weight bearing synovial joints [10]. There is at present no evidence of significant difference between articular cartilage implantation and other interventions [11]. Autologous osteochondral transplant systems have shown encouraging results but there are still problems. Graft matching and contouring to the recipient articular surface is difficult. Donor sites can be a limiting factor. Furthermore, the fibro cartilaginous interface between the donor and recipient site may contribute to breakdown in the long run. Also, the technique is expensive and is technically difficult to perform [12]. Long-term functional outcome is still a significant question mark. In addition, it has not been shown that autologous chondrocyte implantation can prevent degenerative changes. It was previously mentioned that marrow-stimulation techniques such as drilling, micro fracture, or abrasion arthroplasty fail to yield long-term solutions because they typically promote the development of fibrocartilage. Fibrocartilage lacks the durability and many of the mechanical properties of the hyaline cartilage that normally covers articular surfaces [13]. Experimentally, it was proven that subchondral drilling had increased fibro cartilaginous healing with time, with a slight increase in degenerative changes. Drilling may result in a longer-lived repair than abrasion arthroplasty in the treatment of full-thickness lesions [14]. Recent systematic review comparing Micro fracture technique with chondrocyte implantation (ACI) and osteochondral autograft transfer demonstrated no clear superiority of ACI over micro fracture in line with the findings published by other authors [15-17]. Micro fracture technique can be done arthroscopically with faster recovery after surgery and with better cosmesis results. Autologous Chondrocyte Implantation (ACI) involves an open technique with inherent disadvantages such as adhesions and prolonged recovery [18] the size and localization of the defect can be assessed by MRI. It also helps in detection of any other intra-articular lesions [19]. Drilling via intra-articular approach has been performed in the past with poor results [20]. This may be due to open surgery techniques with its associated complications. Patients of this study showed highly significant increases in the respective scores used for outcome measurement demonstrating major improvements in activities of daily living and ability to work. None of our patients complained of knee pain after surgery. Mobilization of the affected knee could be started immediately. Our present results are in line with the available literature. Forst et al. [21] reported on the results of core decompression with resolution of pain in 94% of patients when followed for a mean of 35.4 months. Mont et al. found good or excellent results in 73% of patients at mean follow-ups of 11 years [22]. Marulanda et al. [23] avoided progression to TKA in 97% of patients at a mean follow-up of 3 years treated with percutaneous drilling. Bouwmeester et al. [24] concluded that at 10

years follow-up no difference was observed between debridement and drilling and perichondrium transplantation for treatment of an isolated cartilage defect. Imade et al. [25] also had the same conclusion where they stated that no differences in clinical scores were found in patients with a concomitant ACL rupture and an osteochondral lesion treated by drilling or autologous osteochondral grafting at a minimum follow-up of 1 year, regardless of the differences at arthroscopic grading [25]. Size of the lesion in the cartilage is also important in deciding the method of management. Profeen et al. [26] in their review of the regenerative treatment options in management of cartilage lesions stated that although evidence-based studies comparing microfracture and ACI have not found significant differences in the clinical outcome, the literature does show that choosing the treatment based on the size and characteristics of the osteochondral lesion might be beneficial. The American Association of Orthopedic Surgeons suggests that contained lesions <4 cm<sup>2</sup> should be treated by microfracture, lesions bigger than that by autologous chondrocyte implantation [26]. In comparing our techniques with other techniques: Attmanspacher et al. [27] studied the outcomes in 18 patients after arthroscopically placed osteochondral autograft transfers for a variety of underlying disorders including osteonecrosis, osteochondrosis dissecans, and osteochondral defects secondary to instability in anterior cruciate ligament-deWient knees. Short-term outcomes were very good with an average Lysholm score of 90 points (range 78–92 points), suggesting that this procedure is an effective treatment for focal chondral and osteochondral defects [27]. Despite the overall good results in this study, the small number of patients is still a limitation. Larger number with longer follow up period is needed to prove the long term efficacy of this technique.

## Conclusion

Subchondral drilling can be an effective approach for the treatment of osteochondral defects sized 2-3 cm<sup>2</sup>. Using this method, most patients who failed non-operative treatment successfully avoided the need for joint arthroplasty after a single joint preserving surgical procedure.

## References

1. Buckwalter JA (2002) Articular cartilage injuries. *Clin Orthop Relat Res* : 21-37.
2. Abouheif M, Nakamura M, Deie D, Adachi N, Nishimori M, et al. (2010) Repair of a large osteochondral defect in the knee joint using autologous and artificial bone graft combined with motion preserving distraction arthroplasty: a case report. *Arch Orthop Trauma Surg* 130: 231-236.
3. O'Driscoll SW, Salter RB (1986) The repair of major osteochondral defects in joints surfaces by neochondrogenesis with autogenous osteoperiosteal grafts stimulated by continuous passive motion: an experimental investigation in the rabbit. *Clin Orthop Relat Res* 208: 131-140.
4. McCormick F, Yanke A, Provencher MT, Cole BJ (2008) Minced articular cartilage—basic science, surgical technique, and clinical application. *Sports Med Arthrosc* 16: 217-220.
5. Ferruzzi A, Buda R, Faldini C, Vannini F, Di Caprio F, et al. (2008) Autologous chondrocyte implantation in the knee joint: open compared with arthroscopic technique. Comparison at a minimum follow-up of five years. *J Bone Joint Surg Am* 90 Suppl 4: 90-101.
6. Jakobsen RB, Engebretsen L, Slauterbeck JR (2005) An analysis of the quality of cartilage repair studies. *J Bone Joint Surg Am* 87: 2232-2239.
7. Baum T, Joseph GB, Arulanandan A, Nardo L, Virayavanich W, et al. (2012) Association of magnetic resonance imaging-based knee cartilage T2 measurements and focal knee lesions with knee pain: data from the Osteoarthritis Initiative. *Arthritis Care Res (Hoboken)* 64: 248-255.
8. Lysholm J, Gillquist J (1982) Evaluation of knee ligament surgery results with special emphasis on use of a scoring scale. *Am J Sports Med* 10: 150-154.

9. Minas T, Gomoll AH, Rosenberger R, Royce RO, Bryant T (2009) Increased failure rate of autologous chondrocyte implantation after previous treatment with marrow stimulation techniques. *Am J Sports Med* 37: 902-908.
10. Hangody L, Vászárhelyi G, Hangody LR, Sükösd Z, Tibay G, et al. (2008) Autologous osteochondral grafting—technique and long-term results. *Injury* 39 Suppl 1: S32-39.
11. Wasiak J, Clar C, Villanueva E (2010) Autologous cartilage implantation for full thickness articular cartilage defects of the knee. *Cochrane Database Syst Rev* 10: CD003323.
12. Gilbert JE (1998) Current treatment options for the restoration of articular cartilage. *Am J Knee Surg* 11: 42-46.
13. Minas T, Nehrer S (1997) Current concepts in the treatment of articular cartilage defects. *Orthopedics* 20: 525-538.
14. Menche DS, Frenkel SR, Blair B, Watnik NF, Toolan BC, et al. (1996) A comparison of abrasion burr arthroplasty and subchondral drilling in the treatment of full-thickness cartilage lesions in the rabbit. *Arthroscopy* 12: 280-286.
15. Marcacci M, Berruto M, Brocchetta D, Delcogliano A, Ghinelli D, et al. (2005) Articular cartilage engineering with Hyalograft C: 3-year clinical results. *Clin Orthop Relat Res*: 96-105.
16. Knutsen G, Drogset JO, Engebretsen L, Grøntvedt T, Isaksen V, et al. (2007) A randomized trial comparing autologous chondrocyte implantation with microfracture. Findings at five years. *J Bone Joint Surg Am* 89: 2105-2112.
17. Knutsen G, Engebretsen L, Ludvigsen TC, Drogset JO, Grøntvedt T, et al. (2004) Autologous chondrocyte implantation compared with microfracture in the knee. A randomized trial. *J Bone Joint Surg Am* 86-86A: 455-464.
18. Erggelet C, Kreuz PC, Mrosek EH, Schagemann JC, Lahm A, et al. (2010) Autologous chondrocyte implantation versus ACI using 3D-bioresorbable graft for the treatment of large full-thickness cartilage lesions of the knee. *Arch Orthop Trauma Surg* 130: 957-964.
19. Glückert K, Kladny B, Blank-Schäl A, Hofmann G (1992) MRI of the knee joint with a 3-D gradient echo sequence. Equivalent to diagnostic arthroscopy? *Arch Orthop Trauma Surg* 112: 5-14.
20. Lotke PA, Ecker ML (1985) Osteonecrosis of the knee. *Orthop Clin North Am* 16: 797-808.
21. Forst J, Forst R, Heller KD, Adam G (1998) Spontaneous osteonecrosis of the femoral condyle: causal treatment by early core decompression. *Arch Orthop Trauma Surg* 117: 18-22.
22. Mont MA, Baumgarten KM, Rifai A, Bluemke DA, Jones LC, et al. (2000) Atraumatic osteonecrosis of the knee. *J Bone Joint Surg Am* 82: 1279-1290.
23. Marulanda G, Seyler TM, Sheikh NH, Mont MA (2006) Percutaneous drilling for the treatment of secondary osteonecrosis of the knee. *J Bone Joint Surg Br* 88: 740-746.
24. Bouwmeester PS, Kuijer R, Homminga GN, Bulstra SK, Geesink RG (2002) A retrospective analysis of two independent prospective cartilage repair studies: autogenous perichondrial grafting versus subchondral drilling 10 years post-surgery. *J Orthop Res* 20: 267-273.
25. Imade S, Kumahashi N, Kuwata S, Kadowaki M, Tanaka T, et al. (2013) A comparison of patient-reported outcomes and arthroscopic findings between drilling and autologous osteochondral grafting for the treatment of articular cartilage defects combined with anterior cruciate ligament injury. *Knee* 20: 354-359.
26. Proffen B, von Keudell A, Vavken P (2012) Evidence-based therapy for cartilage lesions in the knee - regenerative treatment options. *Z Orthop Unfall* 150: 280-289.
27. Attmanspacher W, Dittrich V, Stedtfeld HW (2000) Experiences with arthroscopic therapy of chondral and osteochondral defects of the knee joint with OATS (Osteochondral Autograft Transfer System). *Zentralbl Chir* 125: 494-499.