

## Intravenous Immunoglobulin for Relapsing-Remitting Multiple Sclerosis Treatment: A Case Report and Literature Review

Kunfang Yang, Rongrong Yin, Hongyi Cheng, Yuanfeng Zhang, Simei Wang, Chunmei Wang, Yanfen Lu, Jiaming Xi, Qin Lu, Jianjun Huang and Yucai Chen\*

Department of Neurology, Shanghai Children's Hospital, Shanghai Jiao Tong University, Shanghai 200062, China

\*Corresponding author: Yucai C, Department of Neurology, Shanghai Children's Hospital, Shanghai Jiao Tong University, Shanghai 200062, China, E-mail: [chenyc@shchildren.com.cn](mailto:chenyc@shchildren.com.cn)

Received date: February 06, 2017; Accepted date: February 21, 2017; Published date: February 28, 2017

Copyright: © 2017 Yang K, et al. This is an open-access article distributed under the terms of the Creative Commons Attribution License, which permits unrestricted use, distribution, and reproduction in any medium, provided the original author and source are credited.

### Abstract

**Background/aim:** Multiple sclerosis (MS) is a chronic and debilitating inflammatory autoimmune disease of the central nervous system (CNS) that affects the myelinated axons in the CNS. Incomplete remissions occur more commonly with increasing duration of disease. Intravenous immunoglobulin (IVIg) has various functions as an immune modulator via macrophage activation. Clinical trials of immunoglobulin demonstrated remarkable clinical effects in several types of MS, especially in relapsing-remitting type. It is an approved method for the treatment of relapsing-remitting MS that can be used as a supportive therapy. Our study involves the case of a ten year old female patient with relapsing-remitting MS. This study was undertaken to examine the effects of IVIg used almost every 6 months in a patient with relapsing-remitting MS.

**Results:** This case study demonstrated that treatments of IVIg used almost every 6 months in a patient with relapsing-remitting MS have potent therapeutic actions with early beneficial responses.

**Conclusion:** IVIg used almost every 6 months shows a potential positive therapeutic treatment for relapsing-remitting MS and more large-scale clinical studies are required.

**Keywords:** Intravenous immunoglobulin; Multiple sclerosis; Relapsing-remitting

### Introduction

Pediatric multiple sclerosis (MS) with manifestations before 16 years of age occurs in 0.4-10.5% of whole MS population. The initial course of the disease is relapsing-remitting with a relapse rate generally higher than that of adults and less than 3% have a primary progressive form [1]. MS is considered to be an autoimmune, inflammatory and demyelinating disease of the central nervous system (CNS). Typically, MS begins as a relapsing-remitting disease and evolves over time into a chronic secondary progressive condition that can lead to severe disability and even death [2,3]. The number of patients affected with MS has increased to more than two millions in 2013 all over the world [4]. The core roles of T cells as well as B cells in the pathogenesis of MS have long been established [5,6]. These findings support that abnormal functions between T cells and B cells are involved in the immunopathogenesis of MS [7]. Since there were limited effective treatment options available for the patient and, so far, no prospective, placebo-controlled randomized clinical trials in children with disease-modifying therapies (DMT) have been published, we performed this case study to elucidate whether intravenous immunoglobulin (IVIg) used about every 6 months is therapeutically effective in the treatment of relapsing-remitting MS [8].

### Case Report

A 10 year old female patient was referred to our clinic on May 5, 2015 from a regional hospital where she had been admitted 3 years

earlier with symptoms of memory loss associated with a change in temperament and two febrile seizures. Her medical history revealed that she was given IVIg on May 17, 2013 and steroids for 3 weeks afterwards for the first time after the initial diagnosis of acute disseminated encephalomyelitis (ADEM). However, she had no improvement in her symptoms. Then this time we gave her the magnetic resonance imaging (MRI) scan of her brain on May 7, 2015 which showed parenchymal lesions on both sides of the brain and white matter based lesions especially on the left were observed. Based on the MRI scan and the occurrence of further relapse, we assessed she had MS. Dissemination in time and in space by MRI was satisfied according to McDonald criteria [9]. Thus she was treated with IVIg (total of 2 g/kg weight) and steroid therapy (methylprednisolone, iv, 2 mg/kg weight per day) for the second time to manage symptoms.

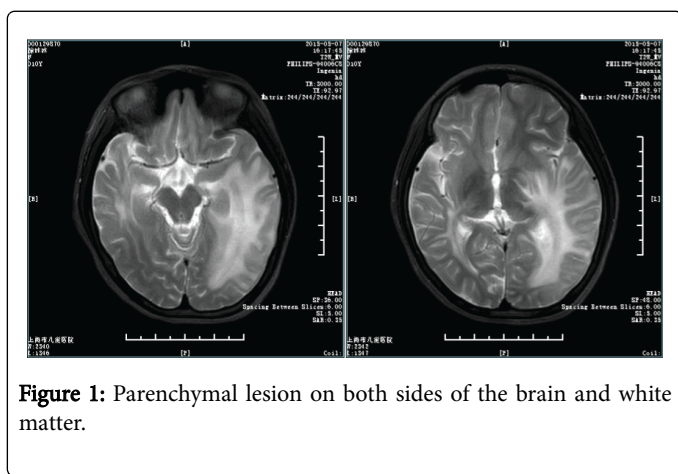
On October 5, 2015, a further episode which was diagnosed as left central facial paralysis occurred and the MRI scan of her brain showed the extensive lesions. Then she again received IVIg (total of 2 g/kg weight) for the third time and steroid therapy (methylprednisolone, iv, 15 mg/kg weight per day for 3 days).

Afterwards, on February 12, 2016 and October 26, 2016, she was given IVIg (total of 0.4 g/kg weight each time) for the fourth and fifth time. The steroid therapy of methylprednisolone was gradually reduced to 2 mg/d.

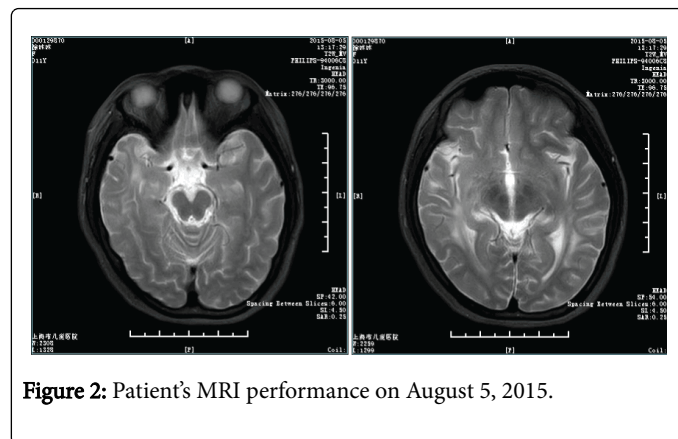
Now she presented little memory loss, no convulsion and little emotional irritability. Once a month she has a transient dizziness with nausea. Her limb activities and response ability were in better condition (Table 1).

	Dosage	Notes
May 17, 2013	Unclear	Used in other hospital
May 7, 2015	2 g/kg weight	No side effect or complication
October 5, 2015	2 g/kg weight	No side effect or complication
February 12, 2016	0.4 g/kg weight	No side effect or complication
October 26, 2016	0.4 g/kg weight	Transient dizziness with nausea

**Table 1:** Time and the dosage of IVIg use.

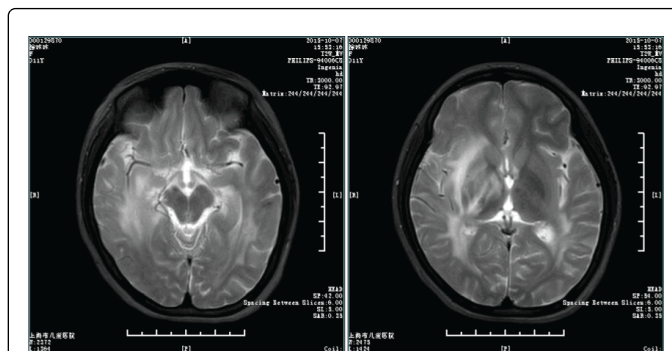


**Figure 1:** Parenchymal lesion on both sides of the brain and white matter.

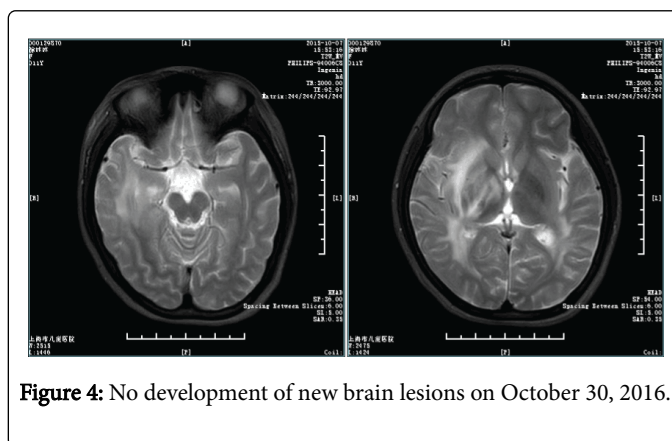


**Figure 2:** Patient's MRI performance on August 5, 2015.

Imaging examination revealed the following results. Figure 1 showed parenchymal lesion on both sides of the brain and white matter based lesions especially on the left were observed on May 7, 2015 when the patient first came to our clinic. Figure 2 showed that the patient's MRI performance on August 5, 2015 was improving. Figure 3 showed new lesions on the right side of the brain MRI scan on October 7, 2015 shortly after the further clinical episode. At that time, the patient received IVIg for the third time. Figure 4 showed no development of new brain lesions on October 30, 2016 and the patient's MRI performance was improving.



**Figure 3:** New lesions on the right side of the brain MRI scan on October 7, 2015.



**Figure 4:** No development of new brain lesions on October 30, 2016.

## Discussion

Major questions on childhood MS remain only partially answered (biological characteristics not investigated, diagnostic criteria not yet established, only common differential diagnosis, MRI and CSF features presented). However, some collaborative researchers have studied pediatric MS cohorts and an international pediatric MS study group (IPMSSG) has recently formed to address the diagnosis and treatment of children with MS [10].

The occurrence of further relapses and new lesions on MRI after the first episode strongly suggested the diagnosis of pediatric MS in our patient. Relapses and remission from symptoms can be observed in our case.

IVIg has been shown effective in the treatment of some immune mediated diseases like idiopathic thrombocytopenic purpura, Kawasaki disease, Guillain-Barre syndrome, dermatomyositis and many others [11] and carries the potential of modifying and/or reversing a number of the immunologic abnormalities found in MS. IVIg treatment has a beneficial effect on MS using both clinical and MRI endpoints [12]. MS is an immune-mediated disorder affecting the CNS that is thought to result from destruction of myelin that is produced by oligodendrocytes by autoreactive T cells. There is a large body of evidence that IVIg can modulate an immune reaction at the level of T cells, B cells, and macrophages, interferes with antibody production and degradation, modulates the complement cascade and has effects on the cytokine network. However, the accurate mechanism of action is not yet clear [13]. IVIg may neutralize circulating

autoantibodies against myelin proteins, induce functional blockade of Fc receptors on macrophages, down regulate production and/or neutralize inflammatory cytokines, inhibit damage by activated complement pathway, restore the physiological pattern of spontaneous fluctuations in the concentration of autoantibodies in plasma and suppress inducer T-cells and B-cells. It is generally accepted that IVIg can interfere with the immune system at nearly every level [14] such as manipulation of the idiotype network by the presence of anti-idiotype antibodies in IVIg. Furthermore, IVIg promote remyelination in demyelinating disorders of animal models and in virus-induced experimental encephalomyelitis, which are the crucial difference between IVIg treatment and all other available immunomodulatory treatments [15,16]. So in patients with relapsing- remitting MS, IVIg is in first evidence class and second line recommendation [13].

This case study demonstrated that treatment with IVIg markedly changed the outcome of a patient with relapsing-remitting MS, suggesting the possibility that IVIg, an immunomodulator, used about every 6 months is useful for the treatment of this disease. But quite possibly, the ability to respond to immunotherapy of IVIg could differ depending on the severity of disease at the time of treatment and the different stages of disease [17]. Meanwhile, the cost of IVIg is not likely to decrease due to the safety issues and manufacturing processes. So a large-scale clinical study for relapsing-remitting MS would be required to clarify the definitive efficacy and dosage of IVIg used about every 6 months in relapsing-remitting MS and the probable mechanism(s) for the pathophysiological actions of IVIg. Moreover, the examination of brain MRI, physical activity and neuropsychological evaluation will help to elucidate the further information on therapeutic efficacy of IVIg in relapsing-remitting MS [18,19]. There are many treatment approaches in children with MS and many on-going clinical trials and approaches and challenges in conducting clinical trials in the pediatric population are discussed [20]. IVIG can presently not be chosen as a first-line treatment in relapsing-remitting MS, but is a valuable alternative for patients, who show contraindications or are unwilling to take the approved medications due to frequent injections [21]. Since the younger patient group exhibits clinical features distinct from the older children, and have a longer time to diagnose and time to begin DMT (disease-modifying therapy), early diagnosis and treatment is important [22].

## Acknowledgement

We would like to express our gratitude to the patient and her parents for their cooperation. This work was supported by National Natural Science Foundation of China (81650008) and Shanghai Science and Technology Fund (16410723400). We would like to thank research technician IV Almedia J Mccoy in Children's Hospital of Philadelphia for her patient guidance.

## References

1. Borriello G, Prosperini L, Luchetti A, Pozzilli C (2009) Natalizumab treatment in pediatric multiple sclerosis: A case report. *Eur J Paediatr Neurol* 13: 67-71.
2. Inui T, Katsuura G, Kubo K, Kuchiike D, Chenery L, et al. (2016) Case report: GcMAF treatment in a patient with multiple sclerosis. *Anticancer Res* 36: 3771-3774.
3. Ebers GC (2000) The natural history of multiple sclerosis. *Neurol Sci* 21: S815-817.
4. Browne P, Chandraratna D, Angood C, Tremlett H, Baker C, et al. (2014) Atlas of multiple sclerosis 2013: A growing global problem with widespread inequity. *Neurology* 83: 1022-1024.
5. Friese MA, Fugger L (2007) T cells and microglia as drivers of multiple sclerosis pathology. *Brain* 130: 2755-2757.
6. Disanto G, Morahan JM, Barnett MH, Giovannoni G, Ramagopalan SV (2012) The evidence for a role of B cells in multiple sclerosis. *Neurology* 78: 823-832.
7. Romme C, Bornsen L, Ratzer R (2013) Systemic inflammation in progressive multiple sclerosis involves follicular T-helper, Th17-and activated B-cells and correlates with progression. *PLOS ONE* 8: e57820.
8. Inui T, Kubo K, Kuchiike D, Uto Y, Nishikata T, et al. (2015) Oral colostrum macrophage-activating factor for serious infection and chronic fatigue syndrome: Three case reports. *Anticancer Res* 35: 4545-4549.
9. McDonald WI, Compston A, Edan G (2001) Recommended diagnostic criteria for multiple sclerosis: Guidelines from the international panel on the diagnosis of multiple sclerosis. *Ann Neurol* 50: 121-127.
10. Krupp LB, Tardieu M, Amato MP (2007) International Pediatric Multiple Sclerosis Study Group criteria for pediatric multiple sclerosis and immune-mediated central nervous system demyelinating disorders: Revisions to the 2007 definitions. *Mult Scler*, 19: 1261-1267.
11. Kalanie H, Tabatabai SS (1998) Combined Immunoglobulin and azathioprine in multiple sclerosis. *Eur Neurol* 39: 178-181.
12. Lewan'ska M, Siger-Zajdel M, Selmaj K (2002) No difference in efficacy of two different doses of intravenous immunoglobulins in MS: Clinical and MRI assessment. *Eur J Neurol* 9: 565-572.
13. Stangel M, Pul R (2006) Basic principles of intravenous immunoglobulin (IVIg) treatment. *J Neurol* 253: V18-24.
14. Kazatchkine MD, Kaveri SV (2001) Immunomodulation of autoimmune and inflammatory diseases with intravenous immune globulin. *N Engl J Med* 345: 747-755.
15. Soelberg Sorensen P, Wanscher B, Schreiber K (1997) A double-blind, cross-over trial of intravenous immunoglobulin G in multiple sclerosis: Preliminary results. *Mult Scler* 3: 145-148.
16. Durelli L, Isoardo G (2002) High-dose intravenous immunoglobulin treatment of multiple sclerosis. *Neurol Sci* 23: S39-48.
17. Gordon SF, Mark SF, Jack PA (1997) Failure of intravenous immunoglobulin to arrest progression of multiple sclerosis: A clinical and MRI based study. *Mult Scler* 3: 370-376.
18. Laurent G, Jagadeesh B, Sriniv V (2015) Intravenous immunoglobulin as clinical immune-modulating therapy. *CMAJ* 187: 257-260.
19. Hughes RAC, Dalakas MC, Cornblath DR (2009) Clinical applications of intravenous immunoglobulins in neurology. *Clin Exp Immunol* 158: 34-42.
20. Tanuja C, Angelo G, Barbara BK (2016) Pediatric multiple sclerosis. *Neurology* 87: s103-s108.
21. Dudesek A, Zettl UK (2006) Intravenous immunoglobulins as therapeutic option in the treatment of multiple sclerosis. *J Neurol* 253: V50-58.
22. Anita LB, Lauren BK, Cody SO (2016) Characteristics of children and adolescents with multiple sclerosis. *Pediatrics* 138: e20160120.