

## Giant Cell Tumor of Tendon Sheath Mimicking Nodal Osteoarthritis

Khaled Al-Jarallah<sup>1\*</sup>, Salah Al Waheeb<sup>2</sup>, Youssef Attia<sup>3</sup> and Mini Abraham<sup>1</sup>

<sup>1</sup>Department of Medicine, Faculty of Medicine, Kuwait University, Kuwait

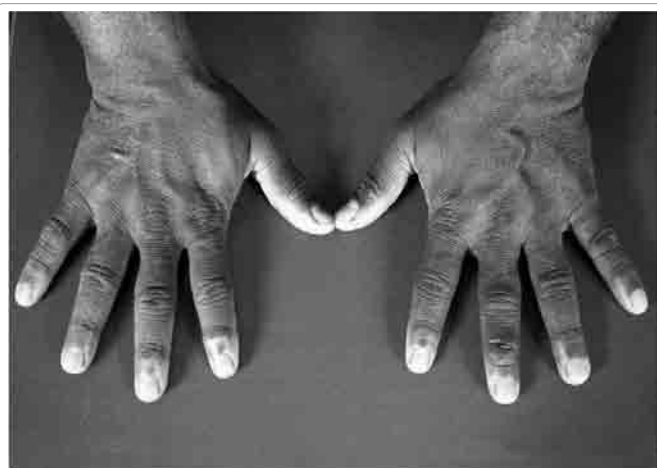<sup>2</sup>Department of Pathology, Faculty of Medicine, Kuwait University, Kuwait

<sup>3</sup>Ministry of Health, Kuwait

### Dear Editor

We would like to report an unusual presentation of giant cell tumor of tendon sheath (GCTTS) at the distal interphalangeal (DIP) joints of the hand. Giant cell tumors of tendon sheath are the second most common benign tumors of hand, simple ganglion cysts being the most common. Usual presentation is painless masses presenting for a long time. Occasionally they can cause distal numbness or mild disability secondary to the size of lesion. Peak age of occurrence is between 30 and 50 years, often seen in women than in men [1]. The etiology is unknown. There is a 50% association with trauma and the most widely accepted theory is that GCTTS is a reactive or regenerative hyperplasia associated with an inflammatory process [2]. Surgical excision is the treatment of choice. Symptoms of the disease are non specific; hence clinical knowledge of the presentation of GCTTS may be beneficial to clinicians.

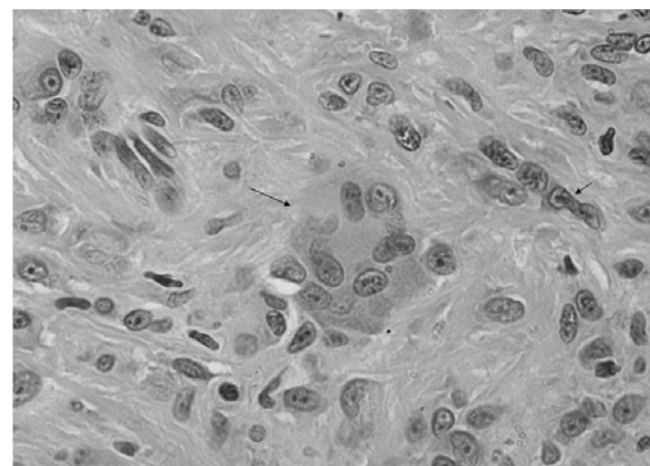
A 51-year old Indian male, a heavy vehicle driver, was referred to rheumatology clinic from General Practitioner with history of painless swellings at the distal interphalangeal (DIP) joints of both hands with a referral diagnosis of nodal osteoarthritis. The swellings were insidiously growing for the past six years and did not interfere with hand movements and functions. There was no history of preceding trauma and there were no similar swellings elsewhere in the body. There were no constitutional symptoms such as night sweats, fever, loss of appetite or weight loss. The patient was not obese and there was no history of diabetes or dislipidemia. His systemic review was normal. Examination of hand revealed 3x4 mm in size lobulated, nodular swellings located on dorsal aspect of all digits adjacent to DIP joints (Figure 1) [Patient's consent was obtained for publication]. Skin over the swelling was normal. Nodules were smooth, soft to firm, nontender, not adherent to the overlying skin, but held in place by the basement structures. There was no transillumination through the swelling. There was normal sensory perception in the digit and range of motion was normal in the



**Figure 1:** Nodular swellings of distal interphalangeal joints (DIP) in both hands.

related joints. The patient's blood parameters (complete blood count, blood sugar, indicators of acute phase response, lipid profile, renal profile, liver profile and serology) were normal. Plain radiography of hands showed soft tissue swellings, with no erosion or calcification with preserved joint space. The differential diagnosis at this point was nodal osteoarthritis. The patient was referred for excision biopsy.

Pathology showed a firm yellowish white piece of tissue measuring 4x5x5 mm. Paraffin blocks were made, glass slides were prepared and processed with Hematoxylin and Eosin stains. Histopathology showed a lobulated well circumscribed partially encapsulated tumor. The bulk of the tumor is composed of small, round to spindle shaped mononuclear cells with pink cytoplasm and round, often grooved nuclei with inconspicuous nucleoli. Many osteoclast-like giant cells were present containing a variable number of nuclei from 4 to 20 nuclei per cell. The nuclear characteristics of the giant cells were similar to the mononuclear cells. Haemosiderin deposits were focally present. The background stroma showed collagen bands in areas and hyalinization in other areas (Figure 2). No mitotic figures or necrosis were identified. A diagnosis of GCTTS was made. Because of the benign nature of



**Figure 2:** High power of the tumor showing osteoclast like giant cell (long arrow), mono nucleated cells (short arrow) (x400 magnification).

**\*Corresponding author:** Khaled Al-Jarallah, Department of Medicine, Faculty of Medicine, Kuwait University, Kuwait, P.O.Box 24923, Safat 13110, Kuwait, Tel: (965) 99666082; Fax: (965) 25338907; E-mail: [aljarallah@hsc.edu.kw](mailto:aljarallah@hsc.edu.kw)

**Received** February 13, 2012; **Accepted** March 21, 2012; **Published** March 23, 2012

**Citation:** Al-Jarallah K, Waheeb SA, Attia Y, Abraham M (2012) Giant Cell Tumor of Tendon Sheath Mimicking Nodal Osteoarthritis. J Arthritis 1:103. doi:10.4172/2167-7921.1000103

**Copyright:** © 2012 Al-Jarallah K, et al. This is an open-access article distributed under the terms of the Creative Commons Attribution License, which permits unrestricted use, distribution, and reproduction in any medium, provided the original author and source are credited.

the lesion and preserved hand functions, patient refused to undergo surgical excision for rest of the lesions. Patient was followed up for a period of three years. There was no sign recurrence of excised tumor.

The localized form of giant cell tumors is the most common subset of giant cell tumors. It has been also called tenosynovial giant cell tumor and nodular tenosynovitis and consists principally of a proliferation of synovial cells arising from a tendon sheath. It occurs at any age, but usually between 30 and 50 years, with 2:1 female predominance [1]. They occur predominantly in the hand where they probably represent the second most common benign tumors of hand, simple ganglion cysts being the most common. The majority occur in the fingers in close proximity to the synovium of the tendon sheath of interphalangeal joint. The lesions may infrequently erode or infiltrate the nearby bone [3] or rarely involve the skin. Other sites of involvement include the wrist, ankle, foot, knee and very rarely the elbow and the hip [2]. The tumors develop gradually over a long period of time. Antecedent trauma is reported in a variable number of cases (1 to 50%) [2,3]. The most common presenting symptom is that of a painless swelling, however GCTTS might cause compression neuropathy [4].

Our patient had a unique presentation of GCTTS by the involvement at all the DIP joints of both hands. He had no history of trauma and the disease process started at the age of 45 years which is usual age of onset in this lesion. The clinical differential diagnosis of a swelling of DIP includes ganglion cysts, foreign body granuloma, epidermoid cyst, mucous cyst, sebaceous cyst, lipoma, nodal osteoarthritis, sarcoidosis, psoriatic arthritis, multicentric reticulohistiocytosis, tendinous xanthoma, fibroma of tendon sheath, infection, rheumatoid nodule, gout, cavernous hemangioma and amyloidoma [5,6].

The tumor is a benign condition with a capacity of local recurrence. Local excision is the treatment of choice. Complete excision is difficult as the mass is associated with the tendon sheath of the joint. Four to thirty percent of cases recur [7,8] but these recurrences are non-destructive and are controlled by surgical excision. It has been suggested the recurrences develop most often in highly cellular tumors or lesions with a high mitotic activity. Al-Qattan [9], in his review found that encapsulated tumors do not recur, whereas uncapsulated tumors have

a tendency to recur. Other factors such as poor surgical technique and bony invasion of the tumors also favor recurrences. Kotwal et al. [10] reported the importance of a classification system to identify patients with high risk of recurrence and a favorable outcome of postoperative radiotherapy for those groups of patients with high risk of recurrence. The patients with high risk either showed mitotic figures in histology or were those with possible incomplete excision. The patient in our report didn't come under this category.

Presentation of GCTTS involving all the DIP joints of both hands simulating nodal OA is unusual. Clinicians should include the possibility of GCTTS among differential diagnosis of swellings in interphalangeal joints that resemble osteoarthritis of hands.

#### References

1. James R Verheyden, Timothy A Damron (2009) Giant cell tumor of tendon sheath.
2. Monaghan H, Salter DM, Al-Nafussi A (2001) Giant cell tumour of tendon sheath (localised nodular tenosynovitis): clinicopathological features of 71 cases. *J Clin Pathol* 54: 404-407.
3. Uriburu IJ, Levy VD (1998) Intraosseous growth of giant cell tumors of the tendon sheath (localized nodular tenosynovitis) of the digits: report of 15 cases. *J Hand Surg Am* 23: 732-736.
4. Wang CW, Chen CY, Wu K, Yang RS (2011) Giant cell tumor of the tendon sheath causing tarsal tunnel syndrome: A case report. *FJMD* 2: 75-77.
5. Mufti S, Malik LM, Sheikh KR, Hussain I (2009) Giant cell tumour of the tendon sheath: a case report. *J Pak Assoc Dermatol* 19: 57-59.
6. Mukhopadhyay S, Damron TA, Valente AL (2003) Recurrent amyloidoma of soft tissue with exuberant giant cell reaction. *Arch Pathol Lab Med* 127: 1609-1611.
7. Reilly KE, Stern PJ, Dale JA (1999) Recurrent giant cell tumors of the tendon sheath. *J Hand Surg Am* 24: 1298-1302.
8. Rao AS, Vigorita VJ (1984) Pigmented villonodular synovitis (giant-cell tumor of the tendon sheath and synovial membrane). A review of eighty-one cases. *J Bone Joint Surg Am* 66: 76-94.
9. Al-Qattan MM (2001) Giant cell tumours of tendon sheath: classification and recurrence rate. *J Hand Surg Br* 26: 72-75.
10. Kotwal PP, Gupta V, Malhotra R (2000) Giant-cell tumour of the tendon sheath. Is radiotherapy indicated to prevent recurrence after surgery? *J Bone Joint Surg Br* 82: 571-573.