



From Minor Domestic Accident to Adrenal Tumours Related Osteoporosis

Ana Valea¹, Mara Carsote^{2*}, Anda Dumitrascu³ and Sorin Paun⁴

¹Department of Endocrinology, Iuliu Hatieganu University of Medicine and Pharmacy & Clinical County Hospital, Cluj-Napoca, Romania

²Department of Endocrinology, Carol Davila University of Medicine and Pharmacy & C.I. Parhon National Institute of Endocrinology, Bucharest, Romania

³Department of Imagery & Radiology, C.I. Parhon National Institute of Endocrinology, Bucharest, Romania

⁴Department of Surgery, Carol Davila University of Medicine and Pharmacy & Floreasca Emergency Hospital, Bucharest, Romania

Keywords: Secondary osteoporosis; Cushing's syndrome; Adrenal tumor

Secondary osteoporosis (OP) is caused by many conditions and endogenous Cushing's syndrome (CS) is one of them. CS involves trabecular bone damage in two thirds of cases with consecutive vertebral fractures that sometimes represent the first sign of both OP and CS but the previous exposure to glucocorticoids excess is found up to 2 years before [1]. 5% of secondary osteoporosis related vertebral fractures underline subclinical forms of hypercortisolism and the majority of them are caused by an adrenal tumour [2]. 10-15% of adrenal CS is related to bilateral forms of adrenal neoplasia [3].

We present a female case discovered with multiple diseases starting from a minor trauma. 54-year female known with high blood pressure controlled under adequate therapy for the last 5 years suffered a minor fall while she was cleaning her house. Lumbar back pain (with some unspecific abdominal pain) persisted for 2 months when she decided to ask for a general practitioner control. The abdominal ultrasound found two bilateral large adrenal tumors that were confirmed by the computed tomography exam (Figure 1). Vertebral fractures at first and third lumbar vertebrae were found and she was referred for an endocrine evaluation. Central Dual-energy X-Ray Absorptiometry was non interpretable at lumbar spine because of the fractures and hip bone mineral density was of 0.827 g/cm², T-score of -1.4 and Z-score of -1.1. The morning plasma cortisol was high of 1046 nmol/L (normal levels between 171 and 536) with suppressed plasma morning ACTH (Adrenocorticotrophic Hormone) of levels below 5 pg/mL (with normal ranges between 5 and 46 pg/mL) suggesting an adrenal CS. Adrenal surgery was recommended and she asked for a second endocrine opinion. Except for mild hypokaliemia of 3.26 mmol/L (normal between 3.5 and 5.1 mmol/L) and secondary osteoporosis the only anomaly was the re-confirmation of high endogen glucocorticoid exposure coming from adrenals (Table 1). Based on secretor aspects and large tumors volume one time bilateral adrenalectomy was performed and nodular hyperplasia was confirmed (with no malignancy features). Adrenal substitution was started together with oral bisphosphonate, vitamin D and calcium supplements.

| Hormone | Value | Normal levels / significance |
|--|-------|---|
| Morning plasma cortisol (µg/dL) | 32 | 11 - 22 |
| Baseline | | |
| Adrenocorticotrophic Hormone-ACTH (pg/mL) | 1 | 6 - 65 |
| Baseline | | |
| Morning plasma cortisol | 30 | < 1.8 |
| After 2 days of daily 2 miligrams (mg) of dexametasone (µg/dL) | | |
| Morning plasma cortisol | 34 | lack of suppression suggests non-pituitary CS |
| After 2 days of daily 8 miligrams (mg) of dexametasone (µg/dL) | | |

Table 1: Cushing's syndrome tests in 54-year old female with newly discovered vertebral fractures and bilateral adrenal tumours.

This case highlights the importance of primary health care in adequately selecting the subjects who need serial tests in order to confirm severe diagnosis.

Acknowledgment

We thank to the patient who consented for this paper. We also thank to all the medical team.

References

- Chiodini I, Torlontano M, Carnevale V, Trischitta V, Scillitani A (2008) Skeletal involvement in adult patients with endogenous hypercortisolism. *J Endocrinol Invest* 31: 267-276.
- Shimon I (2015) Screening for Cushing's syndrome: is it worthwhile?. *Pituitary* 18: 201-205.
- Morelli V, Palmieri S, Salcunil AS (2013) Bilateral and unilateral adrenal incidentalomas: biochemical and clinical characteristics. *Eur J Endocrinol* 168: 235-241.

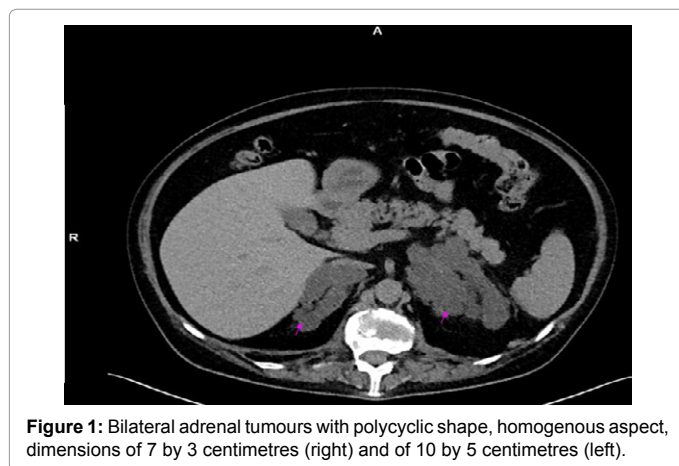


Figure 1: Bilateral adrenal tumours with polycyclic shape, homogenous aspect, dimensions of 7 by 3 centimetres (right) and of 10 by 5 centimetres (left).

***Corresponding author:** Mara Carsote, Department of Endocrinology, Carol Davila University of Medicine and Pharmacy & C.I. Parhon National Institute of Endocrinology, Bucharest, Romania, Tel: +40213172041; E-mail: carsote_m@hotmail.com

Received June 22, 2015; Accepted June 24, 2015; Published July 01, 2015

Citation: Valea A, Carsote M, Dumitrascu A, Paun S (2015) From Minor Domestic Accident to Adrenal Tumours Related Osteoporosis. *Primary Health Care* 5: i103. doi:10.4172/2167-1079.1000i103

Copyright: © 2015 Valea A, et al. This is an open-access article distributed under the terms of the Creative Commons Attribution License, which permits unrestricted use, distribution, and reproduction in any medium, provided the original author and source are credited.