

Evaluation of Effect of Posterior Dynamic Stabilization IntraSPINE System on Sagittal Spinal Balance using EOS[®] X-Ray Imaging System

Simona Bistazzoni^{1*}, Michelangelo De Angelis², Manuela D'ercole³, Carmela Chiaramonte³, Antonio Carotenuto⁴, Giovanni Cardarelli⁵, Francesco Ricciardi², Gualtiero Innocenzi² and Giancarlo Guizzardi⁶

¹Department of Neurosurgery, Sant'Anna Hospital, Como, Italy

²Department of Neurosurgery, IRCCS Neuromed, Pozzilli, Italy

³Department of Neurosurgery, IRCCS Istituto delle Scienze Neurologiche Bologna, Italy

⁴Division of Neurosurgery, School of Medicine and Surgery "Federico II" Naples, Italy

⁵Department of Neurosciences, Reproductive and Odontostomatological Sciences, Federico II University, Italy

⁶Department of Neurosurgery, Centro Chirurgico Toscano Arezzo, Italy

*Corresponding author: Simona Bistazzoni, Department of Neurosurgery, Sant'Anna Hospital, Como, Italy, Tel: +393451599637; E-mail: simona.bistazzoni@virgilio.it

Received date: June 12, 2017; Accepted date: August 26, 2017; Published date: August 31, 2017

Copyright: © 2017 Bistazzoni S, et al. This is an open-access article distributed under the terms of the Creative Commons Attribution License, which permits unrestricted use, distribution, and reproduction in any medium, provided the original author and source are credited.

Abstract

Aim of this prospective study is to assess the effect of posterior dynamic stabilization IntraSPINE system on sagittal spinal balance, using EOS[®] X-Ray imaging system. Between March and December 2015, 8 patients affected by lumbar soft stenosis underwent indirect decompression of the lumbar canal by positioning of IntraSPINE[®] device. Sagittal balance was evaluated considering following parameters: C7 Plum Line (C7PL), Thoracic Kyphosis (TK), Lumbar Lordosis (LL), Pelvic Tilt (PT), Pelvic Index (PI) and Sacral Slope (SS). The EOS[®] 2D/3D system and corresponding sterEOS 3D software for surface 3D reconstruction has been used to calculate the above mentioned parameters. All patients had neurogenic claudication and low back pain for more than 6 months and resistant to drug treatment. They underwent clinical examination before surgery and 1 month after surgery. Statistical analyses were performed using Stata software. All results were considered significant if $p < 0.05$. C7PL, TK, LL, PI and SS were not modified after surgery. PT increased after surgery. VAS, ODI and JOA significantly increased after surgery. The results show that the posterior dynamic stabilization offered by this device leads to a good symptoms control and does not seem to change the sagittal balance.

Keywords: IntraSPINE; Sagittal balance; Dynamic posterior stabilization device; Intralaminar device; EOS[™] X-Ray

Introduction

Neurogenic claudication caused by lumbar spinal stenosis and spinal instability currently represent the most frequent symptoms for visiting a spine surgeon in the occidental countries [1]. The initial treatment approach is conservative and prescribes anti-inflammatory medications, physical therapy programs and epidural steroid injections. Unfortunately, only a small number of patients take benefits from these interventions obtaining a prolonged symptoms control [2]. In the case of failure of the conservative treatment, a surgical approach is indicated and a direct surgical decompression has been shown significantly improvement in pain, function and satisfaction in a remarkable number of cases with durable effects [3]. Traditional approaches include open laminectomy or laminotomy and more recently, excellent results came from the minimally invasive decompression through a mono-lateral approach with undercutting [4-6]. In cases of vertebral instability or spondylolisthesis the procedure can be completed with a fusion. Despite the fact that there are complications after such approaches [7] there is a subgroup of patients with a low Schizas scale grade (A or B) (Figure 1) [8] whose general condition and comorbidities preclude to undergo a major spinal operations.

In these cases a less invasive approach can be performed and a posterior dynamic stabilization system can be used [9-12]. The aims of dynamic stabilization are to unload the disc and the facet joints to preserve the motion under mechanical loading and to restrict abnormal motion in the spinal segment.

These devices determine an increase of both the spinal canal area and the neural foraminal area leading to an improvement in symptoms of neurogenic claudication. Current data from biomechanical and clinical studies support the short-term efficacy of interspinous and interlaminar implants in treating claudication related to moderate spinal stenosis [13,14]. Indirect decompression has been criticized as being kyphogenic in the lumbar spine.

These devices reduce the range of motion during flexion-extension at the instrumented level. The range of motion of the adjacent motion segments is not affected by the implant during axial rotation, flexion-extension, or lateral bending [15]. Djurasovic et al. [2] have shown that there are no changes in local kyphosis after implantation of the X-STOP. Despite these discordant opinions about the effects of these devices on the spine physiology, only few studies have pointed out the attention on their effect on the sagittal balance [15,16].

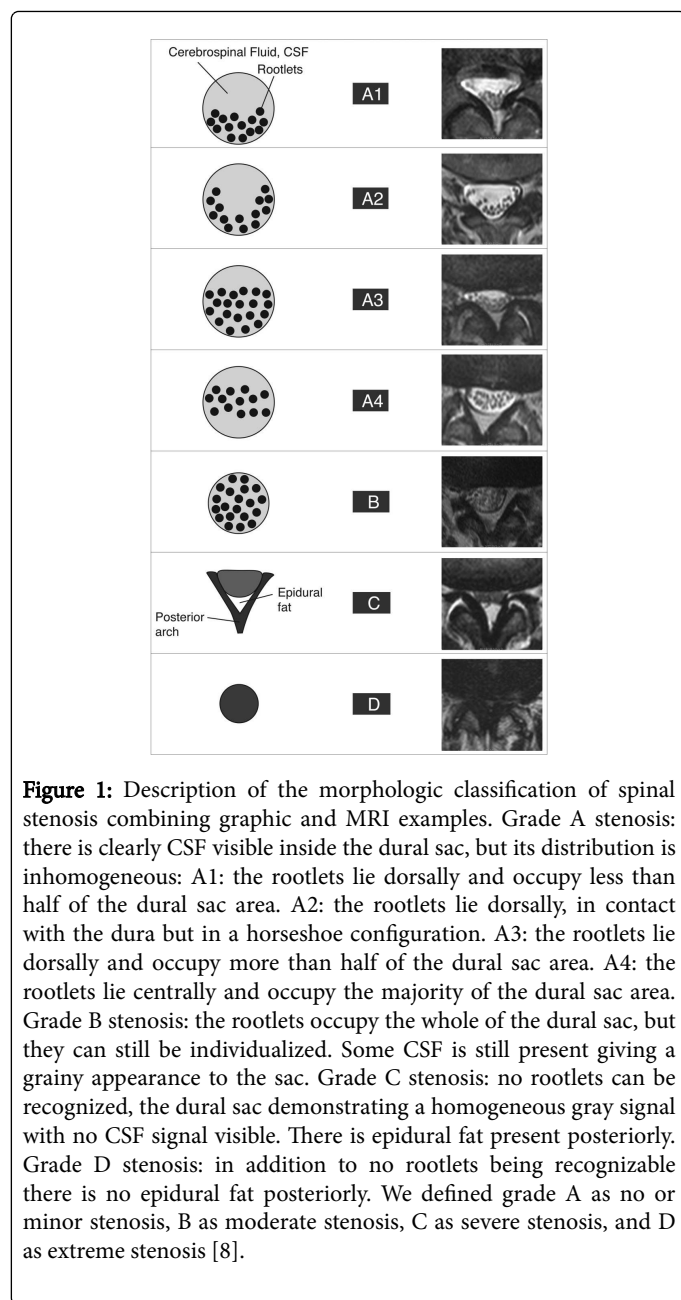


Figure 1: Description of the morphologic classification of spinal stenosis combining graphic and MRI examples. Grade A stenosis: there is clearly CSF visible inside the dural sac, but its distribution is inhomogeneous: A1: the rootlets lie dorsally and occupy less than half of the dural sac area. A2: the rootlets lie dorsally, in contact with the dura but in a horseshoe configuration. A3: the rootlets lie dorsally and occupy more than half of the dural sac area. A4: the rootlets lie centrally and occupy the majority of the dural sac area. Grade B stenosis: the rootlets occupy the whole of the dural sac, but they can still be individualized. Some CSF is still present giving a grainy appearance to the sac. Grade C stenosis: no rootlets can be recognized, the dural sac demonstrating a homogeneous gray signal with no CSF signal visible. There is epidural fat present posteriorly. Grade D stenosis: in addition to no rootlets being recognizable there is no epidural fat posteriorly. We defined grade A as no or minor stenosis, B as moderate stenosis, C as severe stenosis, and D as extreme stenosis [8].

Sagittal balance describes the ideal and "normal" alignment in the sagittal plane, resulting from the interplay between various organic factors. Any pathology that alters this equilibrium instigates sagittal

malalignment and its compensatory mechanisms. As a result, sagittal malalignment is not limited to adult spinal deformity; its pervasiveness extends through most spinal disorders. While further research is developing, the literature reports clinically relevant radiographic parameters that have significant relationships with patient-reported outcomes [17].

This is a prospective study to determine the effect of posterior dynamic stabilization IntraSPINE system [11,12] on sagittal spinal balance using EOS® X-Ray imaging system [18], since no studies have fully delineated the effect of indirect decompression on spinal balance on EOS images.

Materials and Methods

Approval from our institution's ethical board was obtained for this prospective study.

Between March and December 2015 at the Spinal Unit of the I.R.C.C.S. Neuromed Hospital of Pozzilli (Italy), 8 patients (4 female, 4 male average age 54.5 range 39-78) with symptomatic lumbar soft stenosis (Schizas grade scale A and B on MRI image) underwent indirect decompression of the lumbar canal by positioning of IntraSPINE® device by the same neurosurgeon team. All patients had neurogenic claudication and low back pain for more than 6 months that were resistant to physical and drug treatment. They had not other disease conditions and co-morbidities that could affect spinal functions or parameters of sagittal balance. Patients with degenerative spondylolisthesis greater than 4 mm translation were excluded.

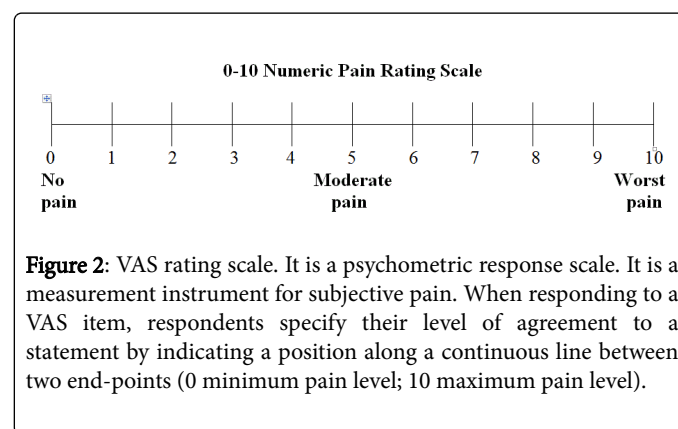


Figure 2: VAS rating scale. It is a psychometric response scale. It is a measurement instrument for subjective pain. When responding to a VAS item, respondents specify their level of agreement to a statement by indicating a position along a continuous line between two end-points (0 minimum pain level; 10 maximum pain level).

Oswestry Disability Index (ODI) (Table 1) [19], Visual Analogue Scale (VAS) (Figure 2) [20], modified Japanese Orthopaedic Association scoring system (JOA) (Table 2) [21] were used to compare the surgical effect and the degree of pain of patients 2 days before and 1 month after surgery.

ODI Score	Description
0-20%	Main Disability: Patient can cope with most ADLs. No treatment indicated except change posture, lifting, etc.
21-40%	Moderate Disability: Patient has more pain with sitting, lifting and standing. Social life is difficult, occasionally off work. Most ADLs and sex activity not affected. Conservative therapies not indicated.
41-60%	Severe Disability: Pain is significant problem for patient with significant problems with sleep, travel, personal care, ADLs, sexual activity.
61-80%	Crippled: Back pain has impact in all aspects of daily living and work. Surgical treatment indicated.

81-100%	Bed bound: These patients are bed bound or exaggerating symptoms
---------	--

Table 1: Oswestry Disability Index (ODI) [19]. The self-completed questionnaire contains ten topics concerning intensity of pain, lifting, ability to care for oneself, ability to walk, ability to sit, sexual function, ability to stand, social life, sleep quality, and ability to travel. Each topic category is followed by 6 statements describing different potential scenarios in the patient's life relating to the topic. The patient then checks the statement which most closely resembles their situation. Each question is scored on a scale of 0–5 with the first statement being zero and indicating the least amount of disability and the last statement is scored. 5 indicating most severe disability. The scores for all questions answered are summed, then multiplied by two to obtain the index (range 0 to 100%). Zero is equated with no disability and 100 is the maximum disability possible.

I. Subjective Symptom (9 points)	II. Objective observations (6 points)
A. Low back pain	A. Lasegue's sign
a. None	a. Normal
b. Occasional mild pain	b. 30°-70°
Frequent mild or occasional severe pain	c. <30°
	B. Sensory
c. Frequent or continuous severe symptom	a. Normal
	b. Mild sensory deficit
B. Leg pain and/or tingling	c. Severe sensory deficit
a. None	C. Muscle power
b. Occasional slight symptom	a. Normal
c. Frequent slight or occasional severe symptom	b. Mild weakness
	c. Severe weakness
d. Frequent or continuous severe symptom	
C. Gait	
a. Normal	
b. Able to walk farther than 500 m although resulting in pain, tingling and/or muscle weakness	
c. Unable to walk farther than 500 m owing to leg pain, tingling, and/or muscle weakness	
d. Unable to walk farther than 100 m because of leg pain, tingling, and/or muscle weakness	

III. Restriction of activities of daily living (ADL) (14 points)	Severe Restriction	Moderate Restriction	No Restriction
a. Turning over while lying	0	1	2
b. Standing	0	1	2
c. Washing	0	1	2
d. Leaning forward	0	1	2
e. Sitting (about 1 h)	0	1	2
f. Lifting or holding heavy objects	0	1	2
g. Walking	0	1	2
IV. Urinary bladder function (-6 points)			
a. Normal	0		
b. Mild dysuria	-3		
c. Severe dysuria (incontinence, urinary retention)	-6		

Table 2: Japanese Orthopaedic Association for Assessment of Low Back Pain (JOA) (21). The score rating system is divided into a 29-point scale of 9 points for “subjective symptoms”, 6 points for “objective observations”, 14 points for “activities of daily living (ADL)” and minus 6 points for “bladder function”; higher point scores indicate improved symptoms.

Five patients had an IntraSPINE® 10 mm placed at one level, 2 placed at two levels, and one placed at three levels (Table 3).

Patient	Age (years)	Number of Levels Treated	VAS Pre/Post	JOA Pre/Post	ODI (%) Pre/Post
Patient 1	48	L4-L5	06-Apr	07-Oct	42/28
Patient 2	66	L4-L5	07-Mar	06-Nov	42/18
Patient 3	39	L4-L5	09-Apr	05-Oct	58/26
Patient 4	78	L4-L5	08-Apr	10-Dec	32/16
Patient 5	64	L2-L3/L3-L4	08-Mar	07-Dec	40/15

Patient 6	47	L4-L5	08-Apr	07-Dec	44/22
Patient 7	39	L4-L5/L5-S1	05-Mar	08-Oct	34/20
Patient 8	55	L2-L3/	07-Apr	09-Nov	28/16
		L3-L4/L4-L5			

Table 3: Pre and post-operative clinical data.

We considered the following parameters to evaluate sagittal balance: C7 plum line (C7PL), thoracic kyphosis (TK), lumbar lordosis (LL), Pelvic Incidence (PI), Pelvic Tilt (PT), Sacral Slope (SS) and $PI-LL < 10^\circ$.

C7PL is defined as the horizontal offset from plumb line dropped from C7 vertebral body to the postero-superior corner of the sacral plate. It is used if a patient is in neutral, positive or negative sagittal alignment [22]. TK is commonly defined as the angle between the upper endplate of T4 vertebrae and lower endplate of T12 vertebrae [23]. LL is defined as the angle between the sacral endplate and the cranial endplate of transitional vertebrae located between the lumbar curve and the thoracic curve [24]. In consideration of the fact that up to 65% of the LL occurs in the extreme caudal lumbar segments [25] we have considered L1-S1 LL to be the standard measurement for the lumbar curve. PI is defined as the angle between a line drawn from the center of the femoral head axis to the midpoint of the sacral plate and the perpendicular to the sacral plate. PI defines the relative orientation of the sacrum versus iliac [26]. PT is defined as the angle between a line drawn from the center of the femoral head axis to the midpoint of the sacral plate and the vertical [27]. SS corresponds to the sagittal inclination of the sacral endplate and is defined as the angle between the sacral endplate of S1 vertebrae and the horizontal (Figure 3) [28]. While these last two parameters are directly related by the geometrical equation $PI=PT+SS$, they are not interchangeable in the evaluation of the sagittal plane [28]. PI-LL is defined as the difference between the PI angle and the LL angle. This parameter quantifies the mismatch between pelvic morphology and the lumbar curve [29]. The EOS® 2D/3D system with its sterEOS 3D software for surface 3D reconstruction (EOS Imaging, France) has been used to calculate the above parameters. All patients had preoperative and 1 month after surgery EOS 2D images and 3D reconstructions [30].

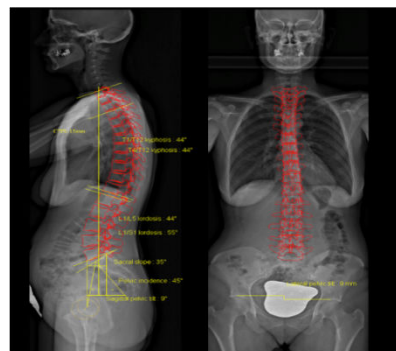

Figure 3: The picture shows EOS 3D reconstruction of our patient, on which sterEOS 3D software automatically calculates the pelvic and spinal parameters of the sagittal balance (C7PL, LL, TK, SS, PI, PT).

Statistical analyses were performed using Stata software (version 13; StataCorp LP, College Station, TX). Before each analysis, the Shapiro Wilk test was used to assess the normality of distribution of variables. If normality assumption was satisfied, parametric tests were used (Student's t-test, linear regression analysis), otherwise, non-parametric equivalent tests were employed. All results were considered significant if $p < 0.05$.

Results

In all cases normality assumption was satisfied, so parametric tests were used. For each parameter, we have calculated mean and standard deviation before and after surgery.

We obtained the following results using Student's t-test for paired data: C7PL (pre-operative 40.75 mm (mean) \pm 47.75 mm (standard deviation) vs. post-operative 31.13 mm \pm 59.46 mm, $p=0.68$); TK ($44.88^\circ \pm 10.78^\circ$ vs. $43.75^\circ \pm 7.67^\circ$, $p=0.62$); LL ($53.62^\circ \pm 8.37^\circ$ vs. $49.38^\circ \pm 12.73^\circ$, $p=0.19$); PI ($53.13^\circ \pm 10.82^\circ$ vs. $53.38^\circ \pm 11.01^\circ$, $p=0.82$); SS ($35.63^\circ \pm 10.25^\circ$ vs. $33.13^\circ \pm 9.42^\circ$, $p=0.17$) were not modified after surgery (Table 4).

Patient	PI	PT	SS	C7PL	LL	TK
	Pre/Post	Pre/Post	Pre/Post	Pre/Post	Pre/Post	Pre/Post
	(degrees)	(degrees)	(degrees)	(mm)	(degrees)	(degrees)
Patient 1	45/45	16/18	29/27	35/51	52/43	58/56
Patient 2	66/66	18/23	47/43	114/50	57/55	47/44
Patient 3	63/60	23/30	38/30	21/118	51/35	30/39
Patient 4	47/52	15/17	32/35	105/93	40/46	32/32
Patient 5	44/46	20/18	23/29	34/-56	54/57	60/48
Patient 6	69/71	16/21	53/50	34/-8	70/74	41/39
Patient 7	45/46	Sep-16	35/30	15/-28	55/49	44/41

Patient 8	45/41	20/21	25/20	-1.103448276	50/36	47/51
-----------	-------	-------	-------	--------------	-------	-------

Table 4: Pre and post-operative parameters for the evaluation of the sagittal balance

PT increased after surgery ($17.12^\circ \pm 4.22^\circ$ vs. $20.62^\circ \pm 4.44^\circ$, $p=0.02$) (Table 4). In order to establish if PT modifications were age related, we performed a linear regression analysis (using PT differences between after and pre surgery as dependent variables and age as independent variables). The age was not influencing the PT modifications ($p=0.10$).

In order to establish if PT modifications were gender related, we performed a Student t-test for unpaired data (using PT differences between after and pre surgery as variables and gender as group). The gender was not influencing the PT modifications ($p=0.53$).

VAS and ODI (respectively: 7.25 ± 1.28 vs. 3.63 ± 0.52 , $p=0.0001$; 40 ± 9.2 vs. 20.13 ± 4.85 , $p=0.0001$ Student's t-test for paired data) significantly decreased after surgery. In order to establish if VAS and ODI difference between post and pre-surgery was related to any of sagittal balance parameters modification, we performed a linear regression analysis. TK, LL, PI, SS, PT, C7PL differences between post and pre-surgery were not related to VAS modifications (respectively: $p: 0.8$, $p: 0.53$, $p: 0.83$, $p: 0.52$, $p: 0.73$, $p: 0.90$) and ODI modifications (respectively: $p: 0.43$, $p: 0.99$, $p: 0.79$, $p: 0.83$, $p: 0.56$, $p: 0.95$).

JOA significantly increased after surgery (7.37 ± 1.6 vs. 11 ± 0.92 , $p=0.0003$ Student's t-test for paired data). In order to establish if JOA difference between post and pre-surgery was related to any of sagittal balance parameters, we performed a linear regression analysis. TK, LL, PI, SS, PT, C7PL differences between post and pre-surgery were not related to JOA modifications (respectively: $p: 0.95$, $p: 0.72$, $p: 0.88$, $p: 0.99$, $p: 0.82$, $p: 0.58$).

Discussion

Spino-pelvic alignment has emergent as one of the key principles in the understanding of pathology, response to treatment and outcome. This applies to the range of spinal pathologies from adolescent deformities, to degenerative pathologies, trauma and complex adult deformity. Additionally, the concepts of spinal alignment are important not only in the diagnosis but also in the treatment of spinal conditions whether using non-operative, minimally invasive or through open surgical procedures [31].

The past two decades have seen an increased interest in the analysis of the sagittal plane in the setting of spinal pathologies and even asymptomatic subjects [32].

The restoration of sagittal spinal balance has been directly related to improvement of pain and function after spine surgery in various disease states [33-36].

Sagittal spinal balance has been described as reciprocal curves of thoracic kyphosis (TK) and lumbar lordosis (LL). The relation of the pelvis to the spine, also described as spino-pelvic balance, is a previously overlooked contributor to overall sagittal balance. Only recently it has been appreciated that pelvis morphology or PI and orientation significantly influence the sagittal spinal geometry, specifically LL, in normal and disease states [26,28,37]. Abnormal PI and spino-pelvic parameters are central to the development and progression of many spine diseases, including isthmic spondylolysis

(IS) and spondylolisthesis and, a variety of other spinal pathologies [38].

Literature has repeatedly shown that spino-pelvic alignment is a primary determinant and strongly correlates with patient-reported outcomes, as measured by pain and disability. In 2002, work by Schwab et al was the first to correlate a main driver of sagittal malalignment, lack of lumbar lordosis with a patient reported outcome: VAS [39] and later with Scoliosis Research Society questionnaire (SRS-22) and ODI [40]. Shortly after, Glassman reported that lumbar kyphosis was very poorly tolerated by patients [33]. In 2013, Schwab's team again reported that the lack of harmony between PI and LL, quantified by the PI-LL mismatch was significantly correlated with pain and disability [41]. Dubousset and Duval-Beaupère emphasized the importance of incorporating the pelvis in spinal malalignment assessment [42,43]. Following that, an increased interest in the correlation of PT and health related quality of life (HRQOL) outcomes has emerged. Lafage et al. in a series of 125 adult deformity patients, reported a significant correlation between PT (pelvic retroversion) and HRQOL outcome scores [44]. More recently, Blondel et al. have reported high correlations of Sagittal Vertical Axis (SVA) and HRQOL underlining the role of spino-pelvic sagittal parameters as the main driver of disability for adult spinal deformity (ASD) patients [45]. The same team in another study [41] of 492 patients demonstrated that SVA was one of the parameters the most correlated with the ODI ($r=0.469$). Accordingly, using retrospectively collected HRQOL and radiographic data, Schwab et al [29] have proposed three thresholds values of sagittal spino-pelvic alignment that must be achieved postoperatively following spinal reconstructive procedures in order to obtain satisfactory outcomes. These values include: 1) SVA less than 50 mm, 2) PT less than 20° and, 3) LL proportional to the PI, whereby $PI-LL=10^\circ$. These data were the first to provide surgeons with defined threshold spino-pelvic parameters to evaluate patients and guide spinal reconstructive procedures. Several studies have demonstrated that the correlation of the sagittal malalignment implies a clinical benefit for the patients [45,46]. Blondel et al. [45] underlined that the correlation of the SVA improves the clinical outcomes of patients at 2 years. This improvement was even more substantial if the restoration of the sagittal global alignment was complete.

Following the latest research that correlates spino-pelvic radiographic parameters to clinical outcomes, sagittal malalignment has been established as a potentially very disabling condition [29,34,40,41].

Sagittal balance can be difficult to measure accurately. Patients can assume many different compensatory postures, including a retroverted pelvis, extended hips, flexed knees, and dorsiflexion of the ankles to pull their head back over their pelvis [47]. Digitalized teleradiography in standing position allows a good evaluation of the sagittal balance and is the most commonly used system today, but the EOS X-rays brought a real progress for the study of the pelvi-spinal balance avoiding vertical parallax distortion with a very low dose of radiation [48]. This system is based on the use of a high sensitive detector developed by Dubousset et al. [18,30]. This collimated detector is mechanically coupled to an X-ray tube in a stiff gantry out a fan-shaped strongly collimated X-ray beam. The simultaneous use of two

X-ray tubes and two detectors, placed in two orthogonal planes in the gantry allows a simultaneous acquisition of lateral and frontal views. These two devices scan the body of the patient, in a standing position, on a vertical distance varying from 5 to 180 cm [49]. This system allows a very important reduction of the X-ray dose of an order of 80-90% versus conventional or digitalized radiographs [48]. An important dynamic range of 30000 gray levels and a pixel size of 250 μ m give good quality images [48] with a simultaneous visibility of thinnest regions as well as the thickest ones. Absence of parallax explains the lack of distortion of the anatomical structures. At last, with an appropriate software and a "bone morphing" technique, the simultaneous acquisition of sagittal and frontal views with identical anatomical landmarks in frontal and sagittal planes, makes possible the construction of a three-dimensional bone envelope weight bearing image of spine, pelvis and lower limbs which can be secondarily extracted and studied in all the planes of the space [47].

In this study we have focused our attention on the sagittal balance before and after the implantation of IntraSPINE in order to confirm that these devices do not modify this parameter. This study represents the first assessment of the sagittal balance after the implantation of a posterior dynamic device using the EOS® X-Ray imaging system. The IntraSPINE device is an intralaminar device used as a dynamic stabilization for the treatment of various degenerative diseases of the lumbar spine. Its main indication is the soft stenosis and foraminal stenosis with or without instability in symptomatic patients unable to undergo major spine surgery. In our study we considered C7PL, TK, LL, PT, PI and SS to evaluate sagittal balance.

C7PL is a useful metric parameter because it conveys a quick and unambiguous description of a trunk's general alignment. It is highly sensitive to any deviation of the spinal curvature and can be masked by the pelvic retroversion. The measurement of C7PL is dependent on patient position and the rotation of the pelvis [22]. Bridwell [50] defines as the C7PL within 6 cm of the posterior-superior corner of the S1 body. In our series C7PL was not significantly modified after surgery ($p=0.68$); and post-operative values return to normality ($31.13 \text{ mm} \pm 59.46 \text{ mm}$).

The average TK in an asymptomatic adult subject varies from 34° to 44° , with extreme values spanning from 0° to 76° range [23]. We found that TK was not significantly modified after surgery ($p=0.62$) and post-operative values return to normality ($43.75^\circ \pm 7.67^\circ$).

The mean reported values for LL on asymptomatic adult subjects varied from 43° to 63° with a standard deviation around 10° and extreme values spanning from 30° to 80° range. LL should be subject-specific and estimated based on the pelvic incidence (and the age of the subject) [51]. LL was not significantly modified after surgery ($p=0.19$) and post-operative values return to normality ($49.38^\circ \pm 12.73^\circ$).

PI was not significantly modified after surgery ($p=0.82$); because PI is a morphological parameter, the term "normal" is debatable. Nevertheless, the reported average value in asymptomatic adult subjects is $52^\circ \pm 10^\circ$ with lower values around 35° and higher values near 85° [28]. The post-operative values return to normality ($53.38^\circ \pm 11.01^\circ$).

SS was not significantly modified after surgery ($p=0.17$); the average SS in asymptomatic adult subjects has been reported to be $41^\circ \pm 8^\circ$ (28). SS is affected by patient's position. The post-operative values return to normality ($33.13^\circ \pm 9.42^\circ$).

We noticed that the IntraSPINE device determines a straightening of the spine (LL, SS, C7PL, TK decreased) without causing a global misalignment.

PT significantly increased after surgery ($p=0.02$) ($17.12^\circ \pm 4.22^\circ$ vs. $20.62^\circ \pm 4.44^\circ$); the PT is a dynamic parameter that also changes through rotation of the pelvis about the hip axis. The average PT in asymptomatic adult subjects has been reported to be $13^\circ \pm 6^\circ$ (52). PT increases over the course of childhood, and studies on children have shown that they exhibit a smaller PT at the age of 7 years old (4°), than they do as adolescents (8° in 13 years old subjects) [52]. Positive values of PT denote posterior rotation of the pelvis (e.g. retroversion), and negative values denote an anterior rotation (e.g. anteversion) [27].

In our series age and gender were not related to PT modifications ($p=0.10$ and $p=0.53$, respectively).

Despite of a PT significantly increased after surgery, we have noticed that this did not compromise the LL and the general alignment.

Pelvic morphology and orientation determines the position of the lumbar spine. In an asymptomatic adult, a high correlation has been demonstrated between LL and SS ($r: [0.65;0.86]$), while the correlation between LL and PI is slightly weaker ($r: [0.60;0.69]$). No correlation between LL and the PT has been reported in the literature [24]. Instead, C7PL gives an idea about the general alignment of the trunk and highly sensitive to loss of LL [33].

Based on these findings and, more specifically, the strong correlation between the SS and the LL, Roussouly et al. studied a group of asymptomatic volunteers to define four types of LL [24]. The first two types are associated with a low SS ($<35^\circ$) and low PI: type 3 is a well-balanced lumbar spine with SS ranging from 35° - 45° , and type 4, is a balanced spine with accentuated curves throughout the thoracic and lumbar spines. While the type one is somewhat unique, the type two to four illustrate that lordosis increase with SS (Figure 4).

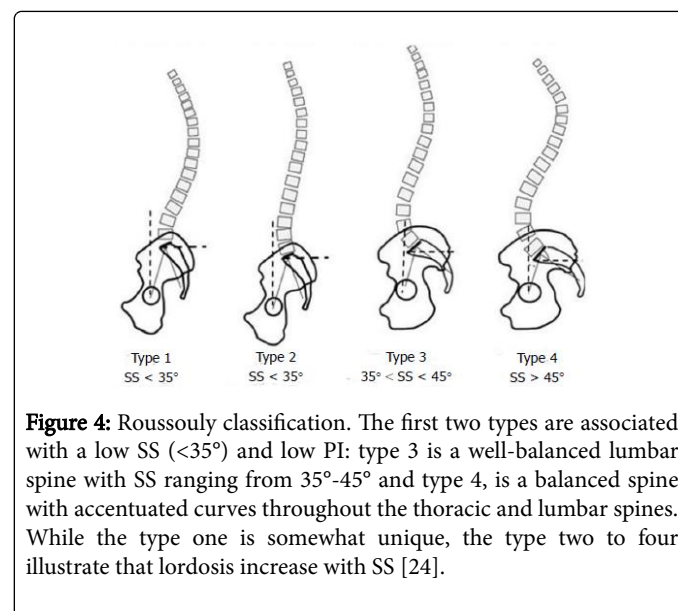


Figure 4: Roussouly classification. The first two types are associated with a low SS ($<35^\circ$) and low PI: type 3 is a well-balanced lumbar spine with SS ranging from 35° - 45° and type 4, is a balanced spine with accentuated curves throughout the thoracic and lumbar spines. While the type one is somewhat unique, the type two to four illustrate that lordosis increase with SS [24].

In our series, we had a preoperative type 3 and a post-operative type 2, with a pelvic retroversion (SS decreased and PT increased).

Schwab et al. stated that attention to PT is necessary to obtain optimal outcomes following realignment procedures. Schwab proposed

a threshold of 20° of PT and showed that increase retroversion correlates to impairment in walking endurance and quality of life [29].

In an effort to offer a simple estimate of the LL required, a new parameter has recently emerged: "PI-LL". This parameter quantifies the mismatch between pelvic morphology and the lumbar curve; the authors suggested to target a PI-LL below the 10° threshold in order to reach a satisfactory spino-pelvic alignment [29].

In our series post-operative PI-LL value was 4°<10°.

All our patients after surgery have maintained a good spino-pelvic alignment and a significantly improvement of clinical outcomes. In fact VAS and ODI significantly decreased after surgery (p=0.0001 for both) and JOA significantly increased after surgery (p=0.0003).

Evaluation scores, such as VAS, JOA and ODI, are currently applied in our clinical practice, as they offer an immediate numeric evaluation of clinical outcome, easily comparable with the preoperative one. JOA score give an immediate overview on neurological status, and it includes objective parameters regarding pain (Lasègue evaluation) and radicular assessment as motor, sensitive and bladder function. This evaluation needs to be performed by a physician. VAS and ODI evaluations provide complementary information about subjective perception of lumbar pain: VAS score is a simple numeric value of overall pain feeling, while ODI evaluation includes impact of pain on daily activities and quality of life. In our experience combination of objective and subjective evaluation offers a better comprehension of clinical outcome.

Conclusion

This is the first study to examine sagittal balance on the EOS® X-Ray system after the implantation of IntraSPINE device. The results show that the posterior dynamic stabilization offered by this device leads to a good symptoms control and does not seem to change the sagittal balance. However, this represents a preliminary study on a small cohort of patients and further studies are granted to clarify this issue.

References

1. Bouras T, Stranjalis G, Loufardaki M, Sourtzis I, Stavrinou LC, et al. (2010) Predictors of long-term outcome in an elderly group after laminectomy for lumbar stenosis. *J Neurosurg Spine* 13: 329-334.
2. Djurasovic M, Glassman SD, Carreon LY, Dimar JR (2010) Contemporary management of symptomatic lumbar stenosis. *Orthop Clin N Am* 41: 183-91.
3. Weinstein JN, Tosteson TD, Lurie JD, Tosteson A, Blood E, et al. (2010) Surgical versus non-operative treatment for lumbar spinal stenosis four-year results of the spine patient outcomes research trial. *Spine* 35: 1329-38.
4. Rosen DS, O'Toole JE, Eichholz KM, Hrubes M, Huo D, et al. (2007) Minimally invasive lumbar spinal decompression in the elderly: Outcomes of 50 patients aged 75 years and older. *Neurosurgery* 60: 503-510.
5. Turner JA, Ersek M, Herron L, Deyo R (1992) Surgery for lumbar spinal stenosis. Attempted meta-analysis of the literature. *Spine* 17: 1-8.
6. Alimi M, Hofstetter CP, Pyo SY, Paulo D, Härtl R (2015) Minimally invasive laminectomy for lumbar spinal stenosis in patients with and without preoperative spondylolisthesis: Clinical outcome and reoperation rates. *J Neurosurg Spine* 22: 339-52.
7. Deyo RA, Mirza SK, Martin BI, Kreuter W, Goodman DC, et al. (2010) Trends, major medical complications and charges associated with surgery for lumbar spinal stenosis in older adults. *JAMA* 303: 1259-65.
8. Schizas C, Theumann N, Burn A, Tansey R, Wardlaw D, et al. (2010) Qualitative grading of severity of lumbar spinal stenosis based on the morphology of the dural sac on magnetic resonance images. *Spine* 35: 1919-1924.
9. Pan B, Zhang ZJ, Lu YS, Xu WG, Fu CD. (2014) Experience with the second-generation Wallis interspinous dynamic stabilization device implanted in degenerative lumbar disease: A case series of 50 patients. *Turk Neurosurg*. 24: 713-719.
10. Ha KY, Seo JY, Kwon SE (2013) Posterior dynamic stabilization in the treatment of degenerative lumbar stenosis: Validity of its rationale. *J Neurosurg Spine* 18:24-31.
11. Guizzardi G, Petrini P (2008) DIAM spinal stabilization systems. Motion preservation surgery of the spine: Advances techniques and controversies. Philadelphia, PA: Saunders Elsevier 519-522.
12. Darwono AB (2015) Novel interlaminar dynamic stabilization concept and device (intraSPINE) for the treatment of early and late degenerative problems in the lumbar spine. In Kuniyoshi Abumi and S Rajasekaran, ed. *Modern techniques in spine surgery*. New Dhely: Jaypee Brothers Medical Publisher, pp: 412-432.
13. Schulte LM, O'Brien JR, Matteini LE, Yu W (2011) Change in sagittal balance with placement of an interspinous spacer. *Spine* 36: E1302-E1305.
14. Bae HW, Laurysen C, Maislin G, Leary S, Musacchio MJ (2015) Therapeutic sustainability and durability of coflex interlaminar stabilization after decompression for lumbar spinal stenosis: A four year assessment. *Int J Spine Surg* 11: 9:15.
15. Lindsey DP, Swanson KE, Fuchs P, Hsu KY, Zucherman JF, et al. (2003) The effects of an interspinous implant on the kinematics of the instrumented and adjacent levels in the lumbar spine. *Spine* 28: 2192-2197.
16. Djurasovic M, Glassman SD, Carreon LY, Dimar JR (2010) Contemporary management of symptomatic lumbar stenosis. *Orthop Clin N Am* 41: 183-91.
17. Diebo BJ, Varghese JJ, Lafage R, Schwab FJ, Lafage V (2015) Sagittal alignment of the spine: What do we need to know? *Clin Neurol Neurosurg* 139: 295-301.
18. Dubouset J, Charpak G, Dorion I, Skalli W, Lavaste F, et al. (2005) A new 2 D and 3D imaging approach to musculoskeletal physiology and pathology with low-dose radiation and the standing position: The EOS system. *Bull Acad Natl Med* 189: 287-297.
19. Fairbank JC, Pynsent PB (2000) The Oswestry disability index. *Spine* 25: 2940-2952.
20. Reips UD, Funke F (2008) Interval-level measurement with visual analogue scales in Internet-based research: VAS Generator. *Behav Res Methods* 40: 699-704.
21. Sato N, Sekiguchi M, Kikuchi S, Shishido H, Sato K, et al. (2012) Effects of long-term corset wearing on chronic low back pain. *Fukushima J Med Sci* 58: 60-65.
22. Lafage V, Diebo BG, Schwab F (2015) Sagittal Spino-Pelvic Alignment Parameters. Global alignment. Sagittal Vertical Axis (SVA). In Lafage V, Diebo BG, Schwab F, ed. *Sagittal Spino-Pelvic Alignment: from Theory to Clinical Application*. Madrid: Editorial Medica Panamericana, p: 22.
23. Lafage V, Diebo BG, Schwab F (2015) Regional curvatures. Thoracic Kyphosis (TK). In Lafage V, Diebo BG, Schwab F, ed. *Sagittal Spino-Pelvic Alignment: from Theory to Clinical Application*. Madrid: Editorial Medica Panamericana, pp: 20-21.
24. Roussouly P, Gollopy S, Berthonnaud E, Dimnet J (2005) Classification of the normal variation in the sagittal alignment of the human lumbar spine and pelvis in the standing position. *Spine* 30: 346-353.
25. Been E, Barash A, Marom A, Kramer PA (2010) Vertebral bodies or discs: Which contributes more to human-like lumbar lordosis? *Clin Orthop Relat Res* 468: 1822-1829.
26. Legaye J, Duval-Beaupère G, Hecquet J, Marty C (1998) Pelvic incidence: A fundamental pelvic parameter for three-dimensional regulation of spinal sagittal curves. *Eur Spine J* 7: 99-103.

27. Lafage V, Diebo BG, Schwab F. (2015) Chapter 1 spino-pelvic alignment parameters. *Sagittal spino-pelvic parameters. Pelvic Tilt (PT) and Sacral Slope (SS)*. Editorial Medica Panamericana, pp: 17-18.
28. Vialle R, Levassor N, Rillardon L, Templier A, Skalli W, et al. (2005) Radiographic analysis of the sagittal alignment and balance of the spine in asymptomatic subjects. *J Bone Joint Surg Am* 87: 260-267.
29. Schwab F, Patel A, Ungar B, Farcy JB, Lafage V (2010) Adult spinal deformity-postoperative standing imbalance: How much can you tolerate? An overview of key parameters in assessing alignment and planning corrective surgery. *Spine* 35: 2224-2431.
30. Dubouset J, Charpak G, Skalli W, Kalifa G, Lazennec JY (2007) EOS stereo-radiography system: Whole-body simultaneous anteroposterior and lateral radiographs with very low radiation dose. *Rev Chir Orthop Repar Appar Mot* 93: 141-143.
31. Lafage V, Diebo BG, Schwab F (2015) Preface. In Lafage V, Diebo BG, Schwab F, ed. *Sagittal Spino-Pelvic Alignment: From theory to clinical application*. Madrid: Editorial medica panamericana, p: 9.
32. Lafage V, Diebo BG, Schwab F (2015) Spino-pelvic alignment parameters. Introduction. In Lafage V, Diebo BG, Schwab F, ed. *Sagittal Spino-Pelvic Alignment: from Theory to Clinical Application*. Madrid: Editorial Medica Panamericana, p: 13.
33. Glassman SD, Berven S, Bridwell K, Horton W, Dimar JR (2005) Correlation of radiographic parameters and clinical symptoms in adult scoliosis. *Spine* 30: 682-688.
34. Glassman SD, Bridwell K, Dimar JR, Horton W, Berven S, et al. (2005) The impact of positive sagittal balance in adult spinal deformity. *Spine* 30: 2024-2029.
35. Lazennec JY, Ramare S, Arafati N, Laudet CG, Gorin M, et al. (2000) Sagittal alignment in lumbosacral fusion: Relations between radiological parameters and pain. *Eur Spine J* 9: 47-55.
36. Jackson RP, McManus AC (1994) Radiographic analysis of sagittal plane alignment and balance in standing volunteers and patients with low back pain matched for age, sex and size: A prospective controlled clinical study. *Spine* 19: 1611-1618.
37. Roussouly P, Gollogly S, Berthonnaud E, Labelle H, Weidenbaum M (2006) Sagittal alignment of the spine and pelvis in the presence of L5-S1 isthmic lysis and low grade spondylolisthesis. *Spine* 31: 2484-2490.
38. Mehta VA, Amin A, Omeis I, Gokaslan ZL, Gottfried ON (2015) Implications of spino-pelvic alignment for the spine surgeon. *Neurosurgery* 76: S42-56.
39. Schwab FJ, Smith VA, Biserni M, Gamez L, Farcy J-PC, et al. (2002) Adult scoliosis: A quantitative radiographic and clinical analysis. *Spine* 27: 387-392.
40. Schwab FJ, Lafage V, Farcy J, Bridwell KH, Glassman SSD, et al. (2008) Predicting outcome and complications in the surgical treatment of adult scoliosis. *Spine* 33: 2243-2247.
41. Schwab FJ, Blondel B, Bess S, Hostin R, Shaffrey CI, et al. (2013) Radiographical spino-pelvic parameters and disability in the setting of adult spinal deformity: A prospective multicenter analysis. *International Spine Study Group (ISSG)*. *Spine* 38: E803-812.
42. Dubouset J (1994) Three-dimensional analysis of the scoliotic deformity. In: Weinstein S, editor. *Pediatr Spine Princ Pract*. New York: Raven Press; p. 479-496.
43. Duval-Beaupère G, Schmidt C, Cosson P (1992) A barycentremetric study of the sagittal shape of spine and pelvis: The conditions required for an economic standing position. *Ann Biomed Eng* 20: 451-462.
44. Lafage V, Schwab F, Patel A, Hawkinson N, Farcy JP (2009) Pelvic tilt and truncal inclination: Two key radiographic parameters in the setting of adults with spinal deformity. *Spine* 34: E599-E606.
45. Blondel B, Schwab F, Ungar B, Smith J, Bridwell K, et al. (2012) Impact of magnitude and percentage of global sagittal plane correction on health-related quality of life at 2-years follow-up. *Neurosurgery* 71: 341-348.
46. Smith JS, Klineberg E, Schwab F, Shaffrey CI, Moal B, et al. (2013) Change in classification grade by the srs-schwab adult spinal deformity classification predicts impact on health-related quality of life measures: Prospective analysis of operative and non-operative treatment. *Spine* 38: 1663-1671.
47. Harding IJ, Charosky S, Vialle R, Chopin DH (2008) Lumbar disc degeneration below a long arthrodesis (performed for scoliosis in adults) to L4 or L5. *Eur Spine J* 17: 250-254.
48. Morvan G, Mathieu P, Vuillemin V, Guerini H, Bossard P, et al. (2011) Standardized way for imaging of the sagittal spinal balance. *Eur Spine J* 20: S602-S608.
49. Deschênes S, Charron G, Beaudoin G, Labelle H, Dubois J, et al. (2010) Diagnostic imaging of spinal deformities: Reducing patients radiation dose with a new slot-scanning X-ray imager. *Spine* 35: 989-994.
50. Bridwell KH. (2006) Decision making regarding Smith-Petersen vs. pedicle subtraction osteotomy vs. vertebral column resection for spinal deformity. *Spine* 31: S171-S178.
51. Lafage V, Diebo BG, Schwab F (2015) Regional curvatures. Lumbar lordosis (LL). In Lafage V, Diebo BG, Schwab F, ed. *Sagittal Spino-Pelvic Alignment: from Theory to Clinical Application*. Madrid: Editorial Medica Panamericana, pp: 18-20.
52. Mac-Thiong JM, Berthonnaud E, Dimar JR, Betz RR, Labelle H (2004) Sagittal alignment of the spine and pelvis during growth. *Spine* 29: 1642-1647.