

## Early Stage Detection of Psoriatic Arthritis Using SPECT and FDG-PET/CT

Shanthi Priya A<sup>1\*</sup> and Jobin Christ MC<sup>2\*</sup>

<sup>1</sup>Assistant Professor, Department of Biomedical Engineering, Rajalakshmi Engineering College, Chennai, India

<sup>2</sup>Professor, Department of Biomedical Engineering, Rajalakshmi Engineering College, Chennai, India

\*Corresponding authors: Shanthi Priya A, Assistant Professor, Department of Biomedical Engineering, Rajalakshmi Engineering College, Chennai, India, Tel: 044 3718 1111; E-mail: [shanthipriya.a@rajalakshmi.edu.in](mailto:shanthipriya.a@rajalakshmi.edu.in)

M.C. Jobin Christ, Professor, Department of Biomedical Engineering, Rajalakshmi Engineering College, Chennai, India, Tel: 044 3718 1111; E-mail: [jobinchrist@gmail.com](mailto:jobinchrist@gmail.com)

Received date: November 30, 2017; Accepted date: December 26, 2017; Published date: January 06, 2018

Copyright: © 2018 Priya S, et al. This is an open-access article distributed under the terms of the Creative Commons Attribution License, which permits unrestricted use, distribution, and reproduction in any medium, provided the original author and source are credited.

### Abstract

Psoriatic arthritis is one of the rare types of autoimmune disease that cause body's own immune system to harm skin and joints which leads to painful areas of swelling and inflammation. Psoriatic arthritis (PsA) is not like the other forms of arthritis that are clearly distinguishable, where arthritis is accompanied by typical psoriasis symptoms, such as a red, scaly rash that will develop silvery white patches. It's a chronic condition where hands, fingers, feet, large joints of the lower body, and the lower back are the most common areas to be affected by PsA. Effects will be worsening over time in case of no treatment provided on time. Permanent damage occurs to joints and tissues if not treated promptly. This paper has an analysis over the recent advancement in imaging techniques such as SPECT (Single Photon Emission Computed Tomography) and FDG-PET/CT (Fluorodeoxyglucose - Positron Emission Tomography /Computed Tomography) have showed more reliable and accurate diagnosis of early stage Psoriatic Arthritis.

**Keywords:** Psoriatic arthritis; PSA; IMod; Arthritis; SPECT; FDG-PET/CT

### Introduction

Imaging techniques in radiology helps to diagnose PsA [1] in early conditions and prevents them from worsening the condition. Plain radiography is the imaging modality (IMod) that was used in early days for detection. But detection of inflammatory changes affecting soft tissue and bone marrow was difficult because of its indistinct image outcomes. Radiographic techniques can detect inflammations of PsA that typically occur in an advanced conditions, not just in synovial joints and knee joints, fibrocartilaginous joints such as sacroiliac joints [2,3], but also helpful in imaging of the ligaments and parts of entheses of tendons. Ultrasound and MRI are IMod which are advancements to the field of radiological imaging; however it has ability only to detect and measure the extent of joint damage earlier with accurate result, than with other radiographs. These IMod also provide a sensitive means of assessing for the presence of inflammation and quantify its amount. These IMod, as it has more features, it also provides the potentials for the identification of tendonitis, dactylitis and enthesitis. These features can help medical professionals to make precise diagnosis of PsA and its effects on skin. Moreover, Scintigraphy and MRI can help in the early detection and assessment of axial and sacroiliitis disease. Unambiguous visualization of inflammations in peripheral entheses, axial entheses, peripheral joints and axial joints, are the best part of MRI, which has dramatically improved the feasibility for objective monitoring and early diagnosis of the disease process in PsA. Relationships among enthesitis, synovitis and osteitis in PsA can be explained using MRI, enthesitis is the primary target of inflammation but also support SpA pattern of inflammation. So long CT also has been considered to have small role in assessment of peripheral joints and it may be useful in assessing elements of spine

disease. But in recent years CT in conjunction with special techniques, has become growing area for exploitation for its potentials in the field of diagnosis.

CT and MRI accuracies are similar to each other in valuation of erosions in sacroiliac joints and involved inflammations to improve its specificity; it is used in conjunction with PET as a hybrid method to accurately locate the region of inflammation in Psoriatic arthritis patients, at much earlier stages.

Positron emission tomography (PET) [2] is one of the non-invasive, sensitive, and quantitative imaging technique that targeting binding sites to visualizes functional tissue changes. It provides molecular data which is contrast to functional and anatomic data obtained by magnetic resonance imaging (MRI) and ultrasonography (US). Moreover, compared with other techniques in nuclear imaging like conventional scintigraphy, PET has great advantage of the high levels of sensitivity in 3-D (dimensional) mode and it has ability to quantify accurate tracer uptake and also reproductive, enable monitor of disease activity and its therapeutic effects. In mid of 1970s development of PET was started after the introduction of fluorodeoxyglucose (FDG) which is labelled as fluorine-18 (18F-FDG) [4,5]. Then in mid of 2000, three decades later, PET-computed tomography (CT) fusion gives more precise anatomic localization of the PET signal [2]. 18F-FDG is absorbed in metabolically active tissues and once it has been absorbed phosphorylation averts the glucose from escaping from the cell. 18F-FDG PET was tested by injecting it into the body to visualize inflammatory lesions and an oncologic PET scans, was carried out. This in turn revealed its capability of being absorbed in non-cancer (benign) and metabolically active lesions.

Bone scan (BS) and single photon emission computed tomography (SPECT) that uses 99mTc labelled phosphonate agents is capable of highlighting faster bone metabolism and turnover in injured bones,

which is also relatable with the injuries associated with ligaments, tendon injury and inflammatory conditions in joints as a new method for contrasting [4]. For detecting pathogenic lesions, multiple changes in bone turnover are generally interdependent to structural changes. Thus, SPECT and bone scan demonstrates good and accurate results in diagnosis of rare and benign musculoskeletal disorders. Recently, integrating SPECT and computed tomography (CT) a hybrid imaging method SPECT/CT has been developed. This method has more advantage than SPECT alone. In SPECT/CT localizing a lesion in the beginning stages is possible by using high-resolution CT [5]. Bone SPECT/CT shows higher diagnostic values than the conventional methods mentioned above.

### Radionuclide Imaging of Psoriatic Arthritis Using SPECT/CT

Study Is Made from Patient Who Suffered from Diabetic Foot syndrome, psoriatic arthritis and type 2 diabetes at the age of 67. Symptoms of inflammation were found in patient's right ankle joint. It was unclear that whether the cause of inflammation is because of psoriatic arthritis or diabetic foot syndrome. To clarify this, Scintigraphic imaging with radiolabeled white blood cells is performed. They used SPECT/CT with technetium-99m labelled WBC ( $^{99m}\text{Tc}$ -WBC) and performed the imaging at the regions on inflammation. The results of this technique made it clear that the articular space of subtalar joints are alone affected by inflammatory process. Since the patient had been diagnosed with exacerbation of psoriatic arthritis, radionuclide synovectomy can be performed. It is of vital importance to accurately differentiate between inflammatory arthritis of the foot and diabetic foot syndrome. We can come to the conclusion that with the help of radiolabeled white blood cells scintigraphic imaging using SPECT/CT gives a clear idea of further treatments of such inflammation [4,5].

### FDG-PET/CT in the Diagnosis and Monitoring of Psoriatic Arthritis

For some of the patients who suffered from psoriasis also develop joint pain. It is very difficult to decide whether the pain is caused due to psoriatic arthritis (PsA) or related inflammatory conditions. A new imaging technique known as whole body Positron Emission Tomography/Computed Tomography (PET/CT) [1,3] locate inflammation in the body by utilizing the idea of inflammatory cells that has the ability to absorb sugar. Because usually PsA patients have inflammatory cells in their tendons and joints, this kind of scan help the physician to view whole body and locate inflammation by taking a CT image [6-8]. Studies have found that few patients with psoriasis but not suffering with arthritis has inflammation in both tendons and joints even ahead of symptoms in patient. In this study, the investigators found that how good PET/CT works for assessing inflammation in PsA patients. This was studied using several patients suffering from joint pains and psoriasis at some nearby regions of skin and the results showed amazing details on how this type of radiology was able to picturize early signs of the PsA. This would be a best tool to prevent damage or pain caused due to PsA by finding and treating inflammation before it starts to spread.

A comparison of pre-treatment and post treatment (patient specific) analysis is shown for both techniques (Figures 1 and 2).

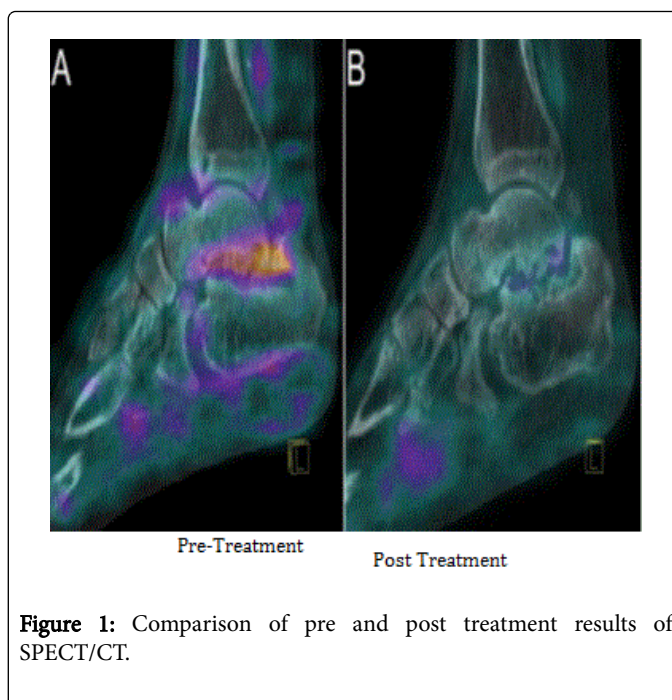


Figure 1: Comparison of pre and post treatment results of SPECT/CT.

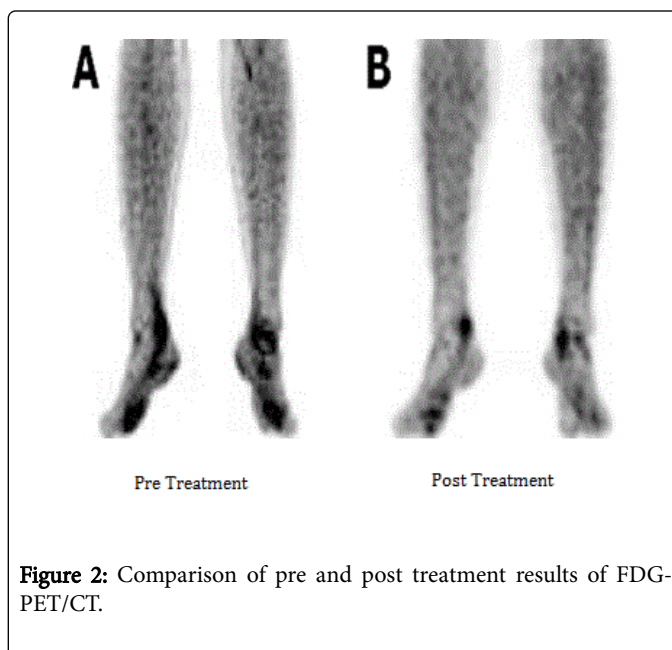


Figure 2: Comparison of pre and post treatment results of FDG-PET/CT.

### Conclusion

In this paper two different imaging techniques coupled with CT such as Single Photon Emission Computed Tomography/ Computed Tomography (SPECT/CT) and Fluorodeoxyglucose Positron Emission Tomography/Computed Tomography (PET/CT) are analyzed for the early detection of Psoriatic arthritis. The images used are ankle joints that showed inflammatory cells in their joints and tendons. The two techniques had shown more accuracy in terms of detecting the psoriatic arthritis and helps in precise differentiation of psoriatic arthritis and other inflammatory conditions.

---

## References

1. Mallbris L, Ritchlin CT, Ståhle M (2006) Metabolic disorders in patients with psoriasis and psoriatic arthritis. *Curr Rheumatol Rep* 8: 355-363.
2. <https://www.healthline.com/health/pet-scan#overview1>
3. <https://www.mayoclinic.org/diseases-conditions/bone-and-joint-infections/symptoms-causes/syc-20350755>
4. Psoriatic arthritis radiology: Imaging tests for diagnosis.
5. <https://www.ncbi.nlm.nih.gov/pmc/articles/PMC3101722/>
6. Solomon DH, Love TJ, Canning C, Schneeweiss S (2010) Risk of diabetes among patients with rheumatoid arthritis, psoriatic arthritis and psoriasis. *Ann Rheum Dis* 69: 2114-2117.
7. <http://paperity.org/p/60298120/comparison-of-spect-ct-and-mri-in-diagnosing-symptomatic-lesions-in-ankle-and-foot-pain>
8. Ha S, Hong SH, Paeng JC, Lee DY, Cheon GJ, et al. (2015) Comparison of SPECT/CT and MRI in Diagnosing Symptomatic Lesions in Ankle and Foot Pain Patients: Diagnostic Performance and Relation to Lesion Type. *PLoS ONE* 10: e0117583.