

Concurrent Central Retinal Artery and Vein Occlusion in a Pediatric Patient

Mohd Syafiq Bin Azman^{1*}, Shawarinin Binti Jusoh¹ and Akmal Haliza Binti Zamli²

¹Hospital Tengku Ampuan, Afzan, Malaysia

²Universiti Kebangsaan, Malaysia

Abstract

Purpose: To describe a rare case of combined central retinal artery (CRAO) and vein occlusion (CRVO) in pediatric patient.

Case report: We report a case of mixed right eye CRAO and CRVO in a healthy young girl. A nine-year-old child presented with right eye sudden loss of vision. Upon presentation vision was counting finger at 1 feet. Afferent pupillary defect was positive. Fundus examination revealed pre-retinal and retinal hemorrhages in all 4 quadrants with pale retina and cherry red spot. All blood test results were normal except elevated erythrocyte sedimentation rate and complement (C3, C4) level. Fluorescence angiogram revealed delayed arm to retina time, venous filling and large area of capillary fallout. Her right eye vision improved to 1/60 with intravenous steroids.

Conclusion: Combined CRAO and CRVO is possible in a healthy children. Thorough investigations should be done to sought the cause and hence proper management applied.

Keywords: Central retinal artery; Central retinal vein; Occlusion

Introduction

Combined central retinal artery (CRAO) and vein occlusion (CRVO) is a rare entity particularly in pediatric. Most of these patients have some detectable etiologic disorder. We are going to describe a case of concurrent central retinal artery and vein occlusion in a healthy paediatric patient.

Case Report

A nine-year-old girl presented to us with sudden onset painless reduced vision on her right eye (RE) for one month. There was no recent history of infection, trauma or systemic complaints. RE examination revealed a visual acuity of counting fingers at one feet. Anterior segment showed RE relative afferent pupillary defect. There was no vitritis. Fundus examination of RE revealed pre-retinal and retinal hemorrhages in all 4 quadrants with pale retina and cherry red spot (Figure 1). The left eye was normal (Figure 2). Systemic examination was normal. Several investigations including full blood count, liver

function test, autoimmune markers (Anticardiolipin, Antinuclear and Rheumatoid factor), inborn error metabolism workout and thrombophilia screening were found to be within normal limits except elevated erythrocyte sedimentation rate (ESR) and complement (C3, C4) level. Fluorescence angiogram revealed delayed arm to retina time, delayed venous filling, presence of large and small vessels vasculitis and large area of capillary fallout at posterior pole and periphery. Her RE vision improved to 1/60 after intravenous steroid and pan-retinal photocoagulation.

Discussion

Combined central retinal artery and vein occlusion is a rare entity

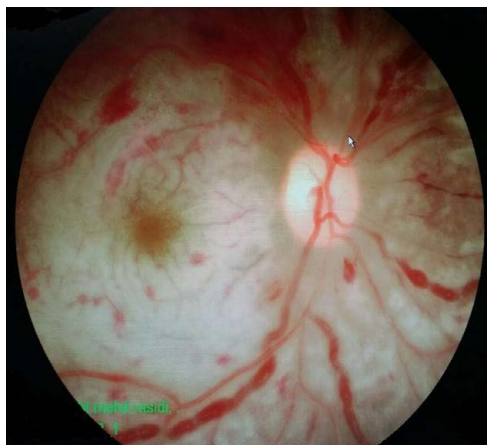


Figure 1: RE fundus photo photograph at presentation showing pre-retinal and retinal haemorrhages in all 4 quadrant concentrating on the posterior pole with pallid retinal edema, cherry red spot and dilated tortous vessels.

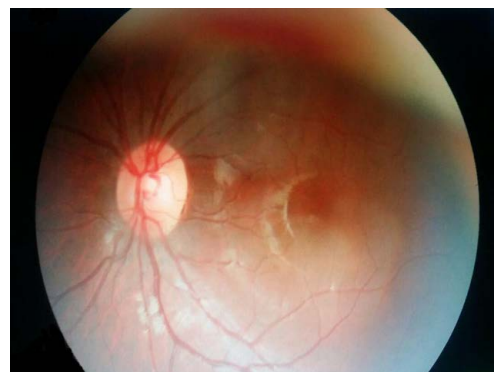


Figure 2: Normal left eye fundus.

*Corresponding author: Mohd Syafiq bin Azman, Hospital Tengku Ampuan Afzan Jalan Tanah Putih, Malaysia, Tel+ 60173129970; E-mail: drsyaqiqazman@gmail.com

Received May 18, 2017; Accepted May 29, 2017; Published June 10, 2017

Citation: Azman MSB, Jusoh SB, Zamli AHB (2017) Concurrent Central Retinal Artery and Vein Occlusion in a Pediatric Patient. Med Rep Case Stud 2: 136. doi: 10.4172/2572-5130.1000136

Copyright: © 2017 Azman MSB, et al. This is an open-access article distributed under the terms of the Creative Commons Attribution License, which permits unrestricted use, distribution, and reproduction in any medium, provided the original author and source are credited.

particularly in paediatric age group. Usually those with retinal artery or vein occlusion may have unusual systemic or ocular associations such as trauma, sickle cell hemoglobinopathies, cardiac disorders, systemic lupus erythematosus, intravenous drug use, varicella infection, Fabry's disease, neurofibromatosis type I and homocystinuria [1-6]. On average, the age of patients with retinal artery occlusion is 58.5 years [4]. It is estimated that the incidence of retinal arterial obstruction in patients under the age of 30 years has been less than 1 in 50,000 outpatients [4]. Axer-Siegel R et al reported the youngest arterial obstruction is that of a 40-day-old female neonate with shock and diffuse intravascular coagulation (DIC), who developed bilateral ophthalmic artery occlusion [7]. To date, the only reported case of combined central retinal artery and vein occlusion in paediatric age group is by Osman Saatci et al. [8]. They described a case of unilateral combined central retinal artery and vein occlusion in a fourteen-year-old boy associated with systemic non-Hodgkin's lymphoma. The diagnosis was confirmed with a supraclavicular lymph node biopsy. His vision upon presentation was no perception to light. According to authors, the occlusion was due to tumoral optic nerve involvement which was revealed on orbital magnetic resonance imaging (MRI). There are also few reported cases of idiopathic retinal artery occlusion in the paediatric age group [9-11]. All the reported cases were extensively investigated and had poor visual outcome. To our best knowledge, our case of nine-year-old girl is the first pediatric case of combined artery and vein occlusion in otherwise a healthy child.

Conclusion

This case demonstrates that combined CRAO and CRVO is possible in a healthy children. Thorough investigations should be done to sought the cause and hence proper management applied.

References

1. Wilson RS, Ruiz RS (1969) Bilateral central retinal artery occlusion in homocystinuria: A case report. *Archives of Ophthalmology* 1: 267-268.
2. Sher NA, Reiff W, Letson RD, Desnick RJ (1978) Central retinal artery occlusion complicating Fabry's disease. *Archives of Ophthalmology* 96: 815-817.
3. Brown GC, Magargal LE (1979) Sudden occlusion of the retinal and posterior choroidal circulations in a youth. *American journal of ophthalmology* 88: 690-693.
4. Brown GC, Magargal LE, Shields JA, Goldberg RE, Walsh PN, et al. (1981) Retinal arterial obstruction in children and young adults. *Ophthalmology* 88: 18-25.
5. Cho NC, Han HJ (1992) Central retinal artery occlusion after varicella. *American Journal of Ophthalmology* 114: 235-236.
6. Saatci AO, Saylam GS, Yasti ZÖ, Söylev M, Saatci I (1998) Neurofibromatosis type I and unilateral ophthalmic artery occlusion. *Ophthalmic Genetics* 19: 87-91.
7. Axer-Siegel R, Snir M, Schonfeld T, Yassur Y (1997) Bilateral central retinal artery occlusion in a neonate. *Journal of Pediatric Ophthalmology and Strabismus* 34: 249-251.
8. Saatci AO, Düzovali Ö, Özbek Z, Saatci I, Sarialioglu F, et al. (1998) Combined central retinal artery and vein occlusion in a child with systemic non-Hodgkin's lymphoma. *International Ophthalmology* 22: 125-127.
9. Heckler LV, Lederer DE, Alwadani F, Koenekoop RK (2008) Idiopathic central retinal artery occlusion in a 6-year-old. *Canadian Journal of Ophthalmology/ Journal Canadien d'Ophtalmologie* 43: 375-376.
10. Lee WB, Pearson PA, Moreman K (2002) Central retinal artery occlusion and disc edema in a child. *Journal of American Association for Pediatric Ophthalmology and Strabismus* 6: 264-265.
11. Sebban AI, Sullivan TJ, Davison MB (1996) Branch retinal artery occlusion in a child. *Australian and New Zealand Journal of Ophthalmology* 24: 283-286.