

Co-Existence of Relapsing Remitting Multiple Sclerosis and HLA B27 Positive Ankylosing Spondylitis in a Malay Male: A Rare Occurrence

Viswanathan S* and Kamil MKM

Department of Neurology, Hospital Kuala Lumpur, Jalan Pahang, Kuala Lumpur, MY 50586, Malaysia

*Corresponding author: Viswanathan S, Department of Neurology, Hospital Kuala Lumpur, Jalan Pahang, Kuala Lumpur, MY 50586, Malaysia, Tel: 60176800529; E-mail: shivenda70@yahoo.com

Received date: February 27, 2017; Accepted date: March 23, 2017; Published date: March 30, 2017

Copyright: © 2017 Viswanathan S, et al. This is an open-access article distributed under the terms of the Creative Commons Attribution License, which permits unrestricted use, distribution, and reproduction in any medium, provided the original author and source are credited.

Abstract

Ankylosing spondylitis (AS) and multiple sclerosis (MS) are two different chronic inflammatory autoimmune conditions with unclear etiopathogenesis. One is a rheumatological disorder while the other is a neurological one. Current literature on an association between these two conditions is limited. Furthermore, early recognition of potential cases with both conditions co-existing is important as there have been very rare reports on the occurrence of demyelinating diseases or unmasking of latent MS in patients with ankylosing spondylitis treated with anti-TNF α . This has important therapeutic implications for patients at such risk.

Introduction

Herein, we report the very rare occurrence of relapsing remitting MS in a 34 year old male Malay patient with HLA-B27 positive ankylosing spondylitis, multiple white matter lesions in the brain and spinal cord fulfilling Mc Donalds neuroimaging criteria for MS with cerebrospinal fluid oligoclonal band positivity. Initially thought to be an event triggered by anti-TNF α treatment, however following subsequent relapse of cervical myelitis post initiation of interferon beta at 9 months requiring intravenous steroids helped to further consolidate the diagnosis of relapsing remitting MS. Therefore, the occurrence of MS here is as an independent entity associated with Ankylosing spondylitis which may occur infrequently. High index of suspicion and careful exclusion of other mimickers is important as are future studies to elucidate the relationship between these two diseases.

Case Report

Mr E, a 34 year old man initially presented with intermittent unrelenting joint pains over the right knee, hips, lower back and right shoulder since 13 years of age. Xrays of the spine and sacroiliac joints were suggestive of a diagnosis of ankylosing spondylitis. HLA-B27 tests done were positive. Initially he was treated with analgesics, namely non-steroidal anti-inflammatory agents as well as cox-2 inhibitors. However, he continued to have severe multiple joint pains involving both knees, hips, back, ankles and toes associated with joint swellings. So in March 2012, he received one dose of subcutaneous (SC) Adalimumab. In the same year, the patient was referred to another rheumatology centre and started on oral sulphasalazine 500 mg BD.

In December 2013, twenty one months after adalimumab, he started to have numbness over both the feet resulting in unsteadiness of gait and later urinary incontinence. This first episode failed to resolve completely. Following a period of clinical quiescence, in January 2015,

he presented with difficulty in walking and standing due to worsening in unsteadiness of gait. This was associated with right leg weakness. Initially, he did not seek any treatment. In March 2015, he was reviewed by his rheumatologist who thought the symptoms could be due to the back pain associated with AS and he received a single dose of subcutaneous Etanercept. However, in the absence of improvement he was referred to a neurologist.

Neurological examination revealed an alert, oriented gentleman with saccadic eye movements and bilateral temporal pallor of optic discs. There was also bilateral internuclear ophthalmoplegia. The tone in both the lower limbs was increased. The strength of the right upper and lower extremities was 4+/5 while the left upper and lower extremities were 5/5 with globally brisk reflexes. The patient also showed mild unsteadiness on tandem walking. Kurtzke Expanded disability status scale score was 4.0.

Axial and coronal brain magnetic resonance imaging (MRI) showed dissemination in space made up of multiple foci on T2WI in keeping with deep cerebral white matter hyperintensities of the brainstem, periventricular and juxtacortical regions involving both the cerebral hemispheres suggestive of a demyelinating disease process (Figure 1). The MRI of the spine showed patchy intramedullary lesions from C3 to C6, T2 and T5 vertebral levels. Visual evoked potentials (VEPs) were within normal limits. Blood tests for connective tissue disease and sarcoidosis were all negative. CSF analysis yielded normal protein and glucose levels, acellular with normal level of immunoglobulin G index with positive oligoclonal bands. The patient was diagnosed with MS and given a 5 day course of intravenous methylprednisolone. He was then commenced on disease modifying therapy (DMT's) made up of Interferon Beta 1b 250 mcg EOD and symptomatic treatment for lower limb spasticity consisting of baclofen 10 mg TDS. After another relapse of right lower limb weakness due to a new cervical 6 and 7 myelitis he was upgraded to Fingolimod 0.5 mg OD and has remained relapse free.

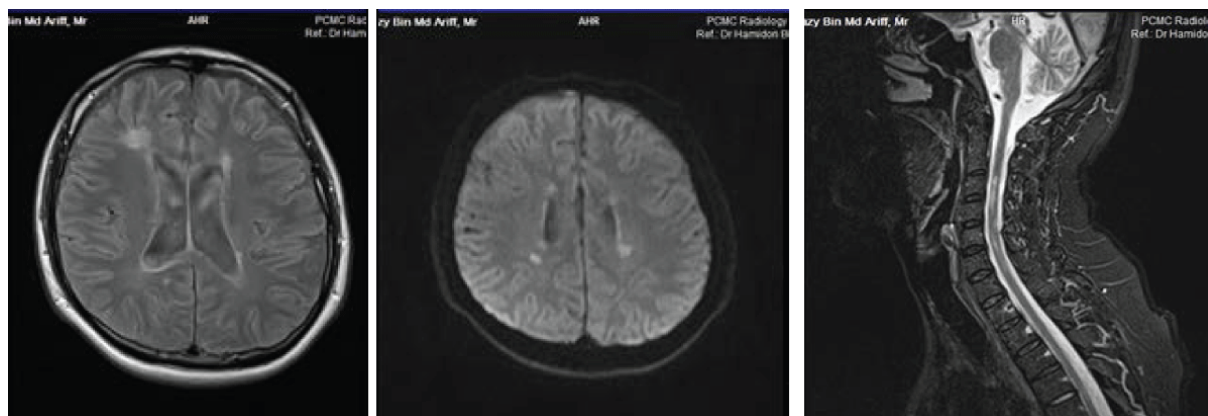


Figure 1: MRI brain shows subcortical white matter periventricular lesions showing dissemination in space on axial Flair MRI of the brain. Sagittal view MRI of the spine showing a spinal cord lesion over the cervical and thoracic cord.

Discussion

We report a patient with coexisting HLA-B27 positive AS and MS. We also review the literature on the association between these two conditions. AS and MS are both chronic autoimmune mediated inflammatory diseases associated with significant disability. MS is relatively rare in Malaysia with a prevalence of 3.23 per 100,00 population [1]. The prevalence of AS here is uncertain.

Both AS and MS share unclear etiopathogenesis. Both are characterized by an initial inflammatory phase and immune mediated tissue specific attacks. The inflammatory phase in MS is followed by predominantly axonal degeneration and myelin sheath damage, while in AS by degenerative phenomena and new bone formation. A number of AS patients with possible or definite MS have been reported in the literature but the association of both diseases is still considered to be rare [2-5].

In 1986, Pillay and Hunter reported increased incidence of abnormal evoked potentials in patients with underlying AS. In their study of 16 AS patients who were subjected to VEP studies, all except for 2 were found to be normal [6]. Similarly, abnormalities of brainstem auditory evoked potentials (BAEP) in patients with AS were reported by other authors [7]. However, the significance of the abnormal evoked potentials in patients with AS needs to be interpreted with caution in the absence of clinical and neuroimaging findings typical of Multiple Sclerosis.

Hanrahan et al. in 1988 investigated the radiological evidence of AS in a series of 20 HLA-B 27 positive MS patients and reported that 5 cases fit the criteria for MS as did Mignarri et al who reported a single case in a HLA-B27 positive patient very similar in presentation to ours [8-10]. Furthermore, Libbrecht and de Bleeker reviewed 10 cases of concomitant AS and MS. Four of them were definite MS and the others had either probable MS (monophasic myelopathy) or MS-like syndromes [4].

Nevertheless, a number of studies have shown that in the absence of definitive epidemiological studies, the increased frequency of the co-existence of AS and MS has yet to be proven conclusively. Whitman and Khan, in 1989 postulated that AS and MS was associated with certain HLA antigens in the West. Unfortunately, there exists a great degree of heterogeneity, geographical and racial variance with these

disorders thus creating difficulty in identifying specific ones for both [8]. In all the reported cases, AS preceded the first sign of MS. The majority of these cases had relapsing remitting MS. This is similarly demonstrated in our index case wherein HLA B27 positive AS was diagnosed first followed by clinically definite RRMS. Additionally, in all the literature we reviewed, all the MS patients coexisting with AS were shown to be HLA B27 positive as exhibited by our case though this clinical significance is uncertain. Thus, the association between MS and AS is complex.

Another issue worth considering here is the possibility of adalimumab inducing demyelination of the central nervous system as there are a number of case reports of anti tumor necrosis factor antagonists (antiTNF α) producing neurological complications post treatment for ankylosing spondylitis. However, in this case the temporal relationship between the anti TNF α and the occurrence of newly diagnosed MS is unlikely as only one dose was given whereas in most literature reviewed patients had multiple courses for months. Furthermore, in the majority of the reports there is resolution of the demyelinating symptoms upon withdrawal of adalimumab and as such this association particularly in this case is highly debatable and unlikely as patient had only partial resolution of symptoms and continued to relapse with attack related disabilities.

In summary, this case is unique as it is the first reported case of a Malay male with both MS and AS which thus far has not been reported. We believe vigorous future studies will bring us to the answer of the association between AS and MS [9-15].

Acknowledgement

We thank the Director General of Health of Malaysia for allowing us to publish this article as part of output from the demyelinating diseases database.

Informed consent: The patient consented to the publication of this case report and use of images to support the manuscript.

References

1. Viswanathan S (2016) Ministry of Health Data from the Demyelinating diseases registry at Kuala Lumpur Hospital. Hospital Based data, Malaysia.

2. Tan FU, Tellioğlu S, Aydin G, Erdemoğlu AK, Keleş I (2004) Ankylosing spondylitis and multiple sclerosis in an HLA-B27 negative patient. *Acta Neurol Belg* 104: 169-172.
3. Calin A (1989) Ankylosing spondylitis Philadelphia. Saunders 1021-1037.
4. Libbrecht N, De Bleecker J (1999) Ankylosing spondylitis and multiple sclerosis. *Acta Clin Belg* 54: 30-32.
5. Lourbopoulos A, Ioannidis P, Boura E, Antoniadis D, Karacostas D, et al. (2013) Coexistence of multiple sclerosis and ankylosing spondylitis: Report of two cases. *Eur Neurol* 70: 149-154.
6. Pillay N, Hunter T (1986) Delayed evoked potentials in patients with ankylosing spondylitis. *J Rheumatol* 13: 137-141.
7. Iulia GS, Daniela MT, Elena Rezus, Cristian DP (2015) Brainstem auditory evoked potentials findings in ankylosing spondylitis. *Romanian Journal of Neurology* 14: 3.
8. Whitman GJ, Khan MA (1989) Unusual occurrence of ankylosing spondylitis and multiple sclerosis in a black patient. *Cleve Clin J Med* 56: 819-822.
9. Hanrahan PS, Russell AS, McLean DR (1988) Ankylosing spondylitis and multiple sclerosis: an apparent association? *J Rheumatol* 15: 1512-1514.
10. Mignarri A, Dotti MT, Battisti C, Vallone I, Federico A (2009) Occurrence of ankylosing spondylitis and multiple sclerosis-like syndrome in a HLA-B27 positive patient. *Neurol Sci* 30: 329-332.
11. Polman CH, Reingold SC, Banwell B, Clanet M, Cohen JA, et al. (2011) Diagnostic criteria for multiple sclerosis: 2010 revisions to the McDonald criteria. *Ann Neurol* 69: 292-302.
12. Borman P, Tuncay F, Kaya M, Ergun U, Inan L (2011) Coexistence of ankylosing spondylitis and multiple sclerosis. *Acta Neurol Belg* 111: 340-343.
13. Thomas DJ, Kendall MJ, Whitfield AG (1974) Nervous System Involvement in Ankylosing Spondylitis *Br Med J* 1: 148-150.
14. van der Linden S, Valkenburg HA, Cats A (1984) Evaluation of diagnostic criteria for ankylosing spondylitis. A proposal for modification of the New York criteria. *Arthritis Rheum* 27: 361-368.
15. Andreadou E, Kemanetzoglou E, Brokalaki Ch, Evangelopoulos ME, Kilidireas C, et al. (2013) Demyelinating disease following anti TNF? Treatment: A causal or coincidental association? Report of four cases and review of literature. *Case Rep Neurol Med* 13: 671935.