

## Clinical Image: Carcinoid Syndrome

Peela T, Krishna M\*, Varghese B and Galagali A

Department of Surgery, Armed Forces Medical College, Pune, India

**Keywords:** Carcinoid; Facial flushing; Chemotherapy

### Case History

A 21-yr-old female, presented with history of painful lump in right upper quadrant of abdomen with diarrhea and facial flushing (Figure 1) of 15 days duration. There was no associated vomiting, jaundice, melena, headache or any respiratory complaints. On examination, she had hepatomegaly extending 7cm below right costal margin. All routine hematological and biochemical values were normal except for elevated S. Lipase levels. On further evaluation, USG showed multiple hypochoic lesions in liver and tail of pancreas which was corroborated with CECT findings of multiple discrete hypo-enhancing lesions in both lobes of liver and tail of pancreas abutting left lobe of liver with loss of fat plane (Figures 2 and 3). The clinical picture and imaging raised a suspicion of neuroendocrine tumour of pancreas with liver metastasis. Biochemical markers in form of Serum chromogranin was also raised however urinary 5-HIAA levels were within normal limits. Presently, patient is undergoing chemotherapy as a case of metastatic pancreatic neuroendocrine tumour (NET).

NET of pancreas is classified as functional and non-functional. Carcinoid of pancreas are extremely rare amounting to 0.73% of all carcinoid tumours [1]. Carcinoid syndrome is usually caused due to extensive liver metastasis causing release of vasoactive substances



Figure 1: Female presented facial flushing.

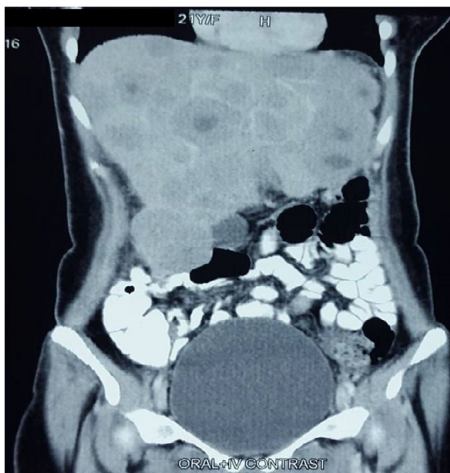


Figure 2: USG showed multiple hypochoic lesions in liver and tail of pancreas.

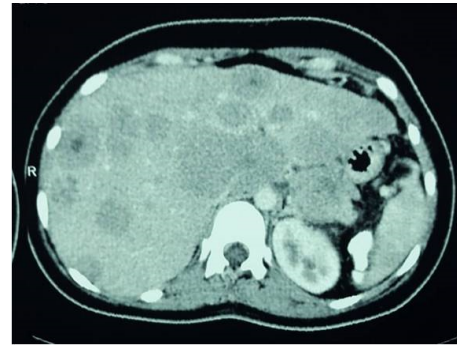


Figure 3: CECT findings of multiple discrete hypo-enhancing lesions in both lobes of liver and tail of pancreas showed multiple hypochoic lesions in liver and tail of pancreas. male presented facial flushing.

into systemic circulation. The presenting features include flushing, diarrhea and occasionally bronchospasm. The possibility of a cure in these patients is directly related to an early diagnosis. For the tumours limited to the pancreas and no evidence of distant metastases, a radical resection with lymphadenectomy may be curative [2].

### References

1. Modlin IM, Lye KD, Kidd M (2003) A 5-decade analysis of 13,715 carcinoid tumors. *Cancer* 97: 934-959.
2. Saint-Marc O, Cogliandolo A, Pozzo A, Pidoto R (2004) A primary pancreatic carcinoid tumour with unusual clinical complaints: A case report. *World Journal of Surgical Oncology* 2(1): 1-4.

\*Corresponding author: Krishna M, Department of Surgery, Armed Forces Medical College, Pune-411040, India, Tel: 91-8411066008; E-mail: [murali276@yahoo.com](mailto:murali276@yahoo.com)

Received: December 03, 2016; Accepted: December 05, 2016; Published: December 08, 2016

Citation: Peela T, Krishna M, Varghese B, Galagali A (2016) Clinical Image: Carcinoid Syndrome. *Oncol Cancer Case Rep* 2: i102.

Copyright: © 2016 Peela T, et al. This is an open-access article distributed under the terms of the Creative Commons Attribution License, which permits unrestricted use, distribution, and reproduction in any medium, provided the original author and source are credited.