

Breast Cancer in SCD Patient: A Case Report and Literature Review

Entisar Al-Zaman^{1*}, Aysha S. ALZaman², Yahya AlZaman³

¹ Department of Obstetrics and Gynecology, Salmaniya Medical Complex, Kingdom of Bahrain

² Department of Hematology-oncology, Salmaniya Medical Complex, Kingdom of Bahrain

³ Department of Internal Medicine, Bahrain Defence Force Hospital, Kingdom of Bahrain

Corresponding Author*

Entisar Al-Zaman

Department of Obstetrics and Gynecology, Salmaniya Medical Complex, Kingdom of Bahrain

E-mail: drayshazaman1@gmail.com

Copyright: ©2024 Al-Zaman, E. This is an open-access article distributed under the terms of the Creative Commons Attribution License CC-BY, which permits unrestricted use, distribution, and reproduction in any medium, provided the original author and source are credited.

Received: 03-Jul-2024, Manuscript No. OCCRS-24-101250; **Editor assigned:** 18-Jul-2024, PreQC No. OCCRS-24-101250 (PQ); **Reviewed:** 20-Jul-2024, QC No. OCCRS-24-101250 (Q); **Revised:** 23-Jul-2024, Manuscript No. OCCRS-24-101250 (R); **Published:** 28-Jul-2024. doi: 10.35248/24.10.02.001-002

Abstract

Background: Malignancies have been often reported among patients with Sickle Cell Disease (SCD), with breast cancer being the most common cancer among females. However, the data available thus far in the literature on the safety of oncological treatments in patients with Sickle Cell Disease (SCD) especially that they are more prone to develop serious and even life-threatening treatment-related complications, is very limited.

Case report: Here, we report a case of a 48-year-old woman with SCD who presented with metastatic Human Epidermal Growth Factor Receptor 2 (HER2) positive breast cancer and was treated accordingly with 3 weekly pertuzumab, trastuzumab anti-HER2 monoclonal antibodies and weekly paclitaxel 80 mg/m² days one, eight, and 15 as per the standard regimen for metastatic breast cancer.

Unfortunately, the patient developed severe acute chest syndrome during the second cycle following the trastuzumab infusion requiring ICU admission; therefore, the anti-HER2 monoclonal antibody treatment was permanently discontinued. However, the patient successfully completed her paclitaxel chemotherapy cycles as planned. Furthermore, unlike trastuzumab, the patient tolerated lapatinib a tyrosine kinase inhibitor against the cytoplasmic domain of HER2 without any serious complications.

Conclusion: Anti-HER 2 monoclonal antibodies namely Trastuzumab and pertuzumab can precipitate acute chest syndrome in SCD patients with breast cancer.

Keywords: Breast cancer • Trastuzumab • Sickle cell anemia • Chemotherapy • Human epidermal growth factor receptors

Introduction

Malignancies have been reported in patients with sickle cell disease SCD [1,2]. Although SCD in itself does not increase the risk of cancer, but also does not confer any protection [3]. Although SCD patients are prone to numerous complications and adverse events, the data available in the literature thus far on the safety of oncological treatments in patients with sickle cell disease is limited [4]. The introduction of hydroxyl urea has led to a marked reduction in mortality among SCD patients and this increase in patient survival has resulted in an increased incidence of malignancies including breast cancer among SCD patients [5]. However, treating breast cancer in patients with SCD presents unique challenges for clinicians.

Case Presentation

A 58-year-old woman with a known case of SCD, who was previously on hydroxy urea but stopped it during the COVID-19 pandemic, presented with a fixed hard mass in the left breast associated with bilateral axillary lymphadenopathy. Her mammography showed bilateral malignant-looking breast lesions as follows:

Pleomorphic micro-calcifications with a mass lesion occupying most of the central left breast, 9.2 cm x 6.4 cm in size, involving the nipple (Figure 1). The right breast also showed pleomorphic microcalcification with an extension to the nipple measuring 7.8 cm x 6.4 cm, along with bilateral axillary lymph node infiltration (Figure 2).

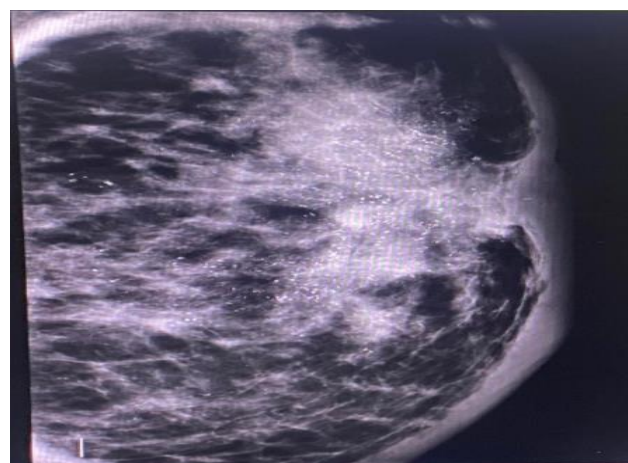


Figure 1. A Mammogram of the left breast showed pleomorphic micro-calcification with a mass lesion occupying the central left breast measuring 9.2x6.4 cm and extending to the nipple

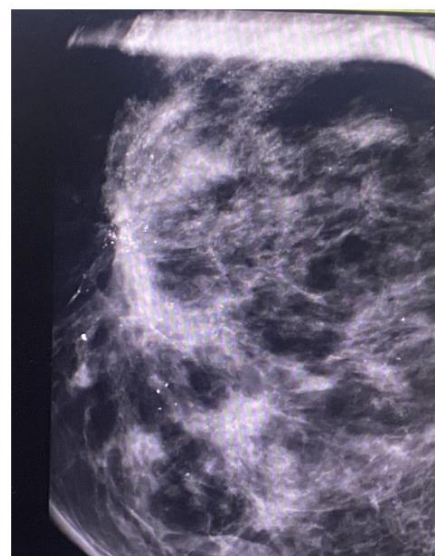


Figure 2. A Mammogram of the right breast showed pleomorphic microcalcification with an extension to the nipple measuring 7.8 cm x 6.4 cm

The tru-cut biopsies from both breasts were consistent with invasive ductal carcinoma of the breast. The immunohistochemistry however showed

different Hormonal Receptor (HR) and human epidermal growth factor receptor (HER2) statuses as follows:

- Left breast invasive ductal carcinoma, Grade III, cT4 N1, Oestrogen Receptor (ER) and Progesterone Receptor (PR) both negative, but HER2 positive
- Right breast invasive ductal carcinoma, Grade II, cT1(m) N1, both ER and PR positive, but HER2 negative.
- Her positron emission Tomography-Computed Tomography (PET CT) scans unfortunately confirmed liver metastasis. Therefore, the patient was treated with the standard protocol of a combination of paclitaxel (Taxol) chemotherapy with anti-HER2 receptor monoclonal antibodies namely trastuzumab and pertuzumab [1].
- Her baseline hemoglobin (Hb) was around 10 gm/dL. The patient was kept well hydrated pre- and post-chemotherapy.

Result

The first cycle was given over two days as per protocol, with pertuzumab only on Day 1 (D1) and trastuzumab and paclitaxel on D2. This went smoothly with only mild itching and chest discomfort during Herceptin infusion, which was not associated with desaturation and was treated as per protocol guidelines by transiently stopping the infusion and then re-challenging with a slower infusion rate. Steroids and anti-histamine were also given to cover any possibility of an infusion reaction that can mimic such symptoms. Prophylactic steroids were also administered prior to subsequent cycles to reduce any chances of reactions. The patient managed to receive week 2 and 3 Taxol treatments without any complication but developed acute chest pain after the administration of the second cycle of Herceptin due to a drop-in oxygen saturation to 88%, and on examination, she was found to have bilateral crepitation. Accordingly, the patient had an Electrocardiogram (ECG) and Echo to rule out Herceptin induced cardiotoxicity, the result of both of which were normal.

Chest X-ray showed a bilateral infiltrate associated with mild left-sided pleural effusion. This was confirmed on CT, which showed newly developed multiple bilateral ground glass nodules, likely inflammatory in nature, and ruled out pulmonary embolism. The results of the septic work-up and blood cultures were all negative. The patient was shifted to the ICU, where she was kept on a high concentration of oxygen and broad-spectrum antibiotics, and also underwent an exchange transfusion. Fortunately, the patient was successfully discharged after spending one month in the hospital.

Given the life-threatening complication the patient experienced, it was decided to permanently discontinue the treatment with anti-HER2 monoclonal antibodies. However, she managed to complete her weekly Taxol chemotherapy as planned. The patient was also restarted on hydroxy urea with the aim to optimize her SCD condition in order to be re-challenged with another anti-HER2 medication with a different mechanism of action, namely lapatinib (TYKERB) a tyrosine kinase inhibitor that blocks the HER2 cytoplasmic domain in view of HER2 positivity and the aggressiveness of the tumor. Fortunately, the patient tolerated TYKERB very well which was given in combination with the hormonal treatment [6].

Discussion

Despite the rarity of data regarding cancer in SCD patients, a wide range of complications have been described with different systematic anti-cancer

drugs ranging from mild vaso-occlusive crises to serious life-threatening complications such as acute chest syndrome, thromboembolism, and multi-organ failure [7]. Moreover, the same drug can have different safety profiles in different populations [8]. The variation in the safety profiles of anti-cancer drugs in SCD is partly due to the unique chemical structures and components of each drug. However, sometimes it is the solvent and not the active ingredient that precipitates the complication, explaining why the same drug can cause a complication in some patients but not in others [7]. Another important mechanism is through the polymorphisms in genes regulating individual drug metabolism and the Fetal Hemoglobin (HbF) expression metabolism.

The patient developed acute chest syndrome when administered anti-HER2 monoclonal antibodies, but she tolerated TYKERB, a HER2 Tyrosine kinase inhibitor [8], well, which again illustrates that the mechanism of action is another important point to be considered when treating SCD patients with cancer, and highlights the need for proper randomized control trial to be inclusive of such groups of patients.

Conclusion

We here report the case of an SCD patient who developed acute chest syndrome after receiving trastuzumab monoclonal antibodies. With the current lack of high-quality prospective evidence, a registry of sickle cell patients diagnosed with cancer can be a very useful tool in choosing a safe treatment regimen for such a critical group of patients.

References

1. Seidman, A. D., et al. "Randomized phase III trial of weekly compared with every-3-weeks paclitaxel for metastatic breast cancer, with trastuzumab for all HER-2 overexpressors and random assignment to trastuzumab or not in HER-2 nonoverexpressors: final results of Cancer and Leu." *J Clin Oncol* 26.10 (2008): 1642-1649.
2. Dawkins, F. W., et al. "Cancer incidence rate and mortality rate in sickle cell disease patients at Howard University Hospital: 1986–1995." *Am J Hematol* 55.4 (1997): 188-192.
3. Chauhan, S. I. M. A., et al. "Incidence of hematological malignancies in sickle cell patients from an Indian tertiary care teaching hospital." *Asian J Pharm Clin Res* 11.3 (2018): 205-209.
4. Al Zaman, A. S. "Breast cancer in patients with sickle cell disease can be treated safely with weekly paclitaxel." *Saudi Medical Journal* 34.2 (2013): 199-201.
5. Yanni, E., et al. "Trends in pediatric sickle cell disease-related mortality in the United States, 1983-2002." *J Pediatr* 154.4 (2009): 541-545.
6. Johnston, S. RD, et al. "Phase III, randomized study of dual human epidermal growth factor receptor 2 (HER2) blockade with lapatinib plus trastuzumab in combination with an aromatase inhibitor in postmenopausal women with HER2-positive, hormone receptor-positive metastatic breast." *J Clin Oncol* 36.8 (2018): 741.
7. Swede, H., et al. "Adverse events in cancer patients with sickle cell trait or disease." *Genet Med* 17.3 (2015): 237-241.
8. Wilson, N. M., et al. "Paclitaxel-induced sickle cell crisis." *Am J Health Syst Pharm* 65.14 (2008): 1333-1336.