

Brainstem Midline Assessed by Transcranial Sonography in Parkinson's Disease: Further Evidence of a Different Etiopathogenesis of Alexithymia and Depression

Roberta Di Giacomo^{1,2*}, Vincenzo D'Agostino³, Maria Vittoria De Angelis², Francesco Cerritelli¹, Luciano Paolo Marchionno², Maria Chiara D'Amico¹, Astrid Thomas¹, Marco Onofri^{1,2}, Laura Bonanni^{1,2}

¹Department of Neuroscience, Imaging and Clinical Sciences, University G.d'Annunzio of Chieti-Pescara, Italy

²Neurology Clinic, SS Annunziata Hospital, Chieti, Italy

³University of Tor Vergata, Faculty of Letters and Philosophy, Department of History, Roma, Italy

*Corresponding author: Roberta Di Giacomo, Department of Neuroscience, Imaging and Clinical Sciences, University G.d'Annunzio of Chieti-Pescara, Italy, Tel: 390871562019; E-mail: roberta.digiaco84@gmail.com

Received date: July 20, 2017; Accepted date: August 29, 2017; Published date: August 31, 2017

Copyright: © 2017 Di Giacomo R, et al. This is an open-access article distributed under the terms of the Creative Commons Attribution License, which permits unrestricted use, distribution, and reproduction in any medium, provided the original author and source are credited.

Abstract

Objective: Parkinson's disease (PD) is often characterized by altered emotional processing, such as depression and alexithymia. Alexithymic and depressive symptoms may be partially overlapping and the relative independence of these two disorders is strongly debated. Reduced echogenicity of midbrain raphe, evaluated with transcranial sonography (TCS), is a characteristic finding in depression associated with PD. No data are available on brainstem's echogenicity in alexithymic PD patients. We assessed, by means of transcranial sonography, possible differences between PD patient with or without alexithymia and/or depression.

Methods: We recruited 22 PD patients among our local cohort of 200 patients referred to our Movement Disorder Center during 2014. All patients were treated with optimal dose of dopaminomimetic (L-DOPA EQ mg 499.7 ± 256.3) and underwent neuropsychological tests including Beck Depression Inventory (BDI) and Toronto Alexithymia Scale-20 (TAS-20). Motor symptoms were assessed with Unified Parkinson's Disease Rating Scale (UPDRS III) and modified Hoehn and Yahr scale (H&Y). TCS was performed, through temporal window, using a color-coded phased-array ultrasound system (SONOS 7500), to evaluate midbrain raphe (0=absent, 1=discontinuous, 2=continuous).

Results: TAS-20 and BDI identified 4 patients with depression without alexithymic symptoms (18.18%), 7 alexithymic patients without depression (31.82%), 5 PD patients with depression and alexithymia (22.73%) and 6 PD patients without any of the two disorders (27.27%). At statistical analysis hypoechogenicity correlated with BDI score and the presence of alexithymia was not significantly correlated with absent or discontinuous raphe.

Conclusion: The study evidenced the presence of hypoechogenicity in the midbrain raphe in PD patient with depression. No alteration of midbrain raphe was found in PD patients with alexithymia. These findings suggest that while depression in PD may involve central component of brainstem midline, constituting the basal limbic system, called mesocorticolimbic pathway, alteration in alexithymia does not affect the midbrain. This study provides further evidence that depression and alexithymia are independent affective disorder.

Keywords: Midbrain sonography; Parkinson's disease; Alexithymia; Depression; Echogenicity of midbrain raphe

Abbreviations PD: Parkinson's Disease; TCS: Transcranial Sonography; BDI: Beck Depression Inventory; TAS-20: Toronto Alexithymia Scale-20; UPDRS: Unified Parkinson's Disease Rating Scale; mH&Y: Modified Hoehn and Yahr Scale; MMSE: Mini-Mental State Examination; LED: L-Dopa Equivalent Dose; D: Depression, A: Alexithymia

Introduction

Parkinson's disease (PD) is often characterized by altered emotional processing. Depression occurs with a prevalence of 30-35% in medicated PD patients and alexithymia with a prevalence of 21% in PD patients [1,2].

Salient features of alexithymia are the inability to distinguish one's feelings from the associated bodily sensations with a tendency to amplify the somatic sensations accompanying emotional arousal, the inability to communicate feelings to others and an externally oriented cognitive style, reflecting reduced inner thoughts and fantasies [3].

Alexithymic and depressive symptoms may be partially overlapping and the relative independence of the two disorders is strongly debated [2-5]. Previous studies show that alexithymic features may be relevant in PD patients and may be associated with the severity of depression [2], but depressive symptoms do not completely explain the difficulty in describing and communicating emotions in this group of patients.

Both depression and alexithymia seem to find their pathophysiological correlate in limbic system dysfunction.

Depression has been associated to morphological alterations of the midbrain raphe [6,7].

A tool to assess the anatomy of the midbrain raphe is transcranial sonography (TCS). This allows a 2D visualization of brain parenchyma [6].

Reduced echogenicity of midbrain raphe, evaluated with TCS, is a characteristic finding in depression associated with PD [7-10]. No data are available on brainstem's echogenicity in alexithymic patients.

In the present study, we aimed to disentangle the possible pathogenetic background of alexithymia and depression, by evaluating, by means of TCS, a group of PD patients with depression in comparison with a group of PD patients with alexithymia and with a group of PD patients without any of the two symptoms.

Materials and Methods

We recruited 22 consecutive PD patients, among a local cohort of 200 patients referred to our institution during 2014. All patients gave their written informed consent to participate and fulfilled research diagnostic criteria for idiopathic PD (UK Brain Bank Criteria [11]).

All the patients were treated with optimal dose of dopaminomimetics. The global cognitive status was assessed with the Mini-Mental State Examination (MMSE). The presence and severity of depression was assessed by Beck Depression Inventory (BDI) which classifies depressive symptoms as mild mood disturbance (score from 11 to 16), borderline clinical depression (score 17-20), moderate depression (score 21-30), severe depression (score 31-40), extreme depression (score over 40).

The Toronto Alexithymia Scale-20 (TAS-20) was also administered. TAS-20 is the most widely used and validated self-administered alexithymia scale [12]. It includes three subscales (F1 difficulty identifying feelings, F2 difficulty describing feelings and F3 difficulty focusing on inner affective experience). Total scores categorize patients as non alexithymic (scores<51), borderline alexithymic (scores from 51 to 60) and alexithymic (scores>=61) [12].

Motor symptoms were assessed with Unified Parkinson's Disease Rating Scale (UPDRS III) [13] and modified Hoehn and Yahr scale (mH&Y) [14].

TCS was performed by an experienced and certified ultrasound physician (RDG) using a color-coded phased-array ultrasound system (SONOS 7500). Patient lied in supine position; the ultrasound probe was pressed on the temporal window, at the temporal squama before the ear as recommended else-where [15]. Axial plane on orbitomeatal line was assessed to evaluate midbrain raphe [16]. A dynamic range of 45 dB, image brightness and time-gain compensation were adapted as needed for each examination. Echogenicity of the brainstem midline was rated in comparison with the echogenicity of the tectum of the mesencephalus and classified as grade 0=absent, 1=discontinuous, 2=continuous [8,15] (Figure 1A example of absent raphe, Figure 1B example of continuous raphe). Grade 0 and grade 1 are classified as hypoechoic. Continuous echogenicity of the raphe is the normal finding in the general population [8-10]. Neuropsychological tests and TCS were performed and analysed in different settings and by examiners blind to diagnosis of depression/alexithymia.

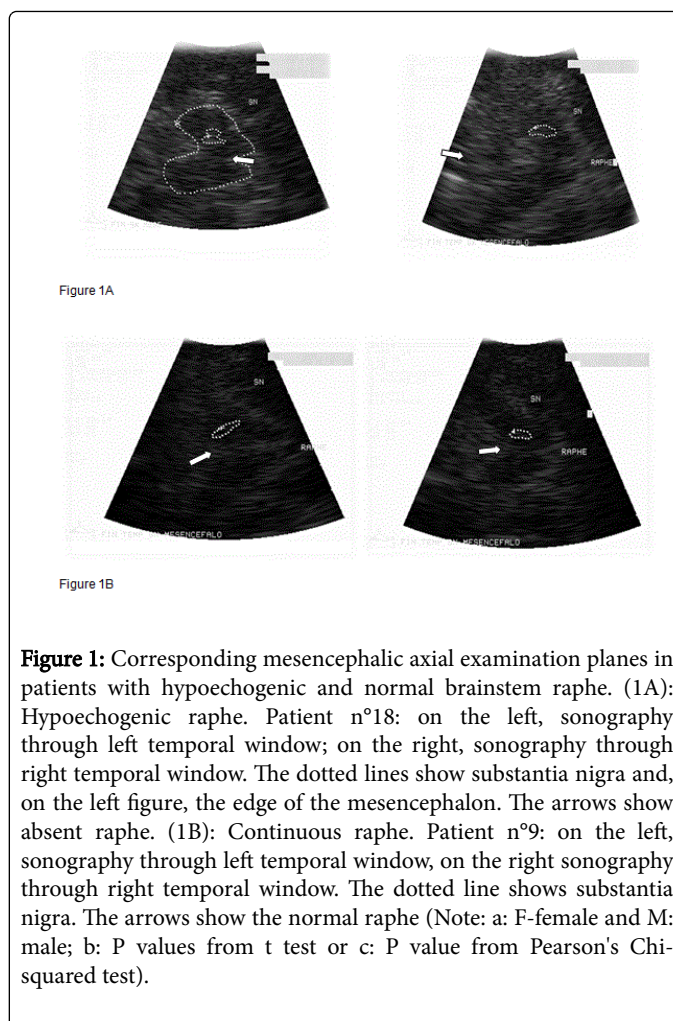


Figure 1: Corresponding mesencephalic axial examination planes in patients with hypoechoic and normal brainstem raphe. (1A): Hypoechoic raphe. Patient n°18: on the left, sonography through left temporal window; on the right, sonography through right temporal window. The dotted lines show substantia nigra and, on the left figure, the edge of the mesencephalon. The arrows show absent raphe. (1B): Continuous raphe. Patient n°9: on the left, sonography through left temporal window, on the right sonography through right temporal window. The dotted line shows substantia nigra. The arrows show the normal raphe (Note: a: F-female and M: male; b: P values from t test or c: P value from Pearson's Chi-squared test).

Exclusion criteria included cognitive impairment suspected on the basis of MMSE \leq 25 and clinical examination, evidence of severe psychotic symptoms or systemic diseases, features suggestive of atypical Parkinsonism, modifications of the antiparkinsonian pharmacological treatment in the last 3 months and insufficient quality of the bone windows.

Statistical Analysis

Arithmetic mean, standard deviation, percentage, range were used. Binary data was compared using the χ^2 test. One-factorial analysis of variance (ANOVA) with the main factors group was conducted to test the difference in variance among the four groups having defined an alfa level less than 0.05. Ordinal data were analyzed using Kruskal-Wallis test with post hoc Bonferroni-Dunn correction was used to manage multiple comparisons. In addition, bivariate Pearson's Correlation was used to explore correlation between echogenicity and neuropsychological results (TAS-20 and BDI).

The statistical software used was R (v. 3.3.2). Results were expressed in terms of point estimate and 95% of confidence interval (CI). Statistical significance was set at $p < 0.05$.

Results

Demographic, clinical and pharmacological findings, neuropsychological and TCS results are reported in Table 1 and compared in Table 2.

Patient	Gender	aLED(mg)	bUPDRS (III)	Antipsychotic/ Antidepressant Drugs	Age (years)	Education (years)	Disease Duration (years)	cmH&Y	dMMSE	eBDI	fTAS20	Raphé	Disease-Group (PD-A, PD-DA, PD-D, PD)
1	M	300	13	NO	76	13	1	2.5	28,3	4	54	2	PD-A
2	M	550	15	NO	78	5	6	2.5	25,7	6	52	2	PD-A
3	M	352	16	NO	66	13	1	1.5	26,2	5	55	2	PD-A
4	F	300	11	NO	52	13	3	1	30	8	56	2	PD-A
5	F	105	11	NO	64	5	1	1	30	3	51	2	PD-A
6	M	100	26	NO	69	18	2	2	27,2	2	56	1	PD-A
7	F	675	19	NO	73	5	5	2	26,3	7	65	2	PD-A
8	F	575	31	NO	76	4	5	2.5	27,7	7	35	0	PD
9	F	510	18	NO	58	13	5	2	28	9	46	2	PD
10	M	715	24	NO	62	13	10	2	30	7	46	2	PD
11	F	507	9	NO	58	16	4	2	30	10	47	0	PD
12	F	400	17	NO	61	8	5	2	30	8	45	2	PD
13	M	885	13	NO	64	13	14	2	29	5	46	2	PD
14	F	510	15	NO	56	16	2	1	30	23	50	0	PD-D
15	M	750	27	YES	80	5	6	2	25,4	15	50	1	PD-D
16	F	785	33	NO	76	4	24	3	27	13	43	1	PD-D
17	M	400	16	YES	70	5	14	2	26,3	12	37	2	PD-D
18	M	415	47	NO	55	18	4	2.5	30	23	53	0	PD-DA
19	M	1180	23	NO	58	8	9	2	30	12	54	0	PD-DA
20	M	380	33	YES	57	13	1	2.5	30	15	63	1	PD-DA
21	F	300	10	YES	48	8	3	2.5	28	21	81	0	PD-DA
22	M	300	22	NO	68	8	1	2	25	16	57	1	PD-DA

Table 1: Demographic and clinical findings. Neuropsychological and transcranial sonography results (Note: a: L-DOPA equivalent dose; b: Unified Parkinson's Disease Rating Scale motor section III; c: modified Hoehn and Yahr scale; d: Mini-Mental State Examination; e: Beck Depression Inventory; f: Toronto Alexithymia Scale-20; g: PD-A: PD patients with alexithymia; h: PD-DA: PD patients with depression and alexithymia; i: PD-D: PD patients with depression; l: PD: PD patients without depression and/oralexithymia).

	PD (n=6)	PD-D (n=4)	PD-A (n=7)	PD-DA (n=5)	p-value b	f-value
Age (Mean ± SD)	63.17 ± 6.71	70.50 ± 10.50	68.29 ± 8.81	57.20 ± 7.19	0.09	2.54
Gender (M:F)a	02:04	02:02	04:03	04:01	0.15c	-
Disease duration (Mean ± SD)	7.17 ± 3.97	11.50 ± 9.71	2.71 ± 2.06	3.60 ± 3.29	0.05	3.232

LED (Mean ± SD)	598.67 ± 174.25	611.25 186.47 ±	340.29 ± 213.11	515.00 ± 375.13	0.23	1.581
Education (Mean ± SD)	11.17 ± 4.36	7.50 ± 5.69	10.29 ± 5.25	11.00 ± 4.47	0.67	0.522
UPDRS (Mean ± SD)	18.67 ± 7.87	22.75 ± 8.73	15.86 ± 5.30	27.00 ± 13.84	0.21	1.639
mH&Y (Mean ± SD)	2.08 ± 0.20	2.00 ± 0.82	1.79 ± 0.64	2.30 ± 0.27	0.43	0.974
MMSE (Mean ± SD)	29.12 ± 1.06	27.18 ± 1.99	27.67 ± 1.80	28.60 ± 2.19	0.31	1.282

Table 2: Comparison of demographic and clinical characteristics among different disease groups.

Among 22 patients, TAS-20 (cut-off value 51) and BDI (cut-off value 11) identified 4 patients with depression without alexithymic symptoms (PD-D) (18.18%), 7 alexithymic patients without depression (PD-A) (31.82%), 5 PD patients with depression and alexithymia (PD-DA) (22.73%) and 6 PD patients without any of the two disorders (PD) (27.27%).

Three PD-D and 5 PD-DA patients showed the presence of hypoechogenicity in the midbrain raphe: hypoechogenicity correlated with BDI score (Pearson's Correlation: $t=-3.9103$, $df=20$, $p<0.001$). Among 7 PD-A patient's only one showed discontinuous raphe and no one showed absent raphe. At statistical analysis, the presence of alexithymia was not significantly correlated with absent or discontinuous raphe (Pearson's Correlation: $t=-0.67542$, $df=20$, $p=0.507$). Two patients of 6 PD patients without depression or alexithymia had absent raphe, one of these showed BDI score equal to 10 and clinical features of depression.

Among demographic characteristics, only disease duration was different between PD-D and PD-A groups. This finding should not affect our observation, because age, disease severity (mH&Y, LED) and clinical features (UPDRS) of the patients were no different. In addition, echogenicity of midbrain structures seems to remain constant over time [17].

Discussion and Conclusion

In the present study, we found a different TCS pattern in PD patients with depression as compared to PD patients with Alexithymia.

We confirmed the presence of hypoechogenicity in the midbrain raphe in PD patient with depression. This alteration may be due to a distinct disruption of fibre tracts and raphe nuclei of the brainstem in depressed patients, as highlighted by neuropathological [18] and MRI findings [6].

In contrast, no alterations of midbrain raphe were found in alexithymic PD patients.

Previous research has generated controversy as to whether alexithymia and depression are distinct or overlapping constructs [4,19,20]. The disentanglement of the two disorders is important because alexithymic patients do not seem to respond satisfactorily to antidepressants and should be directed to psychotherapies involving specific techniques to enhance emotional awareness and integrate symbolic and subsymbolic elements of emotion schemas [21,22]. On the other hand, patients with hypoechogenic raphe seem to respond better to selective serotonin reuptake inhibitor (SSRI) therapy than those with normal echogenicity [23].

Our findings confirmed that depression and alexithymia in PD may recognize different mechanisms. Depression seems to involve central component of brainstem midline, constituting the mesocorticolimbic pathway and involving, mainly, serotonergic system. On the other hand, the presence of alexithymia is not associated with midbrain alterations. This latter result found a significant positive confirmation in several studies, which showed that alexithymia may involve mainly cortical dysfunctions [24-26]. In a recent work evaluating the default mode network (DMN) in alexithymic patients, a higher connectivity was found within right prefrontal and sensory areas. These areas have been associated with emotion suppression and a more action-oriented behavior. Furthermore, the alexithymic group showed reduced connectivity within the frontal areas of the DMN, which could be related to the reduced emotional awareness of alexithymic patients [27].

Furthermore, we note that depressed mood occurs with a prevalence of 40% and alexithymic symptoms were present with a prevalence of 54.55% in our sample. These values were higher than reported in the literature [1,2]. This can be due to the small sample size or to the fact that, at difference with previous reports [2], we included, in the prevalence evaluation, also slightly symptomatic patients (borderline alexithymic patients and mild depressed mood).

The main limitations of our study are the small sample size of patients tested and the semi-quantitative analysis of signal intensity. Moreover, despite we are supported by the abundant literature about consistency of TCS technique [6-8,28], the reliability of this technique is dependent on the quality of the ultrasonography system and on the qualification of the investigator.

In conclusion, the brainstem midline echogenicity would be highly interesting to perform in the future to disentangle these two disorders and, toward this aim, study on non-parkinsonian subjects with and without alexithymia is advisable.

References

1. Ishihara L, Brayne C (2006) A systematic review of depression and mental illness preceding Parkinson's disease. *Acta Neurol Scand* 113: 211-220.
2. Costa A, Peppe A, Carlesimo GA, Pasqualetti P, Caltagirone C (2006) Alexithymia in Parkinson's disease is related to severity of depressive symptoms. *Eur J Neurol* 13: 836-841.
3. Taylor GJ, Bagby RM, Parker JD (1991) The alexithymia construct. A potential paradigm for psychosomatic medicine. *Psychosomatics* 32: 153-164.
4. Parker JD, Bagby RM, Taylor GJ (1991) Alexithymia and depression: Distinct or overlapping constructs? *Compr Psychiatry* 32: 387-394.

5. Todarello O, Porcelli P, Bellomo A, Nardini M (2004) Alexithymia and depression. Comparison of different measures. *Rivista di Psichiatria* 39: 6.
6. Becker G, Berg D, Lesch KP, Becker T (2001) Basal limbic system alteration in major depression: A hypothesis supported by transcranial sonography and MRI findings. *Int J Neuropsychopharmacol* 4: 21-31.
7. Krogias C, Walter U (2016) Transcranial sonography findings in depression in association with psychiatric and neurologic diseases: A review. *J Neuroimaging* 26: 257-263.
8. Berg D, Supprian T, Hofmann E, Zeiler B, Jäger A (1999) Depression in Parkinson's disease: Brainstem midline alteration on transcranial sonography and magnetic resonance imaging. *J Neurol* 246: 1186-1193.
9. Zhang YC, Hu H, Luo WF, Sheng YJ, Chen XF, et al. (2016) Alteration of brainstem raphe measured by transcranial sonography in depression patients with or without Parkinson's disease. *Neurol Sci J* 37: 45-50.
10. Stanković I, Stefanova E, Žiropadja L, Mijajlović M, Pavlović A, et al. (2015) Transcranial midbrain sonography and depressive symptoms in patients with Parkinson's disease. *J Neurol* 262: 689-695.
11. Jankovic J (2008) Parkinson's disease: Clinical features and diagnosis. *J Neurol Neurosurg Psychiatry* 79: 368-376.
12. Bagby RM, Taylor GJ, Parker JD, Dickens SE (2006) The development of the Toronto structured interview for alexithymia: Item selection, factor structure, reliability and concurrent validity. *Psychother Psychosom* 75: 25-39.
13. Fahn S, Elton RL (1987) Members of the Unified Parkinson's Disease Rating Scale Development Committee. Unified Parkinson's disease rating scale. In: Fahn S, Marsden CD, Calne DB, Goldstein M, editors: *Recent development in Parkinson's disease*, Vol. 2 Florham Park, New Jersey: Macmillan Healthcare Information, pp: 153-164.
14. Hoehn MM, Yahr MD (1967) Parkinsonism: Onset, progression and mortality. *Neurology* 17: 427-442.
15. Walter U, Behnke S, Eyding J, Niehaus L, Postert T, et al. (2007) Transcranial brain parenchyma sonography in movement disorders: State of the art. *Ultrasound Med Biol* 33: 15-25.
16. Bogdahn U, Becker G, Winkler J, Greiner K, Perez J, et al. (1990) Transcranial color-coded real-time sonography in adults. *Stroke* 21: 1680-1688.
17. Iranzo A, Stockner H, Serradell M, Seppi K, Valldeoriola F, et al. (2014) Five-year follow-up of substantia nigra echogenicity in idiopathic REM sleep behavior disorder. *Mov Disord* 29: 1774-1180.
18. Baumann B, Danos P, Krell D, Diekmann S, Wurthmann C, et al. (1999) Unipolar-bipolar dichotomy of mood disorders is supported by noradrenergic brainstem system morphology. *J Affect Disord* 54: 217-224.
19. Rief W, Heuser J, Fichter MM (1996) What does the Toronto Alexithymia Scale TAS-R measure? *J Clin Psychol* 52: 423-429.
20. Luminet O, Bagby RM, Taylor GJ (2001) An evaluation of the absolute and relative stability of alexithymia in patients with major depression. *Psychother Psychosom* 70: 254-260.
21. Taylor GJ (2000) Recent developments in alexithymia theory and research. *Can J Psychiatry* 45: 134-142.
22. Stingl M, Bausch S, Walter B, Kagerer S, Leichsenring F, et al. (2008) Effects of inpatient psychotherapy on the stability of alexithymia characteristics. *J Psychosom Res* 65: 173-180.
23. Walter U, Prudente-Morrissey L, Herpertz SC, Benecke R, Hoepfner J (2007) Relationship of brainstem raphe echogenicity and clinical findings in depressive states. *Psychiatry Res* 155: 67-73.
24. Berthoz S, Artiges E, van-de-Moortele PF, Poline JB, Rouquette S, et al. (2002) Effect of impaired recognition and expression of emotions on frontocingulate cortices: An fMRI study of men with alexithymia. *Am J Psychiatry* 159: 961-967.
25. Kano M, Fukudo S, Gyoba J, Kamachi M, Tagawa M, et al. (2003) Specific brain processing of facial expressions in people with alexithymia: An H2 15O-PET study. *Brain* 126: 1474-1484.
26. Gündel H, López-Sala A, Ceballos-Baumann AO, Deus J, Cardoner N, et al. (2004) Alexithymia correlates with the size of the right anterior cingulate. *Psychosom Med* 66: 132-140.
27. Liemburg EJ, Swart M, Bruggeman R, Kortekaas R, Knegtering H, et al. (2012) Altered resting state connectivity of the default mode network in alexithymia. *Soc Cogn Affect Neurosci* 7: 660-666.
28. Pilotto A, Yilmaz R, Berg D (2015) Developments in the role of transcranial sonography for the differential diagnosis of parkinsonism. *Curr Neurol Neurosci Rep* 15: 43.