

Case Report

Open Access

# Blink Reflex Usefulness in Acute Phase of Bickerstaff's Brainstem Encephalitis

Maria Antonia Albertí, Christian Homedes, Valentina Vélez, Mónica Povedano, Jordi Montero and Carlos Casasnovas\*

Neuromuscular Unit Neurology Department, University Hospital of Bellvitge, Hospitalet de Llobregat, Barcelona, Spain

\*Corresponding author: Carlos Casasnovas, Neuromuscular Unit Neurology Department, University Hospital of Bellvitge, Hospitalet de Llobregat, Barcelona, Spain, Tel: 34932607711; E-mail: [carloscasasnovas@bellvitgehospital.cat](mailto:carloscasasnovas@bellvitgehospital.cat)

Received date: October 17, 2017; Accepted date: October 24, 2017; Published date: October 29, 2017

Copyright: © 2017 Albertí MA, et al. This is an open-access article distributed under the terms of the Creative Commons Attribution License, which permits unrestricted use, distribution, and reproduction in any medium, provided the original author and source are credited.

## Abstract

Bickerstaff's brainstem encephalitis (BBE) is a Fisher Syndrome (FS) related disorder characterized by the disturbance of consciousness or hyperreflexia in addition to the classical triad of ataxia, areflexia and ophthalmoplegia. The pathophysiology of BBE remains controversial therefore a complete neurophysiological study including the study of cranial nerves may be crucial to add evidence of peripheral or central nervous system involvement in the assessment of patients. We report the case of 29 years old woman with BBE and the blink reflex (BR) follow up studies revealing a correlation between clinical and electrophysiological improvement. This case may support the usefulness of BR studies for electrophysiological diagnosis in BBE in early stages.

**Keywords:** Bickerstaff's brainstem encephalitis; Fisher syndrome; Brainstem encephalitis; Blink reflex; EMG

## Introduction

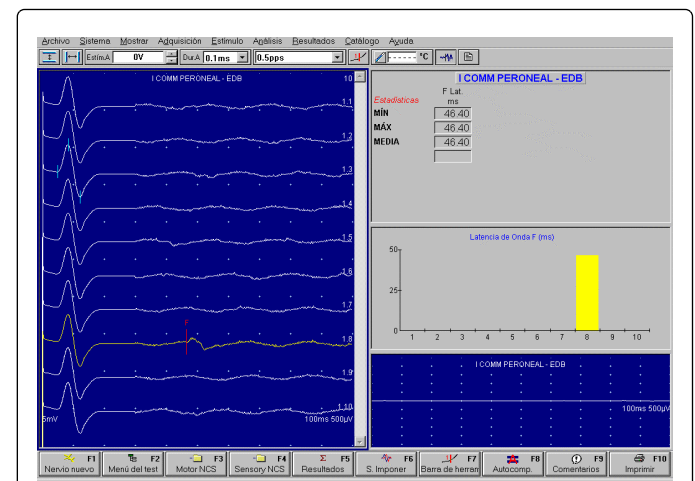
Fisher syndrome (FS) is characterized by the triad of ataxia, areflexia and ophthalmoplegia, with minimal if any limb weakness. Bickerstaff's brainstem encephalitis (BBE) is a related disorder characterized by the disturbance of consciousness or hyperreflexia in addition to the classical triad and share with FS the association with anti-GQ1b antibodies [1-3]. The pathophysiology and the main lesion site in BBE is a matter of debate. Most authors describe a variable involvement of the peripheral and central nervous systems (PNS and CNS) in FS and BBE suggesting a continuous spectrum of disease between them [3-5]. Performing early and serial neurophysiological studies would be crucial in establishing the underlying pathology in both entities [6,7]. Specifically, the inclusion of study of facial nerve and Blink reflex (BR) in the neurophysiological study performed may add evidence of peripheral or central nervous system involvement useful to support the diagnosis, especially in its early stages [7].

We present a case of BBE with very early blink reflex electrophysiological findings that were crucial for explaining the physiopathology of the disease and can help with its topographic diagnosis.

## Case Report

A 29 years old and previously healthy woman was admitted to neurology department because of a 24 h evolution of gait disturbance, diplopia and numbness in hands and feet. Four weeks ago, the patient presented diarrhoea and abdominal pain for 3 days. General examination revealed 39°C axillar temperatures. Neurological examination (Day 1 after onset) showed consciousness disturbance (she was drowsy but able to respond to commands), complete external ophthalmoplegia, her pupils were equal and with no response to photomotor reflex, bilateral facial palsy, aphonia, discrete left hemiparesis (grade 4+), left babinski, ataxic gait and complete

areflexia. Laboratory findings were normal and antibodies against gangliosides (including Gq1b) were negative. Cerebrospinal fluid (CSF) revealed the presence of 70 cells (99% multinuclear cells) with protein and glucose level in the normal range. CSF cultures ruled out other encephalitis aetiologies. Brain MRI did not show any abnormality. Nerve conduction studies (NCS) showed normal compound muscle action potential (CMAP) and distal latencies of all the explored motor nerves (both medians, ulnars and peroneals), blocked F-waves in left peroneal nerve (Figure 1) and clearly increased latency (61 ms) of R2 compound of right blink reflex (BR) with normal R1 latency (Figure 2a). The patient underwent endovenous immunoglobulin treatment.

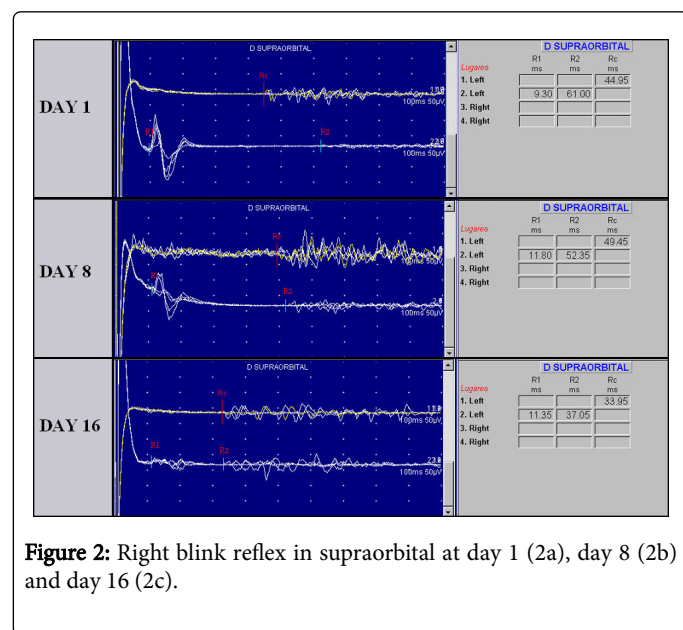


**Figure 1:** Day 1: Blocked F at left peroneal nerve.

In day 8 the patient began improving her external ocular motor motility and right BR revealed a less increased of R2 latency and a minimal increased R1 compound latency (Figure 2b), the other electrophysiological findings were normal, including F-waves of left



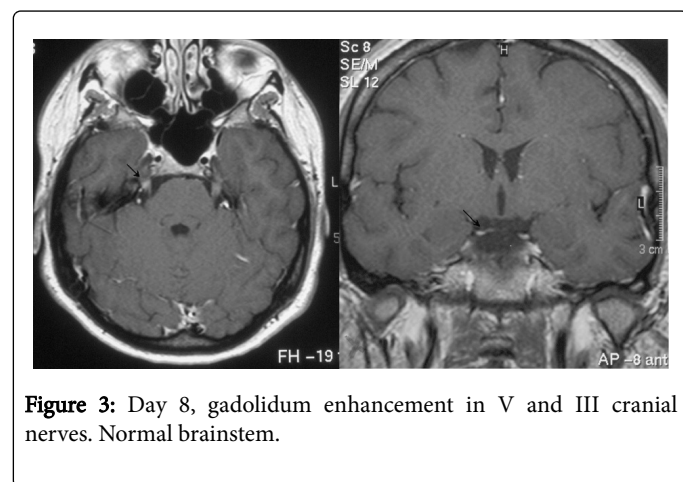
peroneal nerve. In 16 day, the patient presented partial facial bilateral palsy and ophthalmoparesis.



**Figure 2:** Right blink reflex in supraorbital at day 1 (2a), day 8 (2b) and day 16 (2c).

A second brain MRI showed gadolinium enhancement in both III and V cranial nerves and no brainstem abnormality (Figure 3). Blink reflex was normal (Figure 2c) and NCS reveals a decreased CMAP of facial nerve, the other NCS and F-waves studies were normal. No abnormalities were found at any moment in needle electromyographic studies.

In day 28, she was discharged from the hospital with mild ophthalmoparesis and facial nerve palsy, generalized areflexia and no gait disturbance. In day 70 neurological examinations was normal and NCS did not show any abnormality.



**Figure 3:** Day 8, gadolinium enhancement in V and III cranial nerves. Normal brainstem.

## Discussion

This case shows the typical BBE clinical findings areflexia, ataxia, ophthalmoparesis and central nervous system signs involvement (left

pyramidal signs and consciousness disturbance) associated to pleocytosis in CSF. The electrophysiological findings suggest both peripheral (F-waves block and facial CMAP decreased) and central (increased right R2 latency with normal R1 latency) nervous system involvement. The brain MRI findings suggest an inflammatory process in III and V cranial nerves added. Antibodies against ganglioside Gq1b were negatives, and this can occur in 30% of BBE [3].

## Discussion

In our patient the presence of increased R2 latency despite normal R1 during the ophthalmoparesis consistent with a laterobulbar brainstem involvement, helping to add evidence of central nervous system involvement for the diagnosis of BBE in early evaluation and with normal CNS imaging. Ogawara et al. described a case of BBE with positive antibodies against Gq1b antibodies and absence of R2 compound in blink reflex in day 6 of initial clinics, suggesting nervous system involvement [5]. This absence was transient and blink reflex was normal in day 40.

Serial studies of our patient, showed a normalization of BR study in correlation with clinical improvement.

## Conclusion

This case report supports the usefulness of cranial nerve studies including BR in the understanding of the BBE's pathophysiology and diagnosis, especially in very early stages, and also during the evolution of the disease.

## References

1. Bickerstaff ER (1957) Brain-stem encephalitis: Further observations on a grave syndrome with a benign prognosis. *Br Med J* 5032: 1384-1387.
2. Odaka M, Yuki N, Hirata K (2001) Anti-GQ1b IgG antibody syndrome: Clinical and immunological range. *J Neurol Neurosurg Psychiatry* 70: 50-55.
3. Odaka M, Yuki N, Yamada M, Koga M, Takemi T, et al. (2003) Bickerstaff's brainstem encephalitis: clinical features of 62 cases and a subgroup associated with Guillain-Barré syndrome. *Brain* 126: 2279-2290.
4. Ito M, Kuwabara S, Odaka M, Misawa S, Koga M, et al. (2008) Bickerstaff's brainstem encephalitis and Fisher syndrome form a continuous spectrum: Clinical analysis of 581 cases. *J Neurol* 255: 674-682.
5. Ogawara K, Kuwabara S, Yuki N (2008) Fisher syndrome or Bickerstaff brainstem encephalitis? Anti-GQ1b IgG antibody syndrome involving both the peripheral and central nervous systems. *Muscle Nerve* 26: 845-849.
6. Shahrizaila N, Goh KJ, Kokubun N, Abdullah S, Yuki N (2011) Serial nerve conduction studies provide insight into the pathophysiology of Guillain-Barré and Fisher syndromes. *J Neurol Sci* 309: 26-30.
7. Alberti MA, Povedano M, Montero J, Casanovas C (2017) Early electrophysiological findings in Fisher-Bickerstaff syndrome. *Neurologia*. Epub ahead of print, p: 6.