Journal of Neurology & Neurophysiology

Babi et al., J Neurol Neurophysiol 2016, 7:1
DOI: 10.4172/2155-9562.1000349

Case Report Open Access

Bilateral Borderzone Infarcts in Hypereosinophilic Leukemia without Proximal Vessel Stenosis

M Alain Babi[1,2]*, Salman Al Jerdi[1] and Mark Gorman[1]

[1]*Department of Neurological Sciences, University of Vermont College of Medicine, Burlington, Vermont 05405, USA*

[2]*Division of Neuro-critical care, Department of Neurology, Duke University Hospital, Durham NC 27713, USA*

***Corresponding author:** M Alain Babi, Duke University Hospital DUMC 2900 Durham, NC 27710, USA, Tel: (802) 777 2880; Fax: 802-847-5690; E-mail: ncc.babi@gmail.com

Received date: Dec 21, 2015; **Accepted date:** Jan 19, 2016; **Published date:** Jan 26, 2016

Copyright: © 2016 Babi MA, et al. This is an open-access article distributed under the terms of the Creative Commons Attribution License, which permits unrestricted use, distribution, and reproduction in any medium, provided the original author and source are credited.

Abstract

Objective: We describe border-zone territory infarctions without evident hypotension or vascular stenoses in a case of hypereosinophilic syndrome (HES). We review the spectrum of neurological changes associated with HES and explore about its relationship with the observed infarction pattern.

Methods: This is a case report. A PubMed literature search was conducted searching clinico-radiographic findings of neurological complications associated with HES.

Results: A previously healthy 47 year old man presented with progressive encephalopathy, weight loss and general malaise over three weeks. MRI head revealed bilateral hemispheric watershed infarcts at the junction of the anterior and posterior circulations. No intracranial or extracranial vascular stenoses were found and cardiac evaluation via transesophageal echocardiography, telemetry, and cardiac computed tomography (CT revealed no clear cardiac source of emboli. Persistently elevated eosinophil (>5,000/ µL) led to a bone marrow biopsy and diagnosis of eosinophilic leukemia with CHIC-2 mutation. Treatment with Imatinib and high dose prednisone was undertaken with significant clinical improvement.

Conclusion: This case highlights a very rare cause of bilateral watershed cerebral infarction in non-hemodynamic stenoses. We hypothesize that the particular pattern of infarct observed in this setting may be explained on the basis of the lower capacity of hypoperfused vessel (borderzone) to eliminate emboli related to in situ-thrombosis from degranulation of eosinophils: "Impaired Wash-Out Theory".

Keywords: Stroke; Hyperesinophilia; Infarct; Watershed stroke; Embolism

Abbreviations

EEG: Electroencephalopathy; MRI: Magnetic Resonance Imaging; HES: Hypereasinophilic Syndrome; CHE: Chronic Hypereasinophilic Leukemia; TCD: Transcranial Doppler; CK-MB: Creatinine-Kinase MB fraction; ANA: Anti-nuclear Antibody; ANCA: Anti-Neutrophil Cytoplastic Antibody; SPEP: Serum Protein Electrophoresis; Anti-SSA/SSB Autoantibodies: Anti-Sjögren's-Syndrome-Related Antigen A/ Anti-Sjögren's-Syndrome-Related Antigen B; CNS: Central Nervous System; PNS: Peripheral Nervous System

Introduction

Hypereasinophilic Syndromes (HES) are a heterogeneous group of disorders characterized by sustained overproduction of eosinophils, in which eosinophilic infiltration and mediators may result in multiple organ damage [1-3]. Chronic Hypereasinophilic leukemia (CHE) is one of the syndromes associated with chronic hypereosinophilia. It is characterized by clonal proliferation of eosinophils.

The neurological complications of HES and CHE are varied; and may include cerebral thromboemboli, intracranial hemorrhage, encephalopathy, peripheral neuropathy, and cerebral venous thrombosis [2-5]. Cerebral thromboemboli may arise from intracardiac thrombi or in situ intracranial vascular thrombosis. Magnetic resonance imaging (MRI) can reveal multiple infarcts in multiple vascular territories or watershed border zone distribution [4,6,7]. Encephalopathy can present with behavioral changes, confusion, change in personality and ataxia. Affected patients may have signs of upper motor neuron disease as well as frontal release signs [3,8,9]. Encephalopathic changes have observed with markedly elevated eosinophil numbers and may derive from the toxic mediators of eosinophils [2,5]. Peripheral neuropathy accounts for approximately one-half of all the neurological manifestations of HES. The pattern of neuropathy may be symmetric, asymmetric, sensory, motor, or of mixed pattern. Mononeuritis multiplex or radiculopathy with denervation muscle atrophy have also been reported [2,9]. The prognosis of HES depends on the primary etiology, but features that portend a better prognosis include the absence of cardiac or neurological involvement, lower eosinophilic count and steroid responsiveness [2,10-12].

In this report, we describe the case of a patient with hypereosinophilia secondary to CHE, who presented with rapidly progressive encephalopathy, myocardial infarction, skin lesions, and bilateral borderzone pattern of cerebral infarction. We review the literature through a PubMed® search regarding the relationship of hypereasinophilia and observed neurological symptoms, and explore a potential mechanism of hypereasinophilia-related borderzone pattern of infarction. We alert the treating physicians to recognize this illness as a rare cause of watershed pattern of cerebral infarction without proximal vessel stenosis, and the myriad neurological manifestations which CHE can present.

Citation: Babi MA, Al Jerdi S, Gorman M (2016) Bilateral Borderzone Infarcts in Hypereosinophilic Leukemia without Proximal Vessel Stenosis. J Neurol Neurophysiol 7: 349. doi:10.4172/2155-9562.1000349

Case Report

A 47 year-old man without significant medical history presented with overt functional decline and progressive confusion over the course of two weeks. He was disoriented, inattentive, with markedly impaired short-term memory, difficulty following complex commands and poor insight into his condition. Multiple non-blanching skin lesions were observed in his lower extremities. Neurological examination was intact save for sensory testing: impaired vibration, light touch, and temperature in his distal lower extremities. He needed 1-person assist to ambulate. Limited motor strength testing given patient's ability to cooperate; was nevertheless relatively symmetric.

Contrast-enhanced cranial magnetic resonance imaging (MRI) revealed bi-hemispheric borderzone-pattern cerebral infarctions (Figure 1). Catheter angiography demonstrated patent intracranial/extracranial vasculature without vasculitic changes. Lumbar puncture was normal. Electroencephalography revealed diffuse non-specific slowing (5-7 Hz) throughout without electrographic seizures recorded.

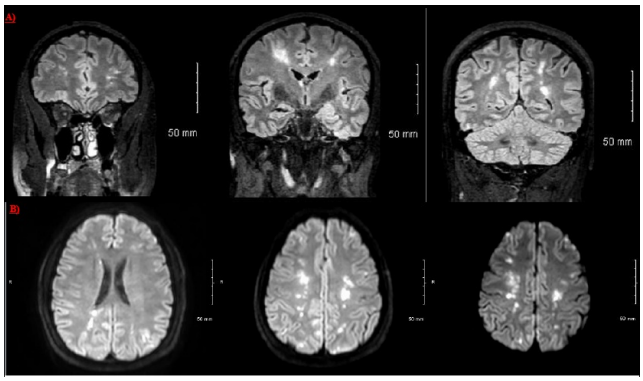

Figure 1: (A) Magnetic resonance imaging (MRI), T2-flair (1 week post clinical syndrome onset), coronal section with classical watershed appearances T2-changes in both ACA/MCA and MCA/PCA borderzone territories. Noted watershed ischemic changes (subacute) in bilateral borderzone regions (ACA/MCA and PCA/PCA); consistent with bilateral watershed cerebral infarction. Left to right: anterior to posterior. **(B)** MRI brain imaging, Diffusion-restricted (DWI) across the watershed regions (anterior/posterior watershed). Noted watershed ischemic changes (subacute) in bilateral watershed zones (MCA/ACA) and PCA/MCA borderzone region; consistent with bilateral watershed cerebral infarcts. Left to right: Caudal to rostral

Electrocardiogram was normal and ten days of telemetry revealed no serious cardiac arrhythmias. Transesophageal echocardiography found preserved left ventricular ejection fraction, no evidence of valvular dysfunction, any cardiac source of thrombi, or patent foramen ovale. Gated MRI of the heart was normal.

Initial vitals on admission were notable for a blood pressure (BP 130/70), heart rate (HR) of 110 bpm. Oxygen saturation was >99% on room air. Respiratory rate (RR) was 20/minute and non-labored. Lab work-up on admission revealed normal electrolytes, renal and liver function tests (including ammonia). Hemoglobin A1c and thyroid function tests were normal. Troponin I was elevated at 0.619 with normal CK-MB. Comprehensive toxicology screen was negative. C-reactive protein (3.9 mg/dL) and sedimentation rate (30 mm/hr) were elevated. Immunoglobulin screen, ANA, ANCA, complements, SSA/SSB were all negative.

White blood cell count was elevated at 14.99 K with 47.0% eosinophils (7.04 K/mm^3), Platelets (203 K/mm^3), hemoglobin (13.2 gm/dL), with a normal MCV (91 fl). Coagulation profile, dilute viper venom time, B2 glycoprotein 1 and cardiolipin antibodies were all within normal values. Serum viscosity and SPEP were normal, but tryptase was elevated at 29.3 ng/mL. Infectious work-up including cultures and antibody screens for parasites were unrevealing.

Bone marrow biopsy was hypercellular with maturing trilineage hematopoiesis and marked eosinophilia (Figure 2a and 2b), diagnostic of a myeloproliferative neoplasm: chronic eosinophilic leukemia with 4q12 deletion (CHIC2 deletion with PDGFA/FIP1 fusion).

Skin biopsy of the vascular lesions revealed non-inflammatory vascular thrombosis; notable for multiple fibrin thrombi within the vessels of the reticular dermis (Figure 2c and 2d). The vessels included capillaries as well as small arterioles. The thrombi were not associated with inflammation or changes of vasculitis; no cholesterol clefts were identified in association with the thrombi (Figure 2c).

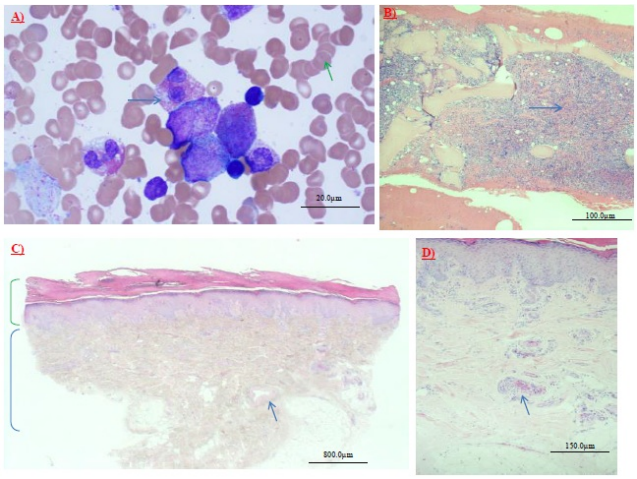

Figure 2: (A) Bone marrow aspirate smear (high power): noted red blood cells with occasional rouleaux formation (green arrow); as well as atypical eosinophil with clumping of eosinophils (blue arrow). **(B)** Bone marrow biopsy (low power); with notable hypercellular appearance; and noted mature trilineage hematopoiesis (megakaryocytes, erythroid precursors and myeloid precursors), along marked eosinophilia (blue arrow). **(C)** Skin biopsy (low power) highlighting a vessel near the right side of this photo (arrow). Noted the epidermis (green bracket) and underlying dermis layers (blue bracket). The vessel demonstrate evidence of fibrin thrombus formation (better visualized under high power) (blue arrow). **(D)** Skin biopsy (high power) demonstrating presence of bland thrombi (fibrin thrombus) formation in the vessel of interest (blue arrow)

The patient was initially treated with high dose intravenous corticosteroids for three days, followed by oral prednisone (100 mg). Hydroxyurea was simultaneously initiated and then transitioned to Imatinib therapy. He was placed on full-dose anticoagulation therapy (warfarin) for 3 months.

Discussion

Neurological complications are common in hypereosinophilia, and include stroke, peripheral neuropathy, and encephalopathy [1,2]. Our patient presented with rapidly progressive encephalopathy, neuropathy and a pattern of borderzone infarction on MRI. Marked eosinophilia was found, secondary causes were ruled out and bone marrow biopsy confirmed the diagnosis of CHE. Hypereosinophilic-related cerebral infarction typically affects vascular borderzones [1-3], traditionally ascribed to impaired hemodynamics (generally upstream high-grade stenosis or marked hypotension), but thorough evaluation in our patient revealed neither vascular compromise nor evidence for systemic hypotension. Hyperviscosity syndromes often associated with borderzone infarcts [4-6], were excluded in our patient.

Our patient suffered multi-organ dysfunction. In addition to the nervous system involvement, there was troponin elevation and skin biopsy revealed fibrin thrombi deposition within the reticular dermis; in capillaries as well as small arterioles. Endomyocardial fibrosis has been documented in HES with (TCD evidence of) microembolism implicated as the etiology of borderzone infarction in this disease [7]. Our patient however had no evidence of this, despite extensive cardiac evaluation.

We hypothesize that the borderzone pattern of infarction observed in hypereosinophilia is directly related to intravascular release of toxic mediators (ribonuclease, major basic protein, and cationic protein [2,5], leading to direct endothelial cell damage. This may lead to thrombosis and embolic infarctions. The characteristic manifestations of cerebral eosinophilic toxicity were first described as the "Gordon Phenomena" in their experimental model of intraventricular injection of Hodgkin's disease aspirates into rabbit cerebrospinal fluids [2,3]. Eosinophils-derived neurotoxin such as ribonuclease, major basic proteins, and cationic protein have been demonstrated in experimental models to damage multiple cell type and organs [2,3]. This in turn may lead to thrombosis and embolic infarctions with a predilection to the watershed zones.

Endothelial damage in peripheral nerves leading to nerve edema and axonal loss explains the peripheral neuropathy in this entity. Additionally, elevated triptase levels related to degranulation of mast cells linked to eosinophil activation may exacerbate the condition. The specific predilection to watershed "borderzones" is based on the "impaired wash-out theory" that these regions have lower perfusion pressure and in turn lower capacity to clear both eosinophil-derived toxins as well as microemboli or in-situ thromboses [1,3].

In addition to the direct neuronal and vascular injury of hypereosinophilia, hyperviscosity may also act in synergy. This is also a well described phenomenon of non-hemodynamic cause of watershed infarcts. However, this was excluded in our patient given normal serum viscosity as well as lack of severely elevated WBC. However, this patient was noted with elevated Triptase levels; which directly link to degranulation of mast cells; in turns linked to eosinophil activation; and supporting a direct vascular and neuronal injury of the easinophils.

The patient's encephalopathy was thought to be most directly linked to the neuronal and microvascular CNS injury related to hypereasinophilia. Other serious causes of encephalopathy were excluded through extensive work-up. The encephalopathy resolved with treatment of hypereasinophilia.

In addition to CNS and PNS injury, our patient suffered multiple organ dysfunction thoughts to be directly related to the toxic-effect of hypereasinophilia. Skin biopsy revealed fibrin thrombi deposition within the reticular dermis; in within capillaries as well as small arterioles. This patient was also noted with elevated cardiac biomarkers despite normal TEE and cardiac MRI. We suspected a direct coronary injury related to the toxic-mediator of hypereosinophilia.

In summary, the borderzone pattern of cerebral infarction associated with hypereosinophilia sets it apart from stroke of other etiologies: a distribution relatively rare in non-hemodynamic related infarcts. Our case suggests a relationship to both hemodynamically-impaired washout and direct endothelial injury, and that this pattern is not unique to the brain but may be observed in other organs as well.

References

1. Aida L, Parkhutik V, Tembl JI, Martín N, Frasquet M, et al. (2013) Embolism and impaired washout: a possible explanation of border zone strokes in hypereosinophilic syndrome. J Neurol Sci 325: 162-164.
2. Moore PM, Harley JB, Fauci AS (1985) Neurologic dysfunction in the idiopathic hypereosinophilic syndrome. Ann Intern Med 102: 109-114.
3. Valent P, Klion AD, Horny HP, Roufosse F, Gotlib J, et al. (2012) Contemporary consensus proposal on criteria and classification of eosinophilic disorders and related syndromes. J Allergy Clin Immunol 130: 607-612.
4. McMillan HJ1, Johnston DL, Doja A (2008) Watershed infarction due to acute hypereosinophilia. Neurology 70: 80-82.
5. Moore PM, Harley JB, Fauci AS (1985) Neurologic dysfunction in the idiopathic hypereosinophilic syndrome. Ann Intern Med 102: 109-114.
6. Grigoryan M, Geisler SD, St Louis EK, Baumbach GL, Davis PH (2009) Cerebral arteriolar thromboembolism in idiopathic hypereosinophilic syndrome. Arch Neurol 66: 528-531.
7. Amarenco P (2008) Watershed infarction due to acute hypereosinophilia. Neurology 71: 779.
8. Fauci AS, Harley JB, Roberts WC, Ferrans VJ, R GH, et al. (1982) The idiopathic hypereosinophilic syndrome. Clinical, pathophysiologic, and therapeutic syndrome. Ann Int Med 97: 78-92.
9. Rampling MW (2003) Hyperviscosity as a complication in a variety of disorders. Semin Thromb Hemost 29: 459-465.
10. Klion AD, Noel P, Akin C (2003) Elevated serum tryptase levels identify a subset of patients with a myeloproliferative variant of idiopathic hypereosinophilic syndrome associated with tissue fibrosis, poor prognosis, and imatinib responsiveness. Blood 101: 4660-4666.
11. Parrillo JE, Lawley TJ, Frank MM, Kaplan AP, Fauci AS (1979) Immunologic reactivity in the hypereosinophilic syndrome. J Allergy Clin Immunol 64: 113-121.
12. Weller PF, Bubley GJ (1994) The idiopathic hypereosinophilic syndrome. Blood 83: 2759-2779.