

# A Novel Mutation in the SCN4A Gene in a Japanese Family with Paramyotonia Congenita

Satoru Takahashi<sup>1\*</sup>, Shiho Yamamoto<sup>1</sup>, Ryosuke Tanaka<sup>1</sup>, Akie Okayama<sup>1</sup>, Akiko Araki<sup>1</sup>, Hiroki Kajino<sup>2</sup> and Hiroshi Azuma<sup>1</sup>

<sup>1</sup>Department of Pediatrics, Asahikawa Medical University, Asahikawa, Japan

<sup>2</sup>Department of Pediatrics, Abashiri Kosei Hospital, Abashiri, Japan

\*Corresponding author: Satoru Takahashi, Department of Pediatrics, Asahikawa Medical University, 2-1-1-1 Midorigaoka-Higashi, Asahikawa 078-8510, Japan, Tel: +81-166-68-2481; Fax: +81-166-68-2489; E-mail: [satoru5p@asahikawa-med.ac.jp](mailto:satoru5p@asahikawa-med.ac.jp)

Received date: Aug 22, 2014, Accepted date: Sep 22, 2014, Published date: Sep 28, 2014

Copyright: © 2014 Takahashi S, et al. This is an open-access article distributed under the terms of the Creative Commons Attribution License, which permits unrestricted use, distribution, and reproduction in any medium, provided the original author and source are credited.

## Abstract

Paramyotoniacongenita is an autosomal-dominant muscle disease caused by missense mutations in *SCN4A*, the gene encoding the alpha subunit of skeletal muscle sodium channel. It is clinically characterized by paradoxical myotonia, an attack of muscle stiffness that is aggravated by repeated activity, as well by cold-induced muscle stiffness. We describe the clinical and genetic features of a Japanese family with Paramyotoniacongenita. Five members of this family (four generations) were affected. Treatment with mexiletine, an antiarrhythmic drug that inhibits inward sodium current, relieved their symptoms. We identified a novel *SCN4A* mutation (c.3470T>A, p.Ile1157Asn) in the affected individuals. This mutation is located on the cytoplasmic loop connecting the transmembrane segments S4 and S5 of domain 3 of the sodium channel, the site for docking with its inactivation particle. This mutation may cause the defective inactivation of the channel. Our observation provides a new insight into the genotype-phenotype correlation in sodium channelopathies.

**Keywords:** Paramyotoniacongenita; Sodium channel; Muscle; Mutation

## Introduction

Skeletal muscle sodium channelopathies are rare autosomal-dominant diseases characterized by episodic abnormalities of muscle membrane excitability [1]. The predominant clinical symptoms are either myotonia or muscle weakness, which are caused by an increase or decrease in muscle membrane excitability. Myotonia is the result of uncontrolled repetitive muscle fiber discharges, which is a consequence of increased membrane excitability. The sodium channelopathies include five allelic disorders: paramyotoniacongenita (PMC), potassium-aggravated myotonia, hyperkalemic periodic paralysis, hypokalemic periodic paralysis, and a form of congenital myasthenic syndrome [1-3]. PMC is distinct from other forms of myotonia. It is characterized by paradoxical myotonia, defined as increased muscle stiffness upon repeated muscle contractions, in which the symptoms usually worsen in cold environments. All of these conditions are caused by missense mutations in the gene *SCN4A* that encodes the pore-forming alpha subunit of the skeletal muscle sodium channel (Nav1.4) [1,4]. The *SCN4A* gene is located on chromosome 17q 23.1-25.3 and comprises 24 exons with a 5.5-kb open reading frame [5,6]. To date, more than 50 different *SCN4A* mutations have been reported in patients with sodium channelopathies (The Human Gene Mutation Database, HGMD; <http://www.hgmd.org>). The relation between genotype and phenotype is complex and is not always consistent. We report here a family with PMC in which a novel missense mutation in *SCN4A* was identified.

## Case Report

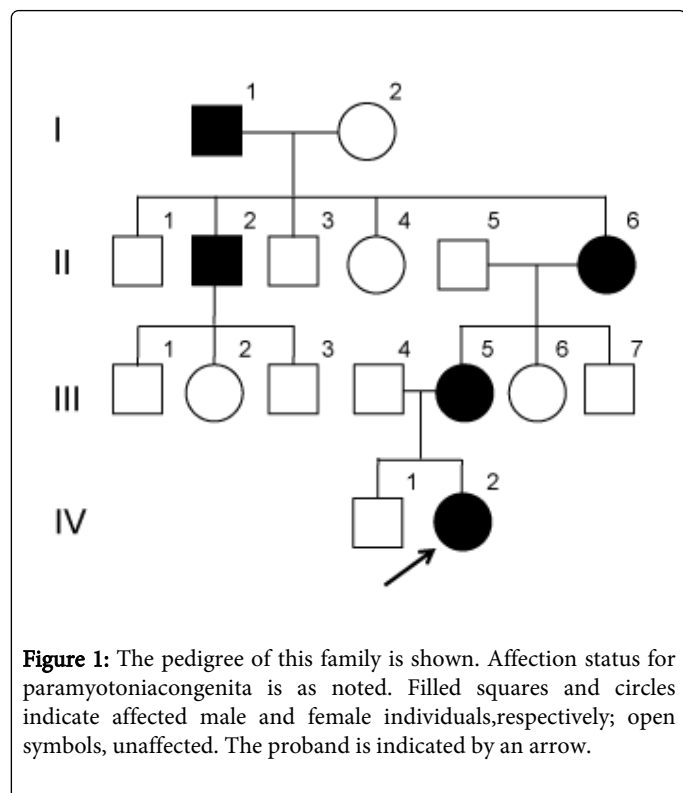
A Japanese family spanning four generations is described in this study (Figure 1). A detailed family history was obtained by interviewing the mother (III-5) of the proband. Five members of this family suffered from paramyotoniacongenita (I-1, II-2, II-6, III-5, and IV-2).

The proband (IV-2) was a 12-year-old girl who was diagnosed as having PMC. She was born to non-consanguineous parents. The pregnancy and delivery were not eventful. Her growth and developmental milestones were normal. Since the age of 7 years she had complained of muscle stiffness that affected her face and limbs in cold environments. When she was swimming in cold pool, she had had a life-threatening experience: her eyes could not be opened and her upper limbs could not be moved. This was accompanied by a cramping sensation in the lower limbs. Also, she found it difficult to release tightly gripped objects and to open her eyes following sneezing. When she played the flute, the movement of fingers tended to worsen with ongoing performance. There was no exacerbation of these symptoms after eating potassium-rich food such as fruits or meal. She had no apparent muscle weakness or paralysis after she recovered from a myotonia attack. On examination, she showed grip myotonia that was further exacerbated by ongoing exercise. Eyelid myotonia after repeated forceful closure of the eyes was also present. There was no muscle atrophy or hypertrophy. Serum levels of sodium, potassium, and chloride were normal, and serum creatine kinase was 134 U/L (normal range, 25-220 U/L). Treatment with mexiletine (150 mg daily in three divided oral doses) was sufficient to relieve her symptoms.

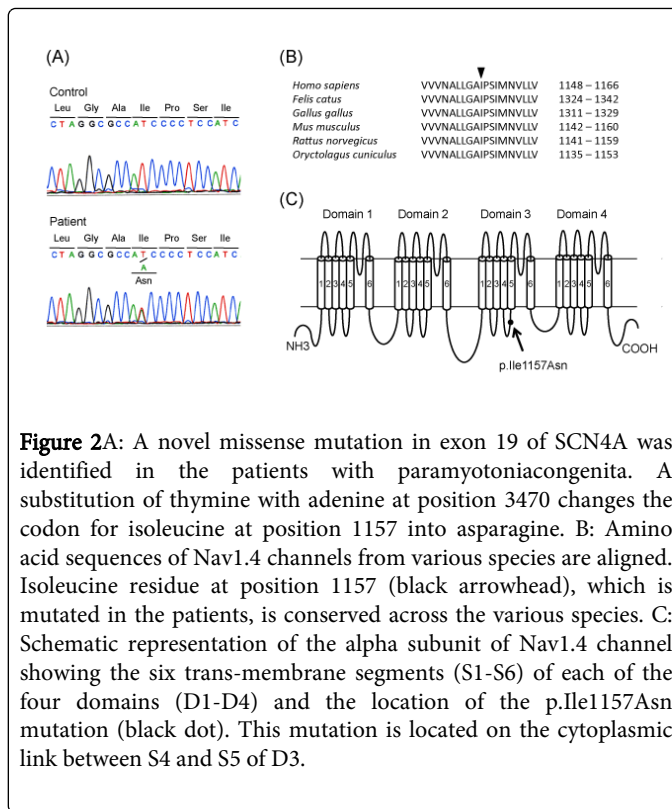
The 38-year-old mother (III-5) of the proband had similar symptoms of cold-induced muscle stiffness that began in early childhood. Face and upper limb muscles were predominantly affected. In a cold environment or even in cool wind, her eyes could not be

opened for several seconds and she could not speak clearly due to muscle stiffness of the tongue. She had experienced muscle stiffness in her upper limbs during exercise in the cold, whereas these symptoms did not occur in a warm condition. These clinical features were not triggered or exacerbated by eating fruits or any other food. She had never experienced episodes of generalized flaccid weakness. The neurological examination disclosed paradoxical eyelid myotonia after repeated forceful closure of the eyes. Muscle hypertrophy and weakness were absent. The creatine kinase level as well as other routine blood parameters was normal. Treatment with mexiletine relieved her symptoms while having eyelid myotonia elicited at room temperature.

In addition to the proband and her mother, 3 other members of this family (I-1, II-2 and II-6) were thought to have cold-induced muscle stiffness with onsets in childhood based on the information obtained from the mother (III-5). The frequency of attacks gradually appeared to decrease with age.



After obtaining written informed consent from the participants, genomic DNA was extracted from the peripheral blood leukocytes of the proband (IV-2) and her mother (III-5), and was used as the template for polymerase chain reaction (PCR). The compatible primers were used to yield DNA fragments spanning the entire coding region and intron-exon boundaries of SCN4A. The PCR fragments were analyzed using automated sequencing. We identified a SCN4A missense mutation (c.3470T>A, p.Ile1157Asn) in both the patients (Figure 2A). This missense mutation alters an amino acid residue in the cytoplasmic link between the trans-membrane segments 4 (S4) and 5 (S5) of domain 3 (D3) of the alpha subunit of Nav1.4 channel that is highly conserved in different species (Figure 2B and 2C). This mutation was not detected in 100 control DNAs.



## Discussion

A familial case is reported with autosomal dominant myotonia in which we identified a novel missense mutation in SCN4A. Diagnosis of PMC was made on the basis of the following clinical features: cold- and exercise-induced myotonia affecting muscles of the face and upper limbs, with early childhood onset, along with the absence of a warm-up phenomenon (repeated muscle contractions exacerbated myotonia instead of alleviating the symptoms), and no effect of eating potassium-rich food on myotonia.

The missense mutation identified in this family exhibits characteristics that suggest that it is the cause of the disease. First, it causes the substitution of the isoleucine residue at a position 1157 of the Na<sub>v</sub>1.4 channel protein that is highly conserved in different species, suggesting functional importance. Second, it was absent in 100 healthy Japanese individuals tested, indicating that it is unlikely to represent a common polymorphism. Third, it segregates with the paramyotonia phenotype in this family. These observations strongly support the idea that this mutation is pathogenic. Although mutations in SCN4A have been identified in various forms of sodium channelopathies, this mutation has never been reported (HGMD, <http://www.hgmd.org>). Our observation provides an important insight into the genotype-phenotype correlation of sodium channelopathies.

The voltage-gated sodium channel is composed of four structurally homologous domains (D1-D4), with six membrane-spanning segments (S1-S6) within each domain [2]. The channel is designed to open and close in response to an electrical potential change in the cell membrane [4]. The occlusion of the channel occurs on the cytoplasmic side through folding of the linker between D3 and D4 into the pore [7]. The S4-S5 cytoplasmic loops of D3 and D4 are short sequences of 15-20 amino acids and are thought to contribute to the formation of a

receptor site for the inactivation particle, a conserved hydrophobic cluster of three amino acids IFM (isoleucine, phenylalanine, and methionine) in the D3-D4 cytoplasmic linker [8,9]. According to the functional studies, PMC-associated mutations have been shown to disrupt fast inactivation of the sodium channel, resulting in a prolonged Na<sup>+</sup> influx that promotes excessive membrane depolarization [10,11]. Moreover, cooling aggravates mutant channel defects by further slowing channel gating [12]. The mutation identified in this family is located on the cytoplasmic loop between S4 and S5 of D3, the site for association with the inactivation particle. It may cause the defective inactivation of the sodium channel, resulting in depolarization of muscle fibers. The degree of depolarization may determine the clinical phenotype. Slight depolarization causes membrane hyper-excitability and myotonia, whereas sustained depolarization induces membrane inexcitability and muscle paralysis [13]. The affected individuals in this family usually presented with cold- and exercise-induced myotonia, but never reported episodes of muscle paralysis. Therefore, this mutation may cause slight depolarization with myotonia, most likely due to an impairment of fast inactivation of the mutant sodium channel.

The aim of drug therapy in myotonia is to reduce the involuntary depolarization. Mexiletine is a class 1b antiarrhythmic drug used for ventricular arrhythmias but is also found to be effective for PMC [14]. The *in vivo* efficacy of mexiletine is most likely due to the open-channel blockage of persistent Na<sup>+</sup> currents [15]. An *in vitro* study confirmed the beneficial effect of mexiletine in the pathological condition: mexiletine could prevent persistent Na<sup>+</sup> currents through the inactivation-deficient mutant sodium channels with SCN4A mutation [16]. Treatment with mexiletine was effective for relieving the symptoms in our patients. Genetic testing for *SCN4A* could confirm the clinical diagnosis of PMC and provide the chance for successful treatment based on the pathophysiology.

## Acknowledgement

This work was supported in part by Grant-in-Aid for Scientific Research C from the Japan Society for the Promotion of Science (#22591118).

## References

- Hoffman EP, Lehmann-Horn F, Rüdel R (1995) Overexcited or inactive: ion channels in muscle disease. See comment in PubMed Commons below *Cell* 80: 681-686.
- George AL Jr (2005) Inherited disorders of voltage-gated sodium channels. See comment in PubMed Commons below *J Clin Invest* 115: 1990-1999.
- Jurkat-Rott K, Holzherr B, Fauler M, Lehmann-Horn F (2010) Sodium channelopathies of skeletal muscle result from gain or loss of function. See comment in PubMed Commons below *Pflugers Arch* 460: 239-248.
- Hudson AJ, Ebers GC, Bulman DE (1995) The skeletal muscle sodium and chloride channel diseases. See comment in PubMed Commons below *Brain* 118 : 547-563.
- George AL Jr, Ledbetter DH, Kallen RG, Barchi RL (1991) Assignment of a human skeletal muscle sodium channel alpha-subunit gene (SCN4A) to 17q23.1-25.3. See comment in PubMed Commons below *Genomics* 9: 555-556.
- George AL Jr, Komisarof J, Kallen RG, Barchi RL (1992) Primary structure of the adult human skeletal muscle voltage-dependent sodium channel. See comment in PubMed Commons below *Ann Neurol* 31: 131-137.
- West JW, Patton DE, Scheuer T, Wang Y, Goldin AL, et al. (1992) A cluster of hydrophobic amino acid residues required for fast Na<sup>+</sup>-channel inactivation. See comment in PubMed Commons below *Proc Natl Acad Sci U S A* 89: 10910-10914.
- Catterall WA (2000) From ionic currents to molecular mechanisms: the structure and function of voltage-gated sodium channels. See comment in PubMed Commons below *Neuron* 26: 13-25.
- Popa MO, Alekov AK, Bail S, Lehmann-Horn F, Lerche H (2004) Cooperative effect of S4-S5 loops in domains D3 and D4 on fast inactivation of the Na<sup>+</sup> channel. See comment in PubMed Commons below *J Physiol* 561: 39-51.
- Chahine M, George AL Jr, Zhou M, Ji S, Sun W, et al. (1994) Sodium channel mutations in paramyotoniacongenita uncouple inactivation from activation. See comment in PubMed Commons below *Neuron* 12: 281-294.
- Yang N, Ji S, Zhou M, Ptáček LJ, Barchi RL, et al. (1994) Sodium channel mutations in paramyotoniacongenita exhibit similar biophysical phenotypes *in vitro*. See comment in PubMed Commons below *Proc Natl Acad Sci U S A* 91: 12785-12789.
- Bouhours M, Luce S, Sternberg D, Willer JC, Fontaine B, et al. (2005) A1152D mutation of the Na<sup>+</sup> channel causes paramyotoniacongenita and emphasizes the role of DIII/S4-S5 linker in fast inactivation. See comment in PubMed Commons below *J Physiol* 565: 415-427.
- Kinoshita M, Sasaki R, Nagano T, Matsuda A, Nakamura S, et al. (2003) Thr1313Met mutation in skeletal muscle sodium channels in a Japanese family with paramyotoniacongenita. See comment in PubMed Commons below *Intern Med* 42: 856-861.
- Jackson CE, Barohn RJ, Ptacek LJ (1994) Paramyotoniacongenita: abnormal short exercise test, and improvement after mexiletine therapy. See comment in PubMed Commons below *Muscle Nerve* 17: 763-768.
- Lehmann-Horn F, Jurkat-Rott K (1999) Voltage-gated ion channels and hereditary disease. See comment in PubMed Commons below *Physiol Rev* 79: 1317-1372.
- Wang GK, Russell C, Wang SY (2004) Mexiletine block of wild-type and inactivation-deficient human skeletal muscle hNav1.4 Na<sup>+</sup> channels. See comment in PubMed Commons below *J Physiol* 554: 621-633.