

A Bibliometric Analysis of Optic Coherence Tomography Studies in Multiple Sclerosis

Nedim Ongun, Cagdas Erdogan and Eylem Degirmenci*

Pamukkale University, School of Medicine, Department of Neurology, Denizli, Turkey

Abstract

Objective: Optical coherence tomography (OCT) is a non-invasive, non-contact diagnostic tool that provides high-resolution cross-sectional images of the retina that has been used for ten years in multiple sclerosis (MS) related optic neuropathies. The objective of this study is to determine the scientific output in use of OCT in multiple sclerosis between 1982 and 2012 using ISI Web of Knowledge.

Methods: The ISI Web of Knowledge was searched for articles on OCT published between 1982 and February 2012 using appropriate terms. Articles were characterized each year by publication type.

Results: Search yielded 154 publications after the search for keywords "optical coherence tomography and multiple sclerosis" and 167 publications after the search for the keywords "optical coherence tomography and optic neuritis". After eliminating the conflicting publications total 193 publications were analyzed. A cubic increase in the number of publications over time was observed.

Conclusions: The number of scientific publications in the field of OCT in MS has increased significantly over the past years. The United States, England and Spain have dominated the field of OCT in MS.

Keywords: Optical coherence tomography; Multiple sclerosis; Optic neuritis; Bibliometric analysis

Introduction

Optical coherence tomography (OCT) is a non-invasive, non-contact diagnostic tool that provides high-resolution cross-sectional images of the retina [1]. The first study to investigate the role of OCT technology in the evaluation of MS patients was reported in the end of 1990s and after than many studies were performed the use of OCT in MS [2-5]. Most of these papers provide the use of OCT in patients with MS by means of some clinical predictors and/or follow-up assessment method of neurodegeneration, however there opposite reports too [6-9].

The objective of this study was to provide a global view of the OCT studies in MS. With this aim, we analyzed various parameters of the OCT literature published in journals indexed in the Institute for Scientific Information (ISI) Web of Knowledge database, including the number of publications, type of the publication, countries, top-cited articles and authors, subject of the studies, main results of the studies, publication language, specific journals and funding.

Materials and Methods

We searched the ISI Web of Knowledge database (1982-2012) using the keywords "optical coherence tomography and multiple sclerosis" or "optical coherence tomography and optic neuritis (ON)". All of the publications were analyzed by the help of abstracts in the ISI Web of Knowledge database and conflicting publications were discarded. We analyzed the number of publications, distribution of the publications by year, publication types (article, letter, proceeding, abstract, review and other), language of the publications, number of publications per journal, publication output by country. In addition subject and main results of the studies were also recorded. We also generated a list of the top 10 OCT-MS related articles based on the citation numbers.

SPSS software (version 15.0; SPSS Inc., Chicago, IL, USA) was used for descriptive statistical analyses. P-values < 0.05 were considered

significant. Regression analysis was used to determine the association between year of publication and the number of publication.

Results

The ISI Web of Knowledge database search yielded 154 publications after the search for keywords "optical coherence tomography and multiple sclerosis" and 167 publications after the search for the keywords "optical coherence tomography and optic neuritis". After eliminating the conflicting publications total 193 publications were analyzed. All of the abstracts were investigated and 112 publications were found about MS-related optic neuropathies and multiple sclerosis. The animal studies were consisting of 1.8% of the publications while percentage of studies with definite MS patients was 49.1% and percentage of studies with MS-related isolated ON patients was 30.4%. The percentage of the patients publications in which the patient group was not determined (Neither definite MS nor MS-related isolated ON patients) was 18.8%. As shown in Table 1, the publication type most frequently used was the article, which constituted 73.2% of the total publications (82 articles), followed by meeting abstract (19; 17%), review (8; 7.1%), editorial material (2; 1.8% and letter (1; 0.9%). The year of first publication about use of OCT in MS was 1999, but after 1999 there was no publication until 2004. Table 1 shows the number of publications and types per year between 2004 and 2011. There was a statistically significant cubic increase over time in the total number

*Corresponding author: Dr Eylem Degirmenci, Pamukkale Universities Tip Fakultesi, Noroloji AD, 20070, Kinikli-Denizli, Turkey, Tel: +90258 4440728-5677; Fax: +902582131034; E-mail: eylemteke@yahoo.com

Received December 10, 2013; Accepted January 29, 2014; Published February 09, 2014

Citation: Ongun N, Erdogan C, Degirmenci E (2014) A Bibliometric Analysis of Optic Coherence Tomography Studies in Multiple Sclerosis. J Neurol Neurophysiol S12: 007. doi:10.4172/2155-9562.S12-007

Copyright: © 2014 Ongun N, et al. This is an open-access article distributed under the terms of the Creative Commons Attribution License, which permits unrestricted use, distribution, and reproduction in any medium, provided the original author and source are credited.

Year	Total (n)	Article	Review	Meeting abstract	Editorial material	Letter
1999	1	1	0	0	0	0
2000-2003	0	0	0	0	0	0
2004	3	0	0	3	0	0
2005	4	1	0	3	0	0
2006	5	3	0	1	1	0
2007	13	6	2	4	0	1
2008	14	9	0	5	0	0
2009	13	12	0	1	0	0
2010	27	22	3	1	1	0
2011	30	27	2	1	0	0

Table 1: Number of publications and types per year between 2004 and 2011.

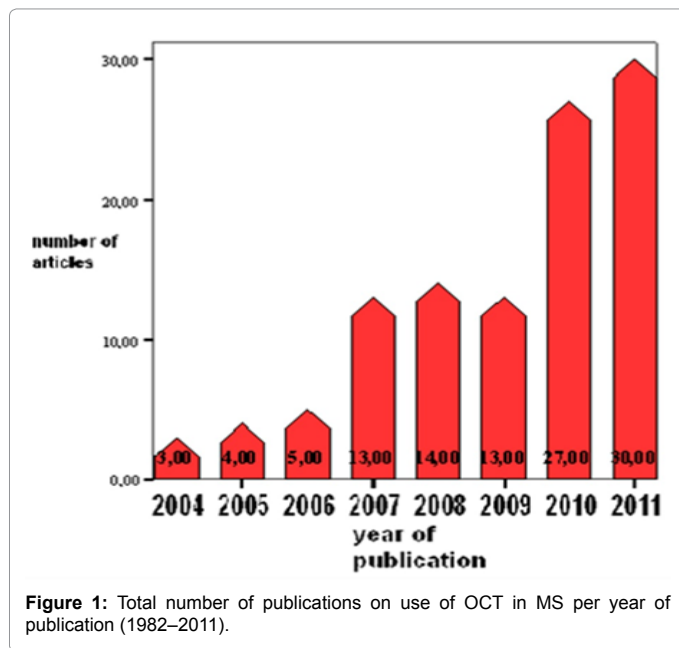


Figure 1: Total number of publications on use of OCT in MS per year of publication (1982–2011).

of publications in the medical literature ($R^2=94.1\%$, $P<0.0001$) (Figure 1). Reported funding according to ISI Web of Knowledge database was found 40.2% of the articles.

We found that publications about the use of OCT in MS were published in 47 different journals. Table 2 shows the list of journal names in which more than two publications were found about use of OCT in MS.

We found that publications about the use of OCT in MS are from total 20 countries (USA, England, Spain, Canada, Multicenter studies from Europe, Germany, Denmark, Australia, Austria, France, Turkey, Italy, Brazil, Hungary, Greece, Holland, China, and Poland). Most of the publications were from U.S.A. and Spain and England are the two other countries following U.S.A. The mean number of citations per publication was 13.2 (range 0-155). Most cited 10 publications with publication title, year and journal name are shown in Table 3. Ninety-four percent of the publications were in the English language (108; 96.4%). The non-English publications were in German (2; 1.8%), French (1; 0.9%), and unspecified (1; 0.9%).

In this study main results of the publications were also analyzed and results were classified as positive, negative and undetermined results for benefic of OCT in MS. According to our results 68.8% of the publications had given positive results, 6.3% of the publications had

given negative results but 25.0% of the publications' results could not be determined. In addition main subjects of the publications were also analyzed in our study. Table 4 summarizes the main subjects of the publications.

Discussion

Over the last 10 years, the number of publications about use of OCT in MS has gradually increased. The United States ranked first among countries in the overall number of publications. However the number of the publications from some European countries like Spain and England should not be underestimated. Compared with American neurologist and ophthalmologist Europeans are also likely to use OCT as a research topic in MS.

Eighty percent of MS patients present with an acute clinical episode affecting one or several neurological sites, which is known as the clinically isolated syndrome (CIS) [2]. ON is the best studied CIS, and represents the first clinical manifestation of MS in approximately 20% of cases. In addition to being the clinical inception for many, an additional 30% to 70% of patients develop ON during the course of their disease, making the anterior visual pathway a frequent target in MS [2]. OCT has the potential to provide a reliable means of capturing axonal deficits, which can be paired to tests of visual function to provide a structural-functional paradigm of brain injury. In this respect, the eye provides a unique view into the effects of central nervous system inflammation, which may enhance the understanding of disease mechanisms that contribute to neurological disability and pathophysiological mechanisms of neurodegeneration in MS.

The earliest application of OCT technology to the study of MS was reported by Parisi et al. in 1999 [10]. OCT is a promising new tool for evaluating atrophy in patients with ON and MS⁵ and this bibliometric study shows that 49.1% of the all publications were performed on patients with definite MS and the percentage of publications that were performed on patients with MS-related isolated ON was 30.4%. Most of the studies and the reviews in the literature give positive results about the use of OCT in MS [1-5], however we found that 6.3% of the all publications had given negative results about the utility of OCT in MS patients.

Although the majority of the publications were published in MS specific journals, our results showed that most cited article about use of OCT in MS were published in neurology and ophthalmology journals rather than MS specific journals and with this result it may be concluded that the new research topic OCT is also in the area of interest of the neurologist and/or neuro-ophthalmologists.

Journal name	Number of publications
Multiple Sclerosis	12
Neurology	11
Investigative Ophthalmology and Visual Science	10
Annals of Neurology	6
Multiple Sclerosis Journal	6
Journal of Neuroophthalmology	5
JONS	4
European Journal of Ophthalmology	3
Public Library of Science One	3
European Journal of Neurology	3
Brain	3
Journal of Neurology	3
Achieves of Neurology	3

Table 2: Names of the journals in with more than two publication of OCT in MS and number of the publications.

Author	Journal	Title	Year	Times cited
Trip et al.	Annals of neurology	Retinal nerve fiber layer axonal loss and visual dysfunction in optic neuritis.	2005	155
Fisher et al.	Ophthalmology	Relation of visual function to retinal nerve fiber layer thickness in multiple sclerosis.	2006	152
Costello et al.	Annals of neurology	Quantifying tonal loss after optic neuritis with optical coherence tomography.	2006	130
Parisi et al.	Investigative ophthalmology and visual science	Correlation between morphological and functional retinal impairment in multiple sclerosis patients.	1999	125
Trip et al.	Neuroimage	Optic nerve atrophy and retinal nerve fibre layer thinning following optic neuritis: Evidence that axonal loss is a substrate of MRI-detected atrophy.	2006	77
Sepulcre et al.	Neurology	Diagnostic accuracy of retinal abnormalities in predicting disease activity in MS.	2007	75
Pulicken et al.	Neurology	Optical coherence tomography and disease subtype in multiple sclerosis.	2007	73
Henderson et al.	Brain	An investigation of the retinal nerve fibre layer in progressive multiple sclerosis using optical coherence tomography.	2008	51
Zaveri et al.	Achieves of neurology	Retinal imaging by laser polarimetry and optical coherence tomography evidence of axonal degeneration in multiple sclerosis.	2008	39
Noval et al.	Acta ophthalmologica scandinavica	Optical coherence tomography versus automated perimetry for follow-up of optic neuritis.	2006	34

Table 3: Most cited 10 publications about use of OCT in MS and MS-related ON.

Subject of the publications	Percentage
OCT – Clinical and functional vision comparisons	28.6%
OCT – Clinical and functional vision and/or visual evoked potential and/or laser polarimetry comparisons	20.5
OCT – Clinical and functional vision and MRI (conventional and nonconventional) comparisons	16.1%
OCT – Clinical and functional vision and automated perimetry comparisons	5.4%
OCT – technique results	2.7%
OCT- Clinical and functional vision and retinal vessel analyses comparisons	0.9%
OCT – Clinical and functional vision and retinal tomography comparisons	0.9%
OCT – Clinical and functional vision and retinal periphlebitis comparisons	0.9%

Table 4: Main subjects of the publications.

Main subjects of the publications were compromising comparisons of clinical parameters with electrophysiological tests, conventional and non-conventional MRI techniques and other ophthalmological tests (quantitative ophthalmoscopes). OCT may also be invaluable for evaluating the effects of therapies on patients with MS but according to our results there is not any definite data about the results of MS therapies on OCT parameters. It is possible that MS could be used as a model disease to study degeneration and regeneration of the central nervous system [11,12] and OCT is found beneficial to show progressive neuroaxonal injury in MS in most of the publications. At this point of view, we estimate that publications of OCT in both MS and other neurodegenerative diseases would gradually increase in the forthcoming years. The incorporation of OCT into the study of neurodegenerative disorders will provide new insights into a more global role for this technology in neurologic disease.

OCT can be used in the ON to capture structural changes in the anterior visual pathway, which will provide unique insights regarding pathogenic mechanisms of CNS injury and, in turn, to develop more effective therapeutic strategies for MS patients. As the data from OCT studies continue to mount, there is evidence to support the feasibility of the ON system model in clinical research and potentially, to establish a role for OCT in the diagnosis and treatment of MS patients.

In conclusion, this study represents the first bibliometric assessment of research of OCT in MS literature. Interest in use of OCT in MS and MS-related ON as a valuable clinical tool continues to grow.

References

1. Miller DH, Altmann DR, Chard DT (2012) Advances in imaging to support the development of novel therapies for multiple sclerosis. *Clin Pharmacol Ther* 91: 621-634.
2. Costello FE, Klistorner A, Kardon R (2011) Optical coherence tomography in the diagnosis and management of optic neuritis and multiple sclerosis. *Ophthalmic Surg Lasers Imaging*. 42: 8-40.
3. Galetta KM, Calabresi PA, Frohman EM, Balcer LJ (2011) Optical coherence tomography (OCT): imaging the visual pathway as a model for neurodegeneration. *Neurotherapeutics* 8: 117-132.
4. Petzold A, de Boer JF, Schippling S, Vermersch P, Kardon R, et al. (2010) Optical coherence tomography in multiple sclerosis: a systematic review and meta-analysis. *Lancet Neurol* 9: 921-932.
5. Lamirel C, Newman N, Bioussé V (2009) The use of optical coherence tomography in neurology. *Rev Neurol Dis* 6: E105-120.
6. Kallenbach K, Sander B, Tsakiri A, Wanscher B, Fuglø D, et al. (2011) Neither retinal nor brain atrophy can be shown in patients with isolated unilateral optic neuritis at the time of presentation. *Mult Scler* 17: 89-95.
7. Serbecic N, Aboul-Enein F, Beutelspacher SC, Graf M, Kircher K, et al. (2010) Heterogeneous pattern of retinal nerve fiber layer in multiple sclerosis. High resolution optical coherence tomography: potential and limitations. *PLoS One* 5: e13877.
8. Outteryck O, Zephir H, Defoort S, Bouyon M, Debruyne P, et al. (2009) Optical coherence tomography in clinically isolated syndrome: no evidence of subclinical retinal axonal loss. *Arch Neurol* 66: 1373-1377.
9. Naismith RT, Tutlam NT, Xu J, Shepherd JB, Klawiter EC, et al. (2009) Optical coherence tomography is less sensitive than visual evoked potentials in optic neuritis. *Neurology* 73: 46-52.
10. Parisi V, Manni G, Spadaro M, Colacino G, Restuccia R, et al. (1999) Correlation between morphological and functional retinal impairment in multiple sclerosis patients. *Invest Ophthalmol Vis Sci* 40: 2520-2527.
11. Frohman EM, Fujimoto JG, Frohman TC, Calabresi PA, Cutter G, et al. (2008) Optical coherence tomography: a window into the mechanisms of multiple sclerosis. *Nat Clin Pract Neurol* 4: 664-675.
12. Fong JS, Rae-Grant A, Huang D (2008) Neurodegeneration and neuroprotective agents in multiple sclerosis. *Recent Pat CNS Drug Discov* 3: 153-165.