

Effectiveness of Internal Sphincterotomy in reducing Post Open Hemorrhoidectomy Pain: A Randomized Comparative Clinical Study

DK Das ^{1*}, UC Choudhury ², Lim ZS ³

¹ Associate Professor & HOD, Dept. of Surgery, FMHS (Formerly Consultant Down Town Hospital), UCSI University, Terengganu Clinical Campus, Malaysia

² O&G Specialist; Guwahati-781028, India

³ 5th year Medical Student; UCSI, University, Clinical Campus, Malaysia

* **Corresponding Author:** Assoc. Prof. Dr. D. K. Das
Dept. of Surgery, FMHS; UCSI University, Terengganu Campus
Bukit Khor, PT 11065, Mukin Rusila
21600, Marang, Kuala Terengganu, Malaysia
Email: digantadas03@gmail.com | Phone: 0661302005060

Abstract

Background: Hemorrhoids are one of the most common disorders of anus. Various treatment modalities have been described over the periods. However, open hemorrhoidectomy; mainly for grade 3 and 4 haemorrhoids is still widely used. The main drawback of hemorrhoidectomy is the pain in the early postoperative period. Studies have showed that internal Sphincterotomy along with Hemorrhoidectomy significantly reduces the post operative pain without any major complications.

Aim & Objective: The aim of this study was to evaluate the effects of internal Sphincterotomy in reduction of post open hemorrhoidectomy pain.

Methods: Over a period of two years 50 patients (38 male, 12 female) aged between 24 & 50 years) treated for 3rd and 4th degree haemorrhoids were included in this prospective randomised study. Patients were randomly divided in to two equal groups. Group I (control group) were subjected to classical open hemorrhoidectomy and group II (study group) were subjected to classical open hemorrhoidectomy with internal Sphincterotomy. Patients above 50 years of age and any patients associated with other colo-rectal or anal diseases were not included in our study.

Results: Mean post-operative pain score in study group (Gr- II) was 1.60 and in control group (Gr- I) it was 2.32 (P<0.01). Postoperative complications, like urinary retention was seen in 8 patients from Gr-I and in 1 patient from Gr-II. From Gr-II; as late complications, faecal soiling was present for 3 weeks in 1 patient and impaired control of flatus was present in 2 patients for 7-10 days. One patient from Gr-I developed anal stenosis which was managed conservatively.

Conclusion: Addition of Internal sphincterotomy to open hemorrhoidectomy is an effective method to reduce post open hemorrhoidectomy pain without significant morbidity.

Key words: Open hemorrhoidectomy, post hemorrhoidectomy pain. Internal Sphincterotomy

Introduction

Hemorrhoids are one of the most common presentations of the anus.¹ Various treatment modalities have been described over the years. However, still hemorrhoidectomy offers the best chances of permanent cure of symptomatic grades-3 and 4 hemorrhoids.^{1,2} The main drawback of hemorrhoidectomy is the uncomfortable pain in the first postoperative week³. The prime cause of unpleasant post-hemorrhoidectomy pain is due to the spasm of the internal sphincter that is exposed after open hemorrhoidectomy, especially in younger patients with higher anal tone.^{4,5,6}

Review of literature showed that various methods have been tried in order to reduce post hemorrhoidectomy pain⁴. Over the time, Internal Sphincterotomy was proved as one of the valid addition to the hemorrhoidectomy for a better postoperative period in terms of less postoperative pain and less complications.^{1,7} Internal Sphincterotomy reduces post hemorrhoidectomy pain by abolishing the hypertonicity (spasm/pressure) of the internal anal sphincter and subsequently reduces the related post hemorrhoidectomy complications as well.^{7,8,9}

The main aim of this study was to compare the postoperative pain in two groups of patients treated with open hemorrhoidectomy and open hemorrhoidectomy with internal sphincterotomy. However, other related complications were also noted and included in the results.

Methods

Over a period of two years 50 patients, suffering from 3rd and 4th degree hemorrhoids attending Down Town Hospital Guwahati, were included in this prospective randomized study. Exclusion criteria: Patients over 50 years of age and hemorrhoids with other anal pathology like fistula, fissure or other colorectal diseases were not included in this study. Disease status was confirmed in all the patients by clinical examinations and proctoscopic examinations. All patients were subjected to routine investigations to look for the fitness to undergo surgery under general anaesthesia.

Patients were randomized according to their chronological numbers of hospital admission. All the patients were explained about their diagnosis and a written informed consent was obtained from each patient. Classical open hemorrhoidectomy (Milligan and Morgan, Figure 1) was performed in control group (Gr-I) and in study group (Gr-II) along with classical open hemorrhoidectomy, internal anal Sphincterotomy (IS) was also performed (Figure 2).

All the patients were operated under general anaesthesia in the lithotomy position by a single surgeon. Dissection was carried out with the help of a diathermy knife and scissors. Absolute haemostasis was maintained in the dissection bed in all the patients. Patients from study group, after completion of classical open hemorrhoidectomy, were subjected to lateral internal sphincterotomy through the left sided open hemorrhoidectomy wound up to around one cm. (Dentate line) upwards. After completion of surgery, a piece of small gauze soaked in lignocaine jelly was used to pack the anal canal lightly in all the patients and the wound was covered with a T-bandage. On second post-operative day, anal pack was removed and all patients were allowed to take hip-bath 2 times a day/after passing stool with acraflavin mixed

lukewarm water up to one week postoperatively. All patients were given 2nd generation cephalosporin and metrogyl IV three doses; 1st dose started at the time of induction of general anaesthesia.

Postoperative pain, pain during the first postoperative bowel motion, early postoperative complications, (urinary retention/reactionary bleeding/flatus or faeces incontinence) duration of hospital stay and late complications (anal stenosis), were evaluated. Another doctor (who was not a member of the operative team and also unaware of the group of the patients) was involved in assessment of the severity of postoperative pain and early complications.

Pain is a subjective matter and difficult to measure accurately. We adopted the method described by Asfar et al¹⁰ and Safwan AT¹. We assessed severity of post-operative pain according to the frequency of administration of analgesic, needed to control the pain for a patient which followed an "on-the-patient's-demand" protocol¹¹. This method is proved to be quite acceptable. Pain level was categorised as 'Mild' (grade1) if required analgesics were 0-2/48hours to control the pain, 'Moderate'(grade2) if numbers were 3-4/48hours and 'Severe' (grade3) when analgesics were >4 in numbers.

All the patients were given Tramadol hydrochloride 100mg intramuscularly. Nurses on duty and the patients were well instructed to 'give and take' analgesic when the pain was really intolerable. Details of the injection time and numbers of analgesic used were recorded against each patient. No outside food was allowed to the patients during hospital admission to avoid any herbals that may have analgesic property. From 2nd post-operative day, all the patients were given laxative (lactoluse) 10ml at bed time and advised to continue 3 weeks postoperatively. On the 7th postoperative day (1st follow-up visit for the patients already discharged from hospital) a careful digital-rectal examination (DRE) was done by the author himself in all the patients to assess the anal tone and anal stenosis if present. All the patients were followed-up in the clinic after two and four weeks of the operation and then once in a month for 3 months thereafter. In each visit DRE was performed and enquiry was made about pain, faecal soiling and flatus or faeces incontinence. Incontinence was defined as the inadvertent passing of flatus or faeces and faecal soiling was defined as the staining of underwear with rectal discharge.

Data was analysed using SPSS programme. Statistical analysis for post-operative pain score and complications between two groups was done using the χ^2 test. The P value <0.01 was taken as significant.

Results

There were 50 patients (25 in Gr-I and 25 in Gr-2), aged 24 to 50 years. There were 38 males and 12 females. 31(62%) were under 40 years of age and 19(38%) were in between 40 to 50 years of age.

Colonoscopy was performed in six patients to rule out any other underlying suspicious pathology. However, results were within normal limits. Two patients had low haemoglobin level (7.5 and 7.1 gm/dl) and both of them were transfused 2 units of blood each and given iron-folic acid tablets. Ultimately haemoglobin level was managed to top-up to around 10 gm/dl in both the patients.

It was seen from our study that postoperative pain in first 48 hours (Table-1) was significantly low ($P<0.01$) in study group (Gr-2). Mean pain score was 1.60 in the study group in comparison to 2.32 in the control group (Gr-1). Similarly early complications (Table-2) like urinary retention and pain during first bowel motion were also significantly low ($P<0.01$) in the study group in comparison to the control group.

In study group; one patient developed faecal soiling (lasted for 2 weeks) and another two patients developed flatus incontinence, lasted for about a week. In control group, one patient developed anal stenosis. All these complications were managed conservatively without any residual effects.

Discussion

High anal canal pressure was documented in patients with hemorrhoids^{12,13,14}, especially in the younger patients. Anal canal pressure remains mostly higher in younger patients due to tight internal sphincter (high tone) than the older people. This tight (over active) sphincter is the prime cause of unpleasant post hemorrhoidectomy pain.^{4,5,6,15} Keeping it in mind, in our study, patients above 50years were not included as low anal tone in these patients can have less post hemorrhoidectomy pain even without internal sphincterotomy.

Anal canal dilatation was described by Lord in 1989¹⁵, but incidence of uncontrolled damage to the internal sphincter fibres was high⁸. Nataraj in 1971 proposed internal sphincterotomy is an alternative of anal dilatation¹⁶. Subsequently Di Bella and Estienne in 1990 stated that internal sphincterotomy reduce anal pain by reduction of the sphincter tonicity⁷. Over the decade several authors reported that significant reduction of post hemorrhoidectomy pain and associated complications can be achieved by adding internal sphincterotomy to hemorrhoidectomy.⁵ Finally Asfar et al¹⁰ reported that the routine performance of internal sphincterotomy through one of the hemorrhoidectomy wounds significantly reduces post-hemorrhoidectomy pain and associated complications.

In our study, it was very obvious and statistically significant that the addition of internal sphincterotomy to hemorrhoidectomy, significantly reduced post hemorrhoidectomy pain and other associated complications in comparison to hemorrhoidectomy alone. Immediate postoperative pain was mild in 13 patients and severe in only three patients in study group, in contrast to mild pain in only two and severe pain in 10 patients in control group ($P<0.01$). Similarly, associated complications like urinary retention was present in eight patients and pain during first bowel motion was severe in nine patients in control group; in contrast to urinary retention and severe pain during first bowel motion in one patient each in study group. Mild pain during first bowel motion was noted in 22 patients in the study group ($P<0.01$).

Hospitals stay and “off work” were significantly lower in the study group, in comparison to control group. In the study group, 21 patients were discharged on 3rd day, 3 patients on 4th day and only one patient with faecal soiling and mild wound infection was discharged on 6th post operative day. Twenty three patients in study group joined their work by 6th post op day. However, in the control group; eight patients were discharged on 3th day and rest 16 patients were discharged on 5th postoperative day. One patient with anal stenosis was discharged on 8th day. Sixteen patients joined their work one week after the operation.

Complications related to internal sphincterotomy like faecal soiling (1 patient) and incontinence of flatus (2 patients) were seen in our study for a short period of time. However, it is mentioned in literature that these complications are transient and acceptable in comparison the benefits of internal sphincterotomy when added to hemorrhoidectomy.^{17,18,19}

Addition of internal sphincterotomy was found to be a suitable procedure to reduce post hemorrhoidectomy pain, but it is not totally devoid of transient complications in early post-operative period. It is more useful in young patients with higher anal pressure.

Limitation of the study: Anal manometry was not performed due to logistic problems.

Conclusions

Internal Sphincterotomy can be safely added to hemorrhoidectomy, especially for younger patients to reduce the agonising postoperative pain and associated complications.

Conflict of Interest: Nil.

References

1. Safwan A Taha. Routine internal sphincterotomy with hemorrhoidectomy for third and fourth degree hemorrhoids greatly improves the outcome. *IJGE*. 2003; 4(1): 48-51.
2. Seyed Vahid Hosseini, Khosro Sharifi, Azadeh Ahmadfard, Mahnaz Mosallaei, Saeideh Pourahmad, Shahram Bolandparvaz. Role of Internal Sphincterotomy in the Treatment of Hemorrhoids : A Randomized Clinical Trial. *Arch Iranian Med*. 2007; 10(4): 504-508.
3. Allen-Mersh TG, Mann CV. Open Haemorrhoidectomy (ST Mark's ligation/excision method) In: LP Fielding, *Operative Surgery. Surgery of the colon, Rectum & Anus. Fifth Edition. Butterworth Heinemann Ltd*. 1993; 789-796.
4. Kanellos I, Zacharakis E, Christoforidis E, Angelopoulos S, Kanellos D, Pramateftakis MG, Betsis D. Usefulness of lateral internal sphincterotomy in reducing postoperative pain after open hemorrhoidectomy. *World J. Surg*. 2005; 29(4): 464-468.
5. Khubchandani IT. Internal sphincterotomy with hemorrhoidectomy does not relieve pain: a prospective randomized study. *Dis. Colon Rectum*. 2002; 45: 1452-1457.
6. Wasvary HJ, Hain J, Mosed-Vogel M. et al. Randomized, prospective, double-blind, placebo –controlled trial of effects of nitroglycerine ointment on pain after hemorrhoidectomy. *Dis. Colon Rectum*. 2001; 44: 1069-1073.
7. DiBella F, Esteinne G. Indications for internal medioposterior with anoplasty of lateral sphincterectomy during hemorrhoidectomy. Our experience. *Minerva-Chir*. 1990; 45(6): 361-363.
8. Mortensen PE, Olsen J, Pedersen IK, Christiansen J. A randomized study on hemorrhoidectomy combined with anal canal dilatation. *Dis. Colon Rectum*. 1987; 19: 755-757.

9. Eisenhammer S. Internal anal sphincterotomy plus free dilatation versus anal stretch with special criticism of the anal stretch procedure for hemorrhoids: the recommended modern approach to hemorrhoid treatment. *Dis. Colon Rectum*. 1974; 17: 493-522.
10. Asfar SK, Juma TH, Ala-Edeen T. Hemorrhoidectomy and sphincterotomy. A prospective study comparing the effectiveness of anal stretch and sphincterotomy in reducing pain after hemorrhoidectomy. *Dis. Colon Rectum*. 1988; 31: 181-185.
11. Safwan A Taha. A new modification for closure of haemorrhoidectomy wounds. *Basrah J Surg*. 2001; 7: 20-24.
12. Schouten WR, van Vroonhoven TJ. Later internal sphincterotomy in the treatment of hemorrhoids. *Dis. Colon Rectum*. 1986; 29: 869-872.
13. Favetta U, Amato A, Interisano A, Pescatori M. Clinical, manometric, and sonographic assessment of the anal canal sphincters: a comparative prospective study. *Int J Colorectal Dis*. 1996; 11: 163-166.
14. Mathai V, Ong BC, Ho YH. Randomised controlled trial of lateral internal sphincterotomy with haemorrhoidectomy. *Br J Surg*. 1996; 83: 380-382.
15. Lord PH. Digital dilatation for hemorrhoids treatment. *Int Surg*. 1989; 74: 144-145.
16. Notaras MJ. The treatment of anal fissure by lateral subcutaneous internal sphincterotomy—a technique and results. *Br J Surg*. 1971; 58: 96-100.
17. Whitehead J. Sample size calculations for ordered categorical data. *Stat. Med*. 1993; 12: 2257-2272.
18. Leong AF, Husain MJ, Seow-Choen F, Goh Hs. Performing internal sphincterotomy with other anorectal procedures. *Dis. Colon Rectum*. 1994; 37: 1130-1132.
19. Hananel N, Gordon PH. Lateral internal sphincterotomy for fissure-in-ano revisited. *Dis. Colon Rectum*. 1997; 40: 597-602.

Table 1(A): Post operative pain score in all patients

Severity of pain	Score per patient	Gr.II (Study group) Hemorrhoidectomy with IS		Gr.I (Control group) Hemorrhoidectomy alone	
		No. Of Patients	Pain score	No. Of patients	Pain score
Grade 1	1	13	13x1=13	2	2x1=2
Grade 2	2	9	9x2=18	13	13x2=26
Grade 3	3	3	3x3=9	10	10x3=30
All grades			40	25	58
Mean			1.60		2.32

IS= Internal Sphincterotomy.

Post operative pain for Gr2 in comparison to Gr1, $X^2=20.846$, 2df, $P<0.01$

Table 1(B): Showing the severity of post operative pain after hemorrhoidectomy with and without internal sphincterotomy; in two age groups.

Age group in years	Study Group(hemorrhoidectomy with sphincterotomy)		Control group(hemorrhoidectomy without sphincterotomy)	
	No. of patients	Mean pain score	No. of patients	Mean pain score
Under 40 years	17	1.82	14	2.84
40-50 years	8	1.38	11	1.80
All ages	25	1.60	25	2.32

Table 2: Post operative complications in all patients

Group	EARLY					LATE				
	Retention of urine	Post op haemorrhage	Pain in the 1 st bowel motion			Faecal soiling		Incontinence		Anal stenosis
			Mild	Moderate	Severe	No. Of Pts	Duration	Flatus	Faeces	
Study group (GrI)	8	Nil	4	12	9	Nil	-	Nil	Nil	1
Control group ((Gr-II)	1	Nil	22	2	1	1	2 weeks	2	Nil	Nil

1. For retention of urine $X^2= 6.638$, 1 df, $P<0.01$
2. For pain during 1st bowel motion $X^2=25.98$, 1df, $P<0.01$

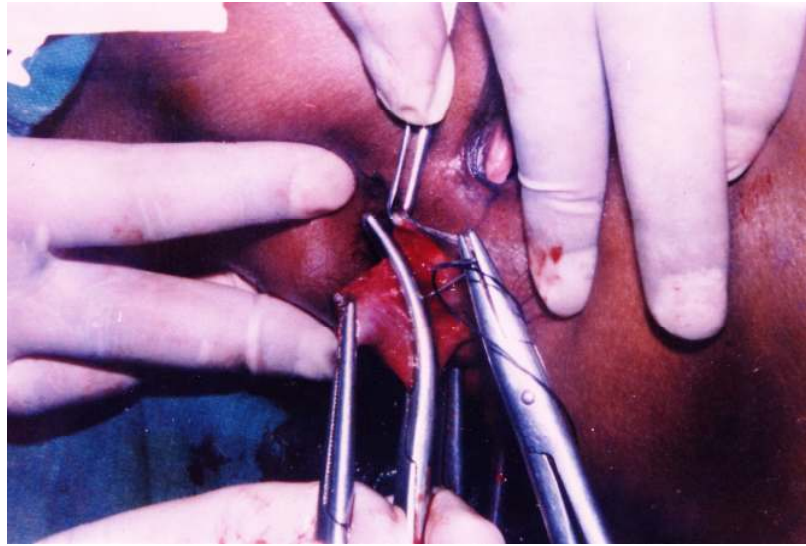


Figure 1: Classical open hemorrhoidectomy (Milligan and Morgan)

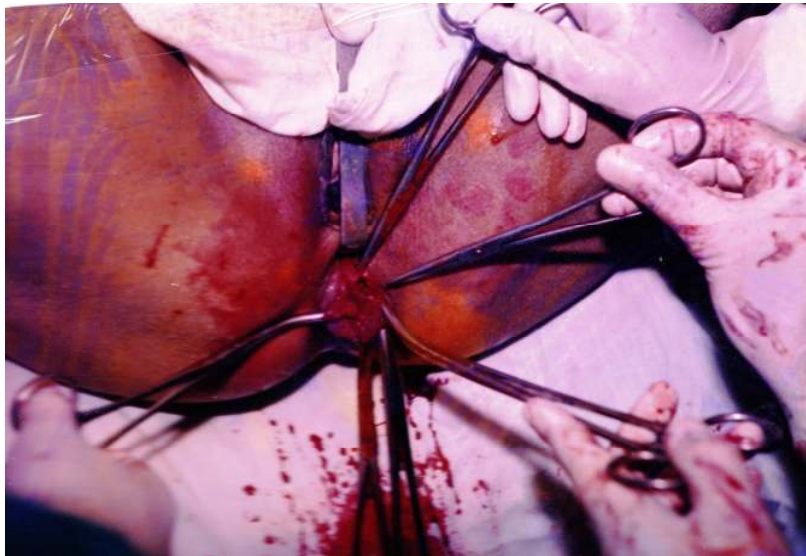


Figure 2: Internal anal Sphincterotomy through open hemorrhoidectomy wound.